

Produced under an educational grant from Edwards Lifesciences LLC

Image-Guided Thrombectomy in Vascular Surgery

The over-the-wire Fogarty Thru-Lumen embolectomy catheter offers expanded capabilities that can be applied to traditional techniques.

BY DAVID H. DEATON, MD

The Fogarty Arterial Embolectomy Catheter (Edwards Lifesciences LLC, Irvine, CA) introduced to vascular surgery the concept and capability of remote treatment of arterial pathology. It has become the standard for removal of peripheral emboli and thrombi since its introduction in 1963, and it has generated a variety of imitations. The parallel development of the Seldinger technique and a host of other over-the-wire-based catheter technologies led to the latest guidewire-compatible iteration of the Fogarty balloon catheter—the Fogarty Thru-Lumen Embolectomy Catheter. The Thru-Lumen Embolectomy Catheter incorporates the same compliant, concentric balloon technology and catheter as the standard Fogarty Catheter, but adds an additional lumen that can be used to guide the catheter over a wire, or for fluid delivery.

The Fogarty Thru-Lumen Embolectomy Catheter is manufactured in sizes of 3 F to 7 F, which allows the device to accommodate a variety of standard guidewire diameters (.018-, .025-, .035-, and .038-inch). The catheter is available in two lengths—40 cm and 80 cm. Stainless steel bushings located at the proximal and distal ends of the balloon enable accurate visualization under fluoroscopy.

This article discusses the expanded capabilities of the Fogarty Thru-Lumen Embolectomy Catheter for its traditional techniques, as well as other methods not traditionally used with this type of catheter.

IMAGE-GUIDED EMBOLECTOMY AND THROMBECTOMY

Embolectomy and thrombectomy procedures were revolutionized by the introduction of the Fogarty catheter. This innovation made it possible to extract emboli and thrombi from remote locations through proximal or dis-

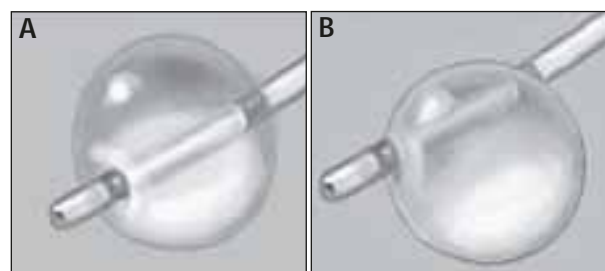


Figure 1. Concentric balloon inflation (A). Eccentric balloon inflation (B).

tal open arterial access. Primary endpoints of success or failure of the original techniques were (1) the ability to pass the catheter down the arterial segment, (2) extraction of thrombus, and (3) the restoration or enhancement of backbleeding at the arteriotomy. The technique was “blind” in the sense that one had no ability to visualize the extent and location of thrombus. Although results were vastly superior to the historical controls at that time, there were still significant failures, as well as iatrogenic injuries from balloon inflation and the repetitive trauma of the balloon shear on the arterial wall. The regulation of balloon inflation is subjective, and proper inflation and deflation during withdrawal is a skill acquired over the course of many years using the technique.

The addition of fluoroscopy to many operating room environments, and the addition of the guidewire lumen in the Fogarty Thru-Lumen Embolectomy catheter, make possible a far more controlled, reproducible, and accessible technique for thrombectomy and embolectomy.

ARTERIAL ACCESS

An appropriate site for access is chosen based on suspected location of the thrombus and ease of access and

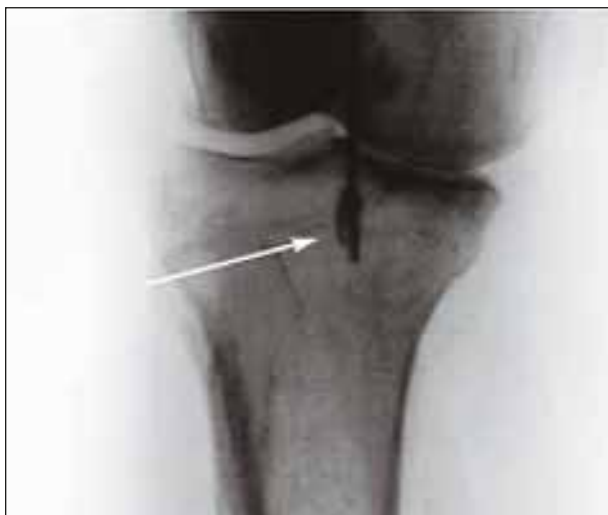

Figure 2. The inflated Fogarty Thru-Lumen Embolectomy Catheter.

wound healing. Lower-extremity embolus can involve the common femoral (CFA), profunda femoris (PFA), and superficial femoral arteries (SFA) separately, or in any combination thereof. If there is knowledge via prior ultrasound or arteriogram that the CFA and PFA are not involved, the SFA may be approached below the common femoral bifurcation through a small incision, avoiding the groin crease and lymph node basin. In the more typical case, the optimal approach exposes the bifurcation of the CFA. If ultrasound is available and the bifurcation can be localized, a small transverse incision can be placed just over that location to facilitate wound healing without impairing exposure. If the vessel is heavily diseased and local endarterectomy or patch angioplasty is a possibility, then strong consideration to a longitudinal arteriotomy is recommended. The CFA, SFA, and PFA are controlled separately with vessel loops. Each vessel is then sequentially released to check for iliac inflow from the CFA and backbleeding from the PFA and SFA.

BALLOON CATHETER SELECTION AND PREPARATION

The French size of the thrombectomy catheter is chosen based on the largest expected vessel diameter to be treated, which is often the external iliac artery (average 7-10-mm diameter), and therefore a 5-F or 6-F catheter is selected that can accommodate a .035-inch guidewire.

The central lumen of the catheter is flushed with heparinized saline. The solution used to fill the balloon should be saline, with enough contrast added to make visualization of balloon inflation easy (eg, usually a concentration of 30% to 50% iodinated contrast agent). The inflated balloon should be placed under the fluoroscope

to ensure that it can be imaged easily. The balloon is inflated with the contrast solution and deflated to remove as much air from the system as possible. The volume in the syringe is then adjusted to the rated maximum volume of the balloon catheter.

It is important to check the balloon for concentricity before use. Eccentric inflation can result in uneven vessel pressure and/or incomplete clot removal (Figure 1). Be sure not to exceed the recommended maximum inflation volume.

GUIDEWIRE SELECTION

A straight, soft guidewire (eg, Bentson, Cook Incorporated, Bloomington, IN) is generally used to traverse the occluded segment(s). Wires with or without hydrophilic coatings may be used, but a noncoated guidewire is most often used initially. The guidewire is inserted into the balloon catheter so that its tip is just inside the catheter. Typically, 90% of stenotic lesions can be crossed with a wire.

FOGARTY THRU-LUMEN EMBOLECTOMY CATHETER PASSAGE

The catheter tip is gently inserted into the orifice of the SFA, and the vessel loop is re-tightened just enough to prevent bleeding. The fluoroscope is brought into position and, under fluoroscopic guidance, the guidewire is advanced down the SFA and into the distal popliteal artery. The balloon is gently inflated just below the knee joint until it starts to take a rectangular shape as opposed to an ovoid shape (Figure 2).

This indicates profile of the balloon to the vessel wall, and excess inflation will only traumatize the vessel. The guidewire is removed. Using subtraction angiography, an arteriogram of the popliteal and proximal tibial vessels is obtained. If there is no evidence of acute tibial occlusion (eg, abrupt occlusion of undiseased vessel), the rest of the thrombectomy procedure will then be directed only at the popliteal and SFA. If there does appear to be thrombus in one or more of the tibials, a variety of options exists for treating the tibial thrombus.

THROMBECTOMY

If there is tibial involvement, smaller guidewires and balloons may be chosen to facilitate the selective cannulation of these vessels (eg, 3-F, .018-inch guidewire compatible) (Figure 3). A balloon may be inflated just proximal to an occlusion, and local thrombolytic therapy administered to avoid balloon trauma to the vessel wall.

If a guidewire passes easily through the occlusion, it is likely to be fresh thrombus. In this case, a small bal-

loon can be advanced over the wire and the balloon very gently inflated under a magnified fluoroscopic image. With the first hint of balloon profile, the balloon should then be withdrawn into the popliteal artery.

It is helpful to restrict all inflow from above so that the thrombus will not simply be pushed back into the tibial circulation. The small balloon can be inflated to a larger size once in the popliteal artery, and if it can achieve profile in the popliteal artery and the SFA, it is withdrawn under fluoroscopic guidance to the proximal arteriotomy. This will also avoid loss of the thrombus back into the tibial circulation.

If there is no tibial involvement, the balloon catheter that was used to shoot the original arteriogram is reinflated to achieve profile in the distal popliteal artery and is slowly withdrawn with constant observation by fluoroscopy. If the balloon “hangs” on a stenotic or diseased area, traction is relaxed to a very light force and the balloon is gently deflated until it passes through the stenotic area (Figure 4).

Once through, the balloon is reinflated to maintain profile in the nonstenotic area. The diseased/stenotic area can be marked for possible later angioplasty or stent therapy. The importance of reducing traction while coming through stenotic areas cannot be overemphasized. If there is a large amount of traction on the balloon catheter coming through the stenosis, it will recoil as it clears the tight area, and the thrombus can be lost below the balloon again. If thrombus does migrate below the balloon, it can frequently be visualized in the column of contrast agent that is often pulled behind the balloon catheter as it is withdrawn. If this is seen, it is important to repeat the balloon pass before restoring flow.

If the first pass of the balloon from the distal popliteal to the proximal arteriotomy is productive of thrombus/embolus and there is no suspicion that the apposition of the balloon to the vessel was lost on the way up, a completion angiogram can be performed after this single passage. Replace the balloon catheter in the proximal popliteal artery and perform an arteriogram across the knee joint and into the tibials. If this is acceptable, the catheter can be withdrawn to the

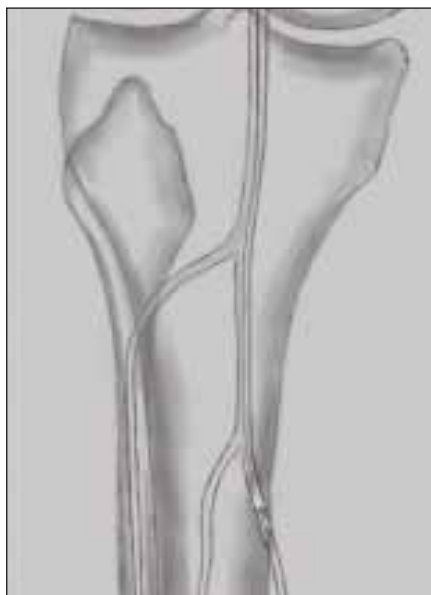


Figure 3. The Fogarty Thru-Lumen Embolectomy Catheter advanced over a guidewire.

proximal SFA and a completion arteriogram of the SFA can be completed.

POTENTIAL ADVANTAGES

Some advantages of image-guided, over-the-wire thrombectomy are:

- A larger catheter and balloon can be safely used when inflation is guided by visualization, avoiding the use of multiple catheters and balloons.
- Variable inflation avoids endovascular trauma and dissection.
- Balloon deformation is a “local arteriogram,” pinpointing diseased areas for detailed imaging or direct treatment.
- Wire passage prior to catheter deployment is a strong indicator of embolic or thrombotic

etiology. The ability to pass a wire is strong predictor of outcome. A variety of techniques can be employed to traverse lesions inaccessible to a catheter alone.

• Distal positioning of the balloon is made possible by wire and image guidance. This prevents multiple passes with an inflated balloon and increases the likelihood of complete treatment with a single balloon pass.

• The infusion of local contrast or therapeutic agents is accomplished by gently inflating the balloon and delivering the agent through the wire lumen. This allows for lower volume but more concentrated contrast or therapeutic agent (eg, thrombolytic agents, nitroglycerin, etc.).

• The access site can be chosen with more freedom because the proximity to branch points is not as crucial to catheter passage using selective over-the-wire catheterization techniques. For example, there is no need to expose the distal popliteal to approach tibial vessels.

INTRALUMINAL VASCULAR CONTROL AND SITE-SPECIFIC ANGIOGRAPHY

The Fogarty Thru-Lumen Embolectomy Catheter can also be used as an endoluminal clamp, which is particularly useful when approaching difficult lesions. Distal control or other convenient arterial access can be obtained first, and a Fogarty Thru-Lumen Embolectomy Catheter can be positioned at the desired site of proximal control. A predetermined amount of balloon

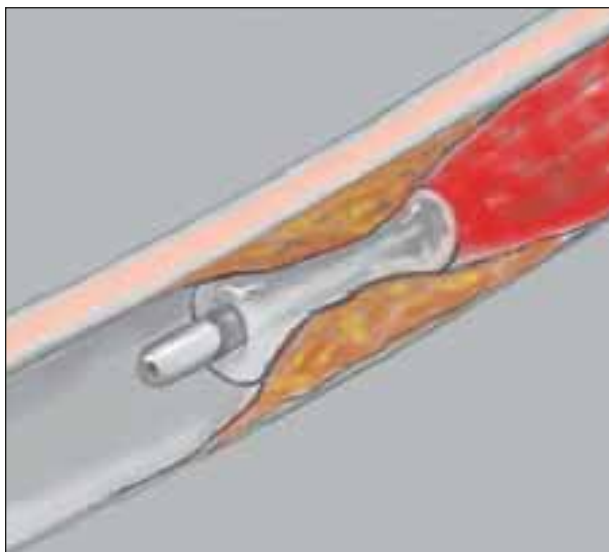


Figure 4. Balloon deformed by stenosis while removing thrombus.

inflation can be determined under fluoroscopy, and the syringe is limited to that volume. When occlusion is required, the balloon is simply inflated and the gate valve is applied to fix the inflation at that level. A wire can be left in place in cases in which risk of dislodgment is significant, allowing quick repositioning of the balloon in that event. This technique is particularly useful when approaching reoperative femoral lesions, infected or degenerative lesions, or any other lesion that would require difficult proximal or distal control. Calcified arteries or those that are difficult or dangerous to clamp for any reason are also good candidates for intraluminal control. The catheter can simultaneously be used to infuse heparinized saline when used for control, avoiding the necessity of systemic heparinization in some cases.

Another potential use for the Fogarty Thru-Lumen Embolectomy Catheter is for site-specific arteriography. In this use, the balloon is inflated near the area of interest. A lesser volume of contrast can then be used to obtain a better arteriogram than using a bolus of contrast from a more distant location. Examples of this would include tibiopopliteal angiograms with the balloon inflated proximally, or inflow visualization of an axillofemoral graft with the balloon inflated just distal to the anastomosis. ■

David H. Deaton, MD, is Chief of Endovascular Surgery at Georgetown University Hospital in Washington, DC. He has disclosed that he is a paid consultant to Edwards Lifesciences. Dr. Deaton may be reached at (202) 687-1265; dhdvasc@aol.com.

Subscribe to *Endovascular Today's e-News*

Our biweekly electronic newsletter can be delivered directly to your e-mail account, bringing you industry and clinical news updates between our print issues. Subscribing is easy and free. Simply e-mail us at EVTeNews@bmctoday.com, type "Subscribe e-News" in the subject line, and include your name in the body of the e-mail. You can unsubscribe at any time by clicking on the "unsubscribe" link in the e-Newsletter.

We look forward to hearing from you!

