

# Update on Currently Available Bioactive Coils

Polyglycolic acid and hydrogel coatings are being investigated to find the optimal combination of bioactive and platinum coils for intracranial aneurysm treatment.

BY ROBERT D. ECKER, MD, AND LEE R. GUTERMAN, MD, PhD

The introduction of Guglielmi Detachable Coils (GDC; Boston Scientific/Target, Fremont, CA) in the early 1990s revolutionized the treatment of intracranial aneurysms. With a guide sheath, a microcatheter, and soft platinum coils, an aneurysm could be elegantly excluded from the circulation without the need for a craniotomy. As experience grew during the last 2 decades, it became clear that wide-necked and giant aneurysms recurred when treated with bare platinum coils alone. On the basis of size, neck, and location, 4% to 50% of aneurysms will recur after treatment.<sup>1</sup> Approximately 23% of aneurysms recur after coiling, with a re-treatment rate of 15% in the first 2 years and a 1.1% rate of re-rupture.<sup>2-4</sup>

Balloon- and stent-assisted coiling have added new techniques to the endovascular armamentarium, but there are still aneurysms that are recalcitrant to treatment.<sup>5-9</sup> With the introduction of the Matrix coil (Boston Scientific/Target) in 2002, bioactive coils were introduced with the joint goal of inducing an exuberant healing response and improved filling volume of a coiled aneurysm, although the Matrix coil was approved by the FDA based on equivalency with conventional GDC. Four bioactive coils are now available for clinical use: Matrix, HydroCoil (MicroVention, Aliso Viejo, CA), Cerecyte (Micrus, Sunnyvale, CA), and Nexus (Micro Therapeutics, Inc., Irvine, CA) (Table 1).




Figure 1. The Matrix coil. Guglielmi detachable coil matrix enriched with polyglycolic acid (PGLA) (A). PGLA intertwined in the platinum coil (B).

## GENERAL CHARACTERISTICS OF CURRENTLY AVAILABLE BIOACTIVE COILS

Only two different bioactive agents are used in the current generation of bioactive coils. PGLA is the bioabsorbable polymer used in the construction of three of the currently commercially available coils. An expanding hydrogel is incorporated in the HydroCoil. Coils coated with several other materials have been tested in animal models, including transforming growth factor-beta, vascular endothelial growth factor, type I collagen, fibronectin, vitronectin, lamin, fibrinogen, ion implantation, and P-32.<sup>10-14</sup> All of these coil techniques have shown promise in animals, but none are currently available for clinical or commercial use.

Although the Matrix, Cerecyte, and now the bioactive Micro Therapeutics, Inc. coil (Nexus) all have differences in the way in which the PGLA is incorporated into the platinum coil, the theory behind the effectiveness of the coils is similar (Figure 1). With PGLA exposure to the internal aneurysm environment, the hope is that an intense inflammatory response in the setting of thrombus will promote more exuberant healing/scarring than bare platinum and thus, lower the rate of aneurysm recanalization. The PGLA absorbs within 90 days from implantation, leaving no long-term inflammatory promoter in the body. The effectiveness of the Matrix coil has been demonstrated in animals.<sup>15</sup>

The HydroCoil consists of an expandable hydrogel coupled to a platinum coil, and can undergo a three- to ninefold increase in size. Expansion of the hydrogel occurs when placed in blood. The user has 5 to 7 minutes to place the coil before retrieving it through the

TABLE 1. CURRENTLY AVAILABLE BIOACTIVE COILS

Coil Name	Bioactive Component	Company
Matrix	PGLA	Boston Scientific/Target
HydroCoil	Hydrogel	MicroVention
Cerecyte	PGLA	Micrus
Nexus	PGLA	Micro Therapeutics, Inc.

microcatheter becomes difficult due to swelling of the hydrogel coating. The hydrogel is not as easily degraded as thrombus and is not subject to normal thrombolytic processes. Therefore, a more extensive healing process can take place, again, leading to lower recanalization rates. HydroCoil treatment has proven effective in animals (Figure 2).<sup>16</sup>

## OVERVIEW OF CLINICAL DATA ON BIOACTIVE COILS

Of the currently commercially available bioactive coils, meaningful clinical data are documented for only the Matrix and HydroCoil. The literature on these two bioactive coils focuses on the volume of coils placed in an aneurysm, and the rate of recurrence compared with bare platinum coils. Sluzewski et al have recently reported that aneurysms that are filled beyond 24% of their volume and that are <60 mL do not recur at 6 months.<sup>17</sup> Previous investigations with platinum coils have shown that maximum coil density is 34%.<sup>18</sup> In the original publication on HydroCoils, Cloft and Kallmes report that HydroCoils provided statistically superior volumetric packing, compared with standard platinum coils (73% vs 32%;  $P=.001$ ).<sup>19,20</sup> According to data provided by MicroVention in their package insert, full expansion of the coils results in an increase in their diameter by 69% to 107%. In a recent publication, Deshaies et al have combined these volumetric insights and found that filling volumes between 23% and 80% can be achieved with HydroCoils.<sup>21</sup> In this series of 12 patients, only a giant aneurysm that was packed 23% volumetrically recurred at 6-month follow-up. Arthur et al have recently described a radiolucent region between the coil mass in aneurysms treated with HydroCoil and the parent vessel.<sup>22</sup> The investigators postulate that this is the angiographic equivalent of exuberant scar healing at the neck (Figures 3 and 4).

The HydroCoil for Endovascular Aneurysm Occlusion (HEAL) study registry of 200 aneurysms treated with the HydroCoil has recently reported some interim data at the 14-month follow-up evaluation.<sup>23</sup> The major findings were that the HydroCoil was as safe as a platinum


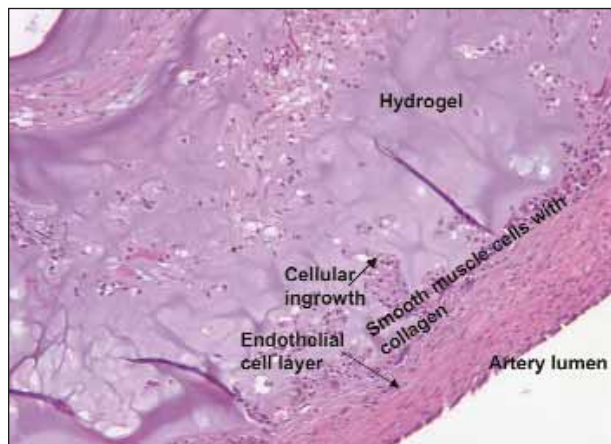


Figure 2. HydroCoil before and after hydration.



**Figure 3.** Exuberant healing with cellular ingrowth 1 month after HydroCoil treatment of an experimental aneurysm in a rabbit. (Adapted and reprinted with permission from Kallmes DF, Fujiwara NH. New expandable hydrogel-platinum coil hybrid device for aneurysm embolization. *Am J Neuroradiol.* 2002;23:1580-1588.)

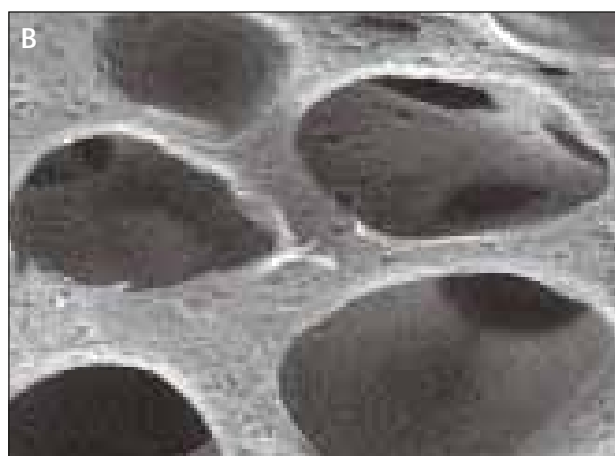

coil and that there seemed to be a trend toward less re-treatment with the HydroCoil if it was the last coil placed and >50% of the overall coil length was used. However, the numbers of patients treated are small, and the optimal combination of platinum and HydroCoil is being investigated in the HEAL II registry. More importantly, the HydroCoil Endovascular Occlusion and Packing Study (HELPS) is enrolling at least 500 patients in a prospective, randomized, multicenter, international trial of the HydroCoil versus bare platinum coil to evaluate major recurrence rates at 15 to 18 months, packing density/volume compared with platinum coils with

respect to rebleeding and re-treatment, and clinical outcome at 3 to 6 months and 15 to 18 months. The results of this more structural and scientifically designed study are anxiously awaited.

Mirroring the findings reported by Arthur et al, Gonzalez et al have reported a radiolucent region between the neck of two aneurysms packed with Matrix coils and the parent vessel thought to represent evidence of excellent neck healing.<sup>24</sup> Although there are animal data demonstrating that Matrix coils lead to more exuberant healing than bare platinum coils, there is little outside of published abstracts to support this claim in patients.<sup>25</sup> Interestingly, lower packing densities for aneurysms treated with Matrix coils have been observed in animal studies and some larger clinical series.<sup>25</sup> Although this has been suggested not to be a problem and perhaps allows increased contact of the blood and aneurysm dome with PGLA, recanalization is a potential problem.<sup>15</sup> Fiorella et al recently presented a prospective consecutive series of 123 patients with 125 aneurysms treated with Matrix coils.<sup>26</sup> In this series, 32% of patients had recanalization and 19% required re-treatment. Forty-six (68%) were unchanged or demonstrated progressive thrombosis. The investigators postulate that there is a group of Matrix “responders” and another group of “nonresponders.” In one group, the exuberant scarring seen in animals occurs and, in the other, limited inflammatory change is apparent.

## HYDROCEPHALUS AND MENINGITIS

Meyers et al have recently reported two cases in which patients with large aneurysms treated with both Matrix and HydroCoils developed significant aseptic



**Figure 4.** Hydrogel characteristics. Hydrated state (A). Blood components (including proteins) are absorbed into hydrogel during a swelling process that promotes healing (original magnification X150, 25 kV, 200  $\mu$ m). Dehydrated state (B). Porous hydrogel provides an excellent substrate for healing (neointima formation, smooth muscle cell migration) (original magnification X500, 20 kV, 100  $\mu$ m).

meningitis responsive to steroids.<sup>27</sup> Brisman et al, in a series of patients who underwent stent-assisted HydroCoil treatment, report two cases of communicating hydrocephalus requiring shunting in two patients with unruptured aneurysms.<sup>28</sup> Although these cases are worrisome, there are not enough cases in the literature to date to truly suggest a higher rate of infection or severe aseptic meningitis. In fact, in 2003, Friedman et al reported a 70-year-old woman who had undergone stent-assisted platinum coil treatment of a basilar trunk aneurysm and subsequently developed a symptomatic, large pontine cyst.<sup>29</sup> The cyst was believed to have developed in response to the large coil mass in the aneurysm and was managed with fenestration and shunting.

## CONCLUSIONS

Bioactive coils are in their infancy. New biologically active products will eventually be incorporated into coils to promote a more exuberant scarring and retraction of the aneurysm and repair of the vessel wall. The currently available coils with PGLA and hydrogel coatings are being further investigated to find the optimal combination of bioactive and platinum coils. Ongoing studies such as HELPS will help define the true benefit and indication for bioactive coils. ■

*Robert D. Ecker, MD, is Clinical Assistant Instructor of Neurosurgery, School of Medicine and Biomedical Sciences, University at Buffalo, State University of New York, Buffalo, New York. He has disclosed that he holds no financial interest in any product or manufacturer mentioned herein.*

*Lee R. Guterman, MD, PhD, is Associate Professor of Neurosurgery and Radiology, Director of Endovascular Fellowship, and Co-director of the Toshiba Stroke Research Center, School of Medicine & Biomedical Sciences, University at Buffalo, State University of New York, Buffalo, New York. He has disclosed that he is a medical advisor to Micro Therapeutics, Inc. Dr. Guterman may be reached at (716) 887-4960.*

1. Raabe A, Schmiedek P, Seifert V, et al. German Society of Neurosurgery Section on Vascular Neurosurgery: Position Statement on the International Subarachnoid Hemorrhage Trial (ISAT). *Zentralbl Neurochir*. 2003;64:99-103.
2. Murayama Y, Nien YL, Duckwiler G, et al. Guglielmi detachable coil embolization of cerebral aneurysms: 11 years' experience. *J Neurosurg*. 2003;98:959-966.
3. Ng P, Khangure MS, Phatouros CC, et al. Endovascular treatment of intracranial aneurysms with Guglielmi detachable coils: analysis of midterm angiographic and clinical outcomes. *Stroke*. 2002;33:210-217.
4. Raymond J, Guilbert F, Weill A, et al. Long-term angiographic recurrences after selective endovascular treatment of aneurysms with detachable coils. *Stroke*. 2003;34:1398-1403.
5. Fiorella D, Albuquerque FC, Han P, et al. Preliminary experience using the Neuroform stent for the treatment of cerebral aneurysms. *Neurosurgery*. 2004;54:6-17.

6. Howington JU, Hanel RA, Harrigan MR, et al. The Neuroform stent, the first microcatheter-delivered stent for use in the intracranial circulation. *Neurosurgery*. 2004;54:2-5.
7. Malek AM, Halbach VV, Phatouros CC, et al. Balloon-assist technique for endovascular coil embolization of geometrically difficult intracranial aneurysms. *Neurosurgery*. 2000;46:1397-1407.
8. Moret J, Pierot L, Boulin A, et al. "Remodeling" of the arterial wall of the parent vessel in the endovascular treatment of intracranial aneurysms (abstract S83). *Proceedings of the 20th Congress of the European Society of Neuroradiology*. *Neuroradiology*. 1994;36 (Suppl 1):S83.
9. Moret J, Cognard C, Weill A, et al. Reconstruction technique in the treatment of wide-neck intracranial aneurysms: long-term angiographic and clinical results. *Apropos of 56 cases*. *J Neuroradiol*. 1997;24:30-44.
10. de Gast AN, Altes TA, Marx WF, et al. Transforming growth factor beta-coated platinum coils for endovascular treatment of aneurysms: an animal study. *Neurosurgery*. 2001;49:690-696.
11. Kallmes DF, Fujiwara NH, Yuen D, et al. A collagen-based coil for embolization of saccular aneurysms in a New Zealand White rabbit model. *Am J Neurorad*. 2003;24:591-596.
12. Murayama Y, Vinuela F, Suzuki Y, et al. Ion implantation and protein coating of detachable coils for endovascular treatment of cerebral aneurysms: concepts and preliminary results in swine models. *Neurosurgery*. 1997;40:1233-1244.
13. Raymond J, Leblanc P, Lambert A, et al. Feasibility of radioactive embolization of intracranial aneurysms using 32P-implanted coils. *Stroke*. 2003;34:1035-1037.
14. Raymond J, Leblanc P, Morel F, et al. Beta radiation and inhibition of recanalization after coil embolization of canine arteries and experimental aneurysms: how should radiation be delivered? *Stroke*. 2003;34:1262-1268.
15. Murayama Y, Tateshima S, Gonzalez NR, et al. Matrix and bioabsorbable polymeric coils accelerate healing of intracranial aneurysms: long-term experimental study. *Stroke*. 2003;34:2031-2037.
16. Kallmes DF, Fujiwara NH. New expandable hydrogel-platinum coil hybrid device for aneurysm embolization. *Am J Neurorad*. 2002;23:1580-1588.
17. Sluzewski M, van Rooij WJ, Slob MJ, et al. Relation between aneurysm volume, packing, and compaction in 145 cerebral aneurysms treated with coils. *Radiology*. 2004;231:653-658.
18. Piotin M, Mandai S, Murphy KJ, et al. Dense packing of cerebral aneurysms: an in vitro study with detachable platinum coils. *Am J Neurorad*. 2000;21:757-760.
19. Cloft HJ, Kallmes DF. Aneurysm packing with HydroCoil Embolic System versus platinum coils: initial clinical experience. *Am J Neurorad*. 2004;25:60-62.
20. Kallmes DF, Cloft HJ. The use of hydrocoil for parent artery occlusion. *Am J Neurorad*. 2004;25:1409-1410.
21. Deshaies EM, Bagla S, Agner C, et al. Determination of filling volumes in HydroCoil-treated aneurysms by using three-dimensional computerized tomography angiography. *Neurosurg Focus*. 2005;18:E5.
22. Arthur AS, Wilson SA, Dixit S, et al. Hydrogel-coated coils for the treatment of cerebral aneurysms: preliminary results. *Neurosurg Focus*. 2005;18:E1.
23. Clinical Update Bulletin. Microvention Update. 2005;1.
24. Gonzalez NR, Patel AB, Murayama Y, et al. Angiographic evidence of aneurysm neck healing following endovascular treatment with bioactive coils. *Am J Neurorad*. 2005;26:912-914.
25. Costa V, Brophy J. for the Technology Assessment Unit (TAU) of the McGill University Health Centre (MUSC). The use of Matrix coils in the treatment of cerebro-vascular aneurysms. Available at [www.mcgill.ca/tau/](http://www.mcgill.ca/tau/) (accessed June 24, 2005).
26. Fiorella D, Albuquerque FC, McDougall CG. Aneurysm embolization with Matrix detachable coils: assessment of durability at 6-month follow-up. Presented at the 3rd Annual American Society of Interventional and Therapeutic Neuroradiology (ASITN) Practicum, Toronto, Ontario, May 21-22, 2005.
27. Meyers PM, Lavine SD, Fitzsimmons BF, et al. Chemical meningitis after cerebral aneurysm treatment using two second-generation aneurysm coils: report of two cases. *Neurosurgery*. 2004;55:1222.
28. Brisman JL, Song JK, Niimi Y, et al. Treatment options for wide-necked intracranial aneurysms using a self-expandable hydrophilic coil and a self-expandable stent combination. *Am J Neurorad*. 2005;26:1237-1240.
29. Friedman JA, McIver JI, Collignon FP, et al. Development of a pontine cyst after endovascular coil occlusion of a basilar artery trunk aneurysm: case report. *Neurosurgery*. 2003;52:694-699.