

Biomechanical Forces in the Femoropopliteal Arterial Segment

What happens during extremity movement and what is the effect on stenting?

BY H. BOB SMOUSE, MD; ALEXANDER NIKANOROV, MD, PhD; AND DANIELLE LaFLASH

Physicians have recently reported stent fractures in self-expanding nitinol stents placed into the superficial femoral (SFA) and popliteal arteries. Presentations at national meetings, including the Transcatheter Cardiovascular Therapeutics (TCT) meeting in Washington, DC,¹ and the International Symposium on Endovascular Therapy (ISET) meeting in Miami, Florida,² have reported the presence of stent fractures in implanted patients and, in some cases, the development of intimal hyperplasia, aneurysms, and vascular occlusions. Interestingly, similar types of stents placed elsewhere in the body have not shown the same propensity for fracture and failure.

Clinical investigators are determining the significance of stent fractures, while stent manufacturers and the FDA are attempting to predict which design types of nitinol stents will fracture and in what setting. The importance of stent fracture in the drug-eluting stent trials is threefold: (1) stent fractures could disrupt a drug delivery system, (2) fractured stents may result in vessel injury, and (3) the mechanical stress found in this arterial segment may delay vessel healing and stent incorporation. One premise is that the SFA and popliteal arteries undergo unique and severe conformational changes that can literally pull apart a metal device (stent).

Given this environment, incorporating implanted stents

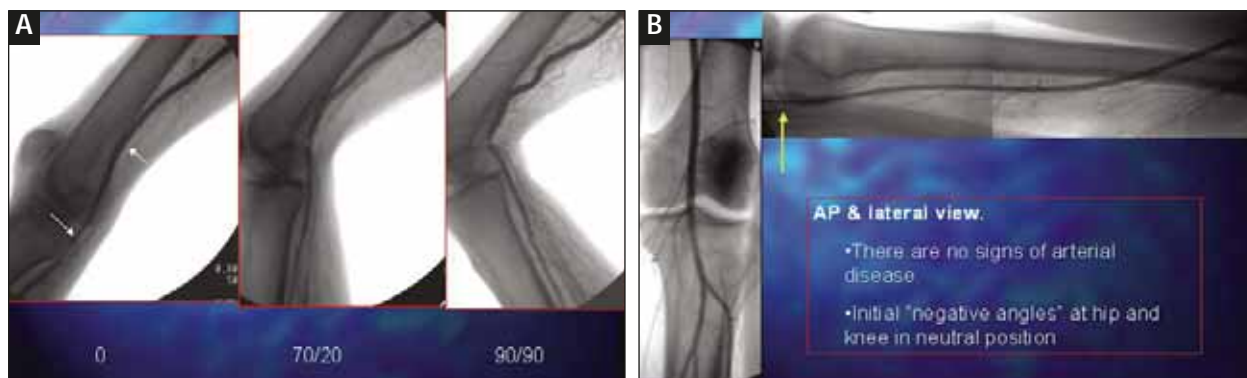


Figure 1. Arrows showing initial “negative angles” at the hip and knee in neutral position. As the hip flexes and the knee bends, these arterial segments will first straighten and then bend resulting in an arterial bend angle less than the respective joints (A). The arrows show the position of marker stents in the contrast-injected popliteal artery during joint movement (B).

■ Repeat all measurements and observations after the control stent was implanted.

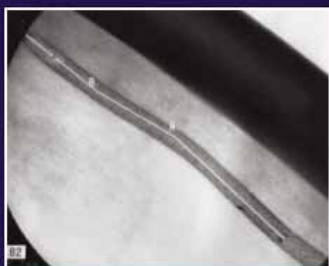


Figure 2. Length measurements were obtained along the central axis of the artery (white line).

into the SFA and popliteal arteries will likely take longer than similar stents implanted into more stable environments, such as the coronary circulation. Moreover, the unimpressive long-term results of the SIROCCO trials (Cordis Corporation, a Johnson & Johnson company, Miami, FL) should not dissuade us from exploring other drug-eluting stent systems. Successful treatment of the SFA may simply be a matter of prolonging the release of the drug beyond what is currently used in the coronary circulation, although this may be simplistic.

Because the morphologic changes occurring in the SFA and popliteal arteries during limb movement are not well understood, we evaluated these changes during walking, stair climbing, and sitting-to-standing movement, using a cadaver model.

MATERIALS AND METHODS

Seven human cadavers (14 limbs) were evaluated for this study. The cadaver limbs were imaged in the supine position on an angiographic table, with arteriography in the neutral or straight-leg positions followed by repeat

arteriography with the hips flexed and knees bent to simulate walking, sitting-to-standing movement, and stair climbing (Figure 1A,B).

For walking, the hips were flexed 20° and the knees were bent 70°. For stair climbing and sitting-to-standing motion, the hips and knees were flexed and bent 90° each. The changes occurring during extremity movement were recorded from the mid-SFA to the distal popliteal artery and included measurements of shortening or elongation in mm, curvature changes in mm of radius, and degrees of bending of the arterial segments and joints (summarized in Tables 1 and 2). Although torsion (or twisting) was not critically evaluated, it was not evident during the study. Arterial branch points and short balloon-expandable stents, inserted into the arteries, were used to assist with measuring length changes of the SFA and popliteal arteries. Vessel bending was recorded with the degree of bend and mm of radius, and was found to occur primarily, but not exclusively, behind the knee.

All measurements and extremity movements were performed first for bare vessels and then repeated after nitinol stents were inserted into the SFA and popliteal arteries (Figure 2). Two different, commercially available, nitinol stents were used for the cadaver study. One stent was relatively flexible and the other stent had four times the axial rigidity. Both stents had similar surface finishes and radial strengths. We were able to draw some conclusions regarding the morphologic changes in the femoral-popliteal segment and some effects this may have on stenting.

FINDINGS

Arterial Shortening and Bending

During hip flexion and knee bending, the SFA and popliteal arteries demonstrated axial compression and bending, with most of the bending occurring behind the knee. These changes were exaggerated as the hip and knee flexed and bent more. There was no elongation, tor-

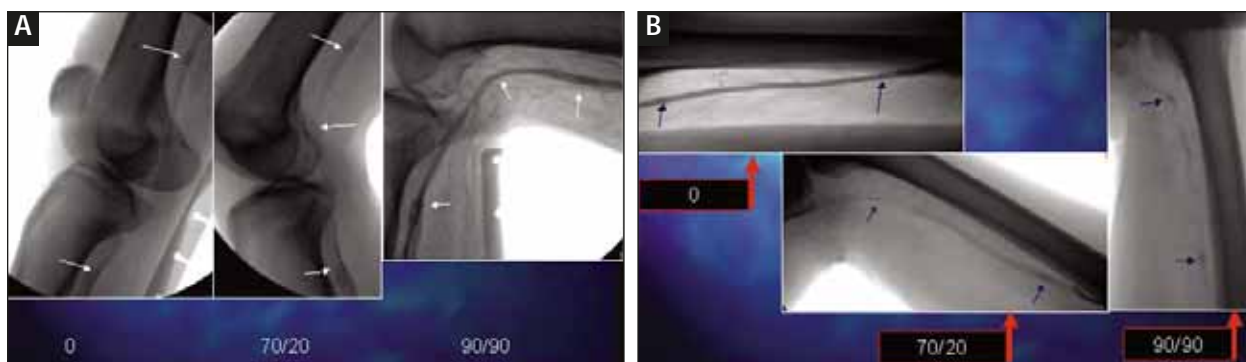


Figure 3. Proximal and distal arrows point to short balloon-expandable stents placed into the popliteal artery to assist with length measurements. The middle arrow shows bending of the popliteal artery with joint movement (A). Arrows mark the position of short balloon-expandable stents placed into the SFA. No significant bending was seen in the SFA with joint movement (B).

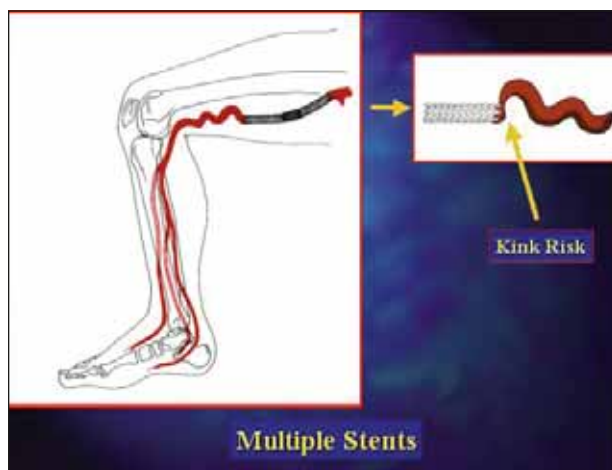


Figure 4. As stents are placed into the artery, its ability to bend and compress is reduced. The adjacent unstented artery bends more, possibly resulting in kinking at the margin of the stent.

sion, or twisting during lower-extremity movement. Although bending behind the knee seems intuitive, we did not observe significant bending in the straight segment of the SFA (Figure 3A,B).

The need for arterial shortening is explained in this manner: as the hip flexes and the knee bends, the straight-line distance between the hip and calf decreases. The positions of the femoral and popliteal arteries are medial and posterior to the femur and knee, respectively. Because of this course, the arterial segment will need to shorten in length as the distance between the calf and hip shortens to prevent kinking. This is what we observed and is accomplished by axial compression and bending (Tables 1 and 2).

Although the majority of bending is behind the knee, arterial bending will also occur in the straight segment of

the SFA. The inherent elastic and collagenous components found in the arterial wall allow a finite degree of axial compression during movement. Once the segment has axially compressed as much as possible, the straight portion of the artery, above the knee, will begin to bend or undulate allowing further foreshortening of the entire segment during ambulation.

Axial Rigidity

The bare artery has a certain inherent axial rigidity, or stiffness, that allows it to maintain its shape and contour while at rest. Although beneficial, this axial rigidity is also relatively minor, thus allowing the artery to compress and bend during ambulation without kinking. Although placing a stent into the artery has the desired effect of scaffolding the walls of the artery, thus preventing elastic recoil and treating intimal injuries, it adds the undesirable effect of altering the axial rigidity of the vessel. Depending on the stent type, the rigidity may be drastically increased, and this increase may severely reduce the arteries' ability to accommodate foreshortening. This lack of accommodation adds stress to the stent and the adjacent unstented artery, possibly contributing to stent kinking or fracturing (Figure 4).

Law of Conservation

The overall length of the arterial segment will shorten a predetermined amount during hip flexion and knee bending regardless of whether stents have been placed into the artery. Another way to think of this is that the musculoskeletal forces applied to the surrounding tissues are so great during joint movement that an artery with stents will be forced to shorten as much as an artery without stents. That is, vessel shortening is conserved regardless of intervention.

TABLE 1. BARE ARTERIES DURING HIP FLEXION AND KNEE BENDING

<ul style="list-style-type: none"> • No elongation • Torsion was not critically evaluated - not observed • Shortening and bending - major changes 				
	Mid- SFA	Distal SFA	Popliteal	Popliteal Bending Radius/Angle
70/20 (Shortening)	5%	14%	9%	
90/90 (Shortening)	10%	23%	14%	13 mm 63°
<i>Average values based on seven cadaver, 14 limb study</i>				

TABLE 2. STENTED POPLITEAL ARTERY "MORE FLEXIBLE" STENTS

	56 mm	100 mm	Bending Radius and Angle
70/20 (Shortening)	4%	11%	
90/90 (Shortening)	7%	14%	20 mm 69°

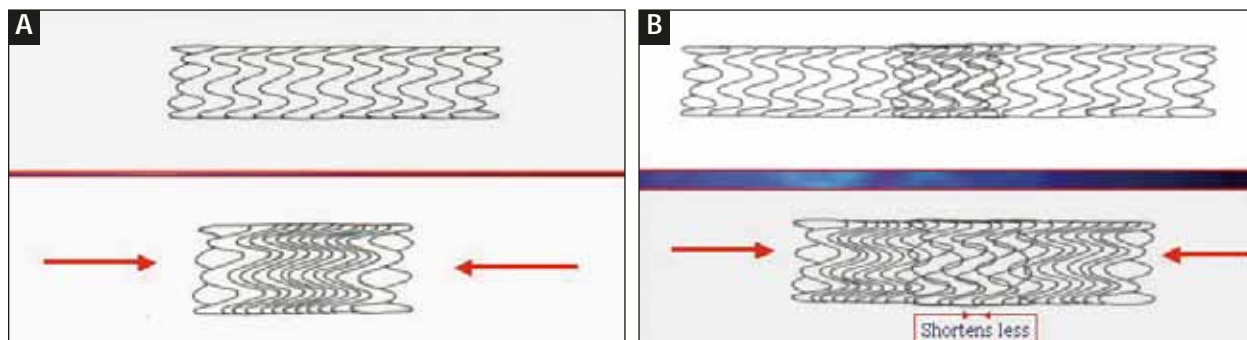


Figure 5. Single stent with axial loading compresses somewhat uniformly throughout its length (A). The overlapped portion of multiple stents compresses or shortens less than the nonoverlapped portions (B).

With longer and more rigid stents, the ability of the artery to axially compress is severely compromised. Once axial compression is maximized, the entire arterial segment will bend or undulate to accommodate the shorter distance between the hip and calf.

There appears to be an inverse relationship between axial compression and bending above the knee. If the artery is not axially rigid, it can compress and, therefore, bending is kept to a minimum. If the artery is rigid (eg, after placing one or more stents), it loses its ability to compress and tends to bend more. Depending on the rigidity of the stent and the overall length of stenting, bending above the knee may be minimal to severe. Moreover, the bare artery tends to bend in an exaggerated manner adjacent to a rigid stent. Bending of the stented artery could lead to strut fractures and stent kinking. Exaggerated bending of the bare artery at the margin of the stent could contribute to accelerated intimal hyperplasia or occlusion.

Compression Effect With Overlapping Stents

Because most of the arterial changes were due to axial compression and bending, the mechanical forces affected overlapping stents differently than single stents. The overlapped portions of the stents had twice the axial rigidity than the nonoverlapped portions of the stents, and therefore, shortened less.

Furthermore, because there is less shortening of the stented artery, the artery begins to bend. However, the overlapped portion of the stent is more rigid than the nonoverlapped portion, which results in a compression effect at the margins of the overlapped stent and adds stress to the stents. This may account for the higher rate of stent fractures seen in the SIROCCO series when more stents were overlapped (Figure 5A,B).

C- to 3-Shaped Changes With Popliteal Bending

Evaluation of the bare popliteal artery during knee

bending demonstrated that the artery bends in a smooth, C-shaped configuration. However, once the artery is stented, it is not able to shorten as much during knee bending. To accommodate bending and foreshortening, the stented artery begins to form several curves and changes from a C-shape into a 3-shape configuration. The additional areas of bending can certainly set up stress concentrations within and at the margins of the stents (Figure 6).

Catastrophic Stent Failure: Kinking

Furthermore, with maximum knee bending, there is the possibility of catastrophic stent failure. This is analogous to overbending a hollow tube, such as a straw, to the point of kinking. Just as a flexible straw can bend more readily than a rigid straw before failing, the same principle applies to axially flexible and axially rigid stents. We observed kinking with maximum flexion (squatting position) in the more rigid stents placed behind the knee (Figure 7A,B).

Primary Stress Points or Stressors

Two primary stressors appeared to affect stenting. The

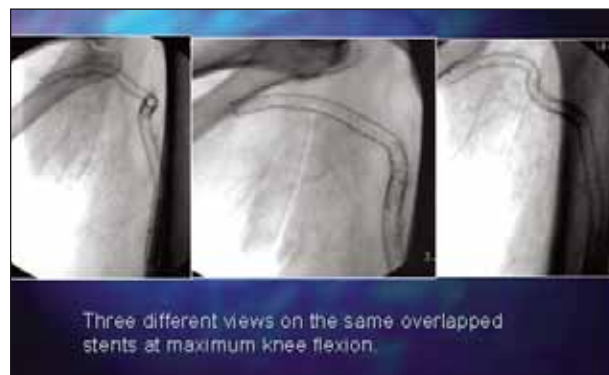


Figure 6. The stented popliteal artery compresses less than the bare artery during knee bending. This results in exaggerated bending of the stented artery during joint movement—a necessary morphologic change allowing foreshortening.

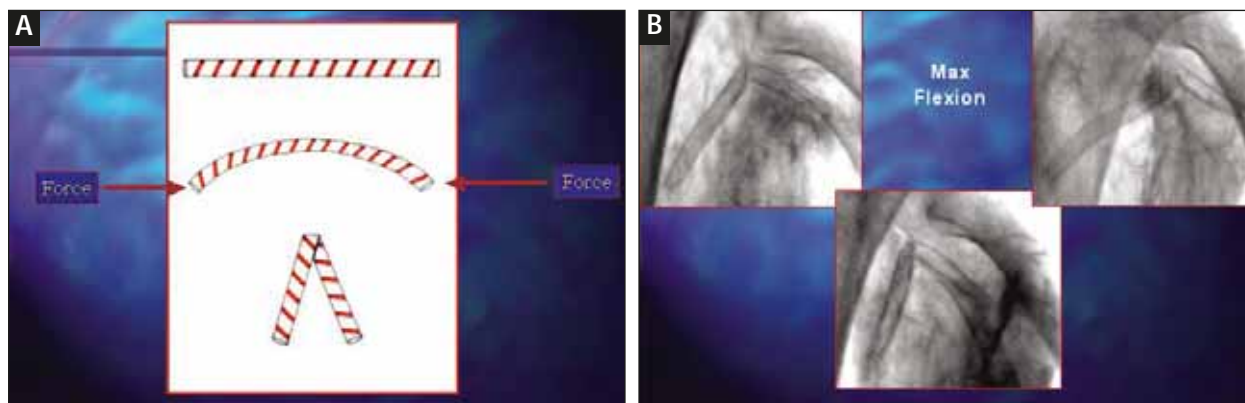


Figure 7. As forces are applied to a hollow tube, such as a straw, the tube will begin to bend until the resistance of the tube is overcome. At this point, failure will occur and the tube will kink (A). Just as a straw will eventually kink when bent too far, we saw kinking of the more rigid stents with maximum knee bending (B).

most significant stressor is the bending of the stent behind the knee. This movement results in severe foreshortening of the undersurface of the stent; that is, the lesser curvature of the stent is axially compressed while the greater curvature, or outer surface, is mildly elongated. The second stressor is uniform axial compression within the straight segments of the SFA and popliteal arteries.

These two stressors account for the majority of stent problems. Bending is found primarily behind the knee, with only mild bending occurring in the straight segment of the SFA. Axial foreshortening is seen in all segments of the femoral and popliteal arteries but is greatest in the popliteal artery. Torsion and elongation are not considered significant stressors within implanted stents.

Out-of-Plane Stent Overlap

An interesting observation was the overlapping of stented segments when a bare artery gap was left between stents. The artery axially shortens or compresses

with movement and, when two stents are placed next to each other but do not overlap, the stented segments shift into a different plane and ride over one another, severely deforming the course of the artery (Figure 8A,B).

Stresses, Stent Design, and Surface Finish

Although biomechanical forces in the lower extremity are very significant, stent design and surface finish are also key elements with regard to strut fractures and stent failures. Poorly polished stent surfaces will leave cracks, fissures, and retained slag, all of which result in metal fatigue, weakness, and strut failure. Stent design (open cell vs closed cell) can significantly alter the axial rigidity of a stent and add stressors to stent struts, leading to fractures over time with ambulation (Figure 9A,B).

LIMITATIONS OF THE STUDY

This study is a preliminary investigation of possible effects within the femoropopliteal arterial segment during

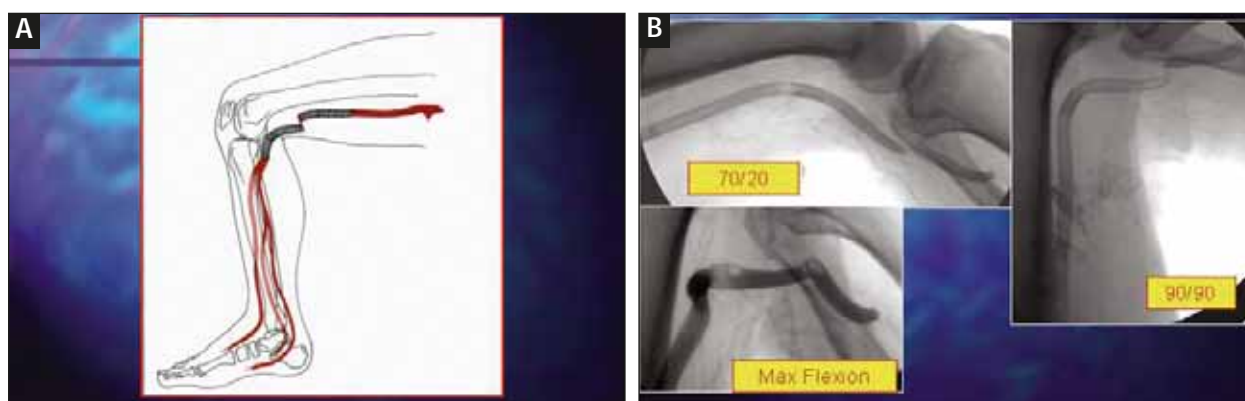


Figure 8. Illustration showing how adjacent stents separated by bare artery may shift out of plane during joint bending (A). Stents placed into the popliteal artery undergo varying degrees of morphologic changes with joint bending. These changes may be minor, such as gentle bending, or severe, such as overriding or kinking of adjacent or overlapped stents (B).

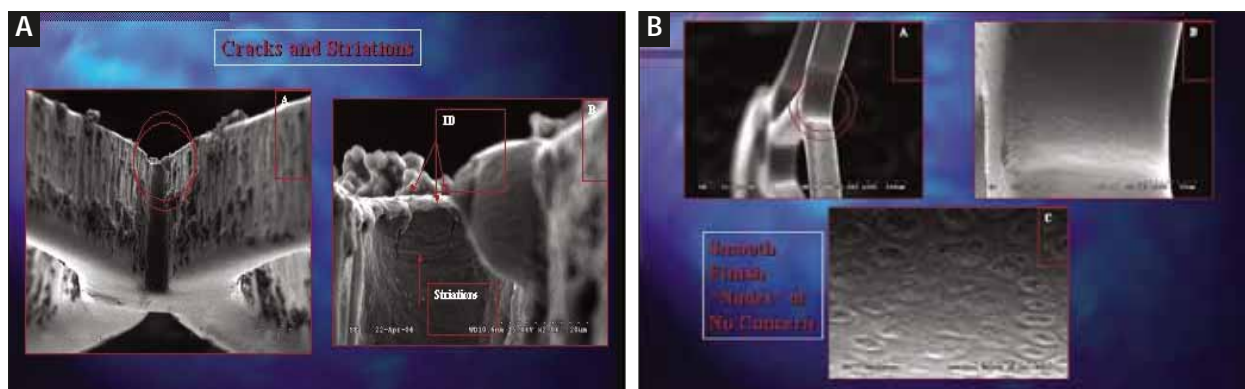


Figure 9. Scanning electron micrographs of two different commercially available stents showing wide variability in surface finishes. Cracks, striations, adherent slag, and pits are undesirable characteristics and may result in fractures (A). A smooth surface finish is desirable for stents placed into the femoropopliteal segment (B).

extremity movement. It is a work in progress and is limited by several factors, including limited sample size, nonatherosclerotic limbs, passive movement, no crossing of legs or limb twisting, no hyperextension or elongation, and only two stent types were tested. Certainly, further work is indicated for a more complete understanding of this vascular segment and the effect with stenting.

The Ideal Stent Design

Conceding the limitations of this study, it is tempting to conclude that the ideal stent design would be made up of a series of independent flexible rings (not interconnected) providing radial support without impeding or altering the physiologic axial compression and bending of the artery normally found with ambulation and positional changes. ■

Suggested Reading:

Allie DE, Hebert CJ, Walker CM. Nitinol stent fractures in the SFA. *Endovasc Today*. 2004;7:22-34.

Duda SH, Bosiers M, Lammer J, et al. Sirolimus-eluting versus bare nitinol stent for obstructive superficial femoral artery disease: The SIROCCO II trial. *J Vasc Interv Radiol*. 2005;16:331-338.

Gray BH, Sullivan TM, Childs MB, et al. High incidence of restenosis/reocclusion of stents in the percutaneous treatment of long-segment superficial femoral artery disease after suboptimal angioplasty. *J Vasc Surg*. 1997;25:74-83.

Lugmayr HF, Holzer H, Riedelsberger H, et al. Treatment of complex arteriosclerotic lesions with nitinol stents in the superficial femoral and popliteal arteries: a midterm follow-up. *Radiology*. 2002;222:37-43.

Oliva VL, Soulez GS. Sirolimus-eluting stent versus the superficial femoral artery: second round. *J Vasc Interv*

Radiol. 2005;16:313-315.

Phipp LH, Scott DJA, Kessel D, et al. Subclavian stent and stent-grafts: cause for concern? *J Endovasc Surg*. 1999;6:223-226.

Sabeti S, Mlekusch W, Amighi J, et al. Primary patency of long-segment self-expanding nitinol stents in the femoropopliteal arteries. *J Endovasc Ther*. 2005;12:6-12.

Scheinert D, Scheinert S, Sax J, et al. Prevalence and clinical impact of stent fractures after femoropopliteal stenting. *J Am Coll Cardiol*. 2005;45:312-315.

Van der Zaag ES, Legemate DA, Prins MN, et al. Angioplasty or bypass for superficial femoral artery disease? A randomized controlled trial. *Eur J Vasc Endovasc Surg*. 2004;28:132-137.

This study was sponsored by Guidant Corporation.

H. Bob Smouse, MD, is Assistant Professor of Clinical Radiology and Surgery, University of Illinois College of Medicine at Peoria, Central Illinois Radiological Associates, Peoria, Illinois. He has disclosed that he is a paid consultant to Guidant. Dr. Smouse may be reached at (309) 655-7125; bsmouse@cirarad.com.

Alexander Nikanorov, MD, PhD, is principal research associate from Guidant, Endovascular Solutions, Santa Clara, California. He has disclosed that he is salaried by Guidant. Dr. Nikanorov may be reached at (408) 845-3323; anikanor@guidant.com.

Danielle LaFlash, is a research associate from Guidant, Endovascular Solutions, Santa Clara, California. She has disclosed that she is salaried by Guidant. Ms. LaFlash may be reached at (408) 845-2223; dlaflash@guidant.com.

1. Scheinert D. Strut fracture in different self-expanding nitinol stents: a prospective evaluation. Presented at TCT 2004; Washington, DC.

2. Biamino G. Not all nitinol stents are alike in the SFA. Presented at ISET 2005; Miami, FL.