

Late Conversion After EVAR

Tips and tricks to help you successfully approach and treat these challenging cases.

BY EVAN C. LIPSITZ, MD, AND TAKAO OHKI, MD, PhD

Endovascular abdominal aortic aneurysm repair (EVAR), first reported in 1991, now represents the majority of aneurysm repairs performed at most centers throughout the world. The growing popularity of EVAR has proceeded at a dramatic pace fueled by improvements in graft manufacture and design, as well as graft availability, operator experience, and patient demand. Although EVAR can be performed with a high technical success rate, the midterm and long-term results are uncertain, and recipients of these grafts require close, ongoing, lifelong follow-up. The majority of endograft failures can be treated with an endovascular approach, and the methods for doing so continue to improve. However, in some cases, the development of endoleak with aneurysm enlargement, aneurysm enlargement without demonstrable endoleak, aortoenteric fistula, graft migration, or rupture may necessitate conversion to an open repair on an elective or sometimes emergent basis. With the ever-increasing number of these grafts being placed, the need for a systematic approach to problems associated with them, including their removal and conversion to open repair when necessary, will become increasingly important.

Preservation of the proximal end of an endograft was reported by May et al in 1999.¹ Preservation of the endograft in this case was necessary because the surgeon was unable to remove the suprarenal and pararenal portions of the endograft. We propose that, in many cases, preservation of part of the endograft is a virtue in that it avoids damage in the native arteries and may serve to buttress the suture lines of the new graft anastomoses. By incorporating the retained portion of the old graft in the suture line, the risk of type I endoleak beside this retained segment is eliminated.

MONTEFIORE EXPERIENCE

We previously reviewed our experience with late open conversion (>30 days) after EVAR to introduce the concept and advantages of endograft retention in this setting.² Currently, we have successfully performed more than 500 EVAR procedures for treatment of aortoiliac aneurysms. Several different endografts have been used throughout this experience, including EVT or Ancure (EVT/Guidant, Menlo Park, CA), Vanguard (Boston Scientific Corporation, Natick, MA), Talent (Medtronic Inc., Santa Rosa, CA), Excluder (Gore & Associates, Flagstaff, AZ), AneuRx (Medtronic), Corvita (Schneider/Boston Scientific Corporation), Zenith (Cook Incorporated, Bloomington, IN), Quantum (Cordis, Warren, NJ), and Montefiore Endovascular Graft System (MEGS) grafts. Patients were followed with serial CT scans and routine physical examinations at 1, 6, and 12 months postoperatively, and yearly thereafter. Indications for late conversion included rupture, aortoenteric fistula, and aneurysm enlargement of ≥ 2 cm, with or without demonstrable endoleak.

There were 11 (2.2%) patients who required late conversion to open repair at an average of 30 months (range, 10-64 months) from the time of the original procedure (Table 1). Ten of the original EVAR procedures were performed electively and one was performed for aneurysm rupture. Nine delayed conversions were performed at our institution and two (patients 1 and 2) were performed at other institutions. The mean age of the patients undergoing delayed conversion was 76 ± 8.4 years and all were men. These patients had a number of associated comorbidities, including coronary artery disease (82%), chronic obstructive pulmonary disease (18%), diabetes mellitus (27%), hypertension (90%), and

TABLE 1. PATIENTS UNDERGOING DELAYED CONVERSION TO OPEN REPAIR AFTER EVAR

Patient No.	Endograft	Time to Conversion (Months)	Indication	Clamp Placement	Findings	Portion of Endograft Left <i>In Situ</i>
1	MEGS	55	Rupture	Supraceliac	Proximal type I endoleak	None
2	Talent	10	Aortoenteric fistula	Thoracic aorta	Aortoenteric fistula from jejunum to bare stent of graft	None
3	Vanguard	28	Type II endoleak	Infrarenal	Type II endoleak	None
4	Vanguard	64	Type III endoleak migration	Suprarenal	Type III endoleak	Distal
5	MEGS (iliac graft)	18	Rupture	Supraceliac balloon, then infrarenal clamp	Ruptured hypogastric aneurysm	Distal
6	Talent	21	Proximal type I	Supraceliac balloon, then infrarenal clamp	Proximal type I endoleak repaired with AneuRx cuff-covered bilateral renal arteries	Distal
7	Talent	38	Rupture	Infrarenal	Graft migration	Distal
8	MEGS (iliac graft)	17	Rupture	Infrarenal	Proximal type I endoleak	Distal
9	AneuRx	26	Rupture	Infrarenal	Type I endoleak	Distal
10	MEGS (for rupture)	15	Enlarging AAA	Graft	Endotension	Entire graft
11	Talent	31	Rupture	Supraceliac	Type II endoleak	Entire graft

MEGS, Montefiore Endovascular Graft System.

chronic renal insufficiency (9%). Two (18%) of the patients were on warfarin for auricular fibrillation. Two of these patients (patients 5 and 8) were originally treated for isolated iliac artery aneurysms. The mean aneurysm size at the time of EVAR was 6.9 cm (range, 6-10 cm) for all patients and 7 cm (range, 6-10 cm) when excluding patients with isolated iliac artery aneurysms. The mean aneurysm size at the time of late conversion was 8.2 cm (range, 6-12 cm) for all patients and 8.4 cm (range, 6-12 cm) excluding patients with isolated iliac artery aneurysms. Nine of these patients had an increase in aneurysm size, and two patients had stable aneurysm size. There were no significant differences in patient demographics or follow-up between all patients undergoing EVAR and those who required delayed conversion other than the percentage of men, which was 87% of all patients undergoing EVAR. Of the seven patients presenting with rupture, all who presented had pain and six had hypotension. Of the two patients who died, one

(patient 1) had extensive blood loss both preoperatively and intraoperatively (due to extensive scarring and difficult graft removal), and the other (patient 2) died of multisystem organ failure several days after extra-anatomic bypass.

Four of the 11 patients (36%) underwent a total of six secondary procedures for treatment of endoleaks prior to undergoing late open conversion. One patient underwent translumbar decompression for an expanding aneurysm and endotension without demonstrable endoleak (patient 10). Another patient (patient 6) required stent placement within the limb of a bifurcated graft, which subsequently thrombosed necessitating a femorofemoral bypass. This patient ultimately developed a type I endoleak and underwent late conversion when an attempt at endovascular repair with a proximal AneuRx cuff failed, resulting in coverage of the renal arteries. Patient 3 underwent coil embolization of a patent ilio-lumbar artery via a hypogastric artery approach for the

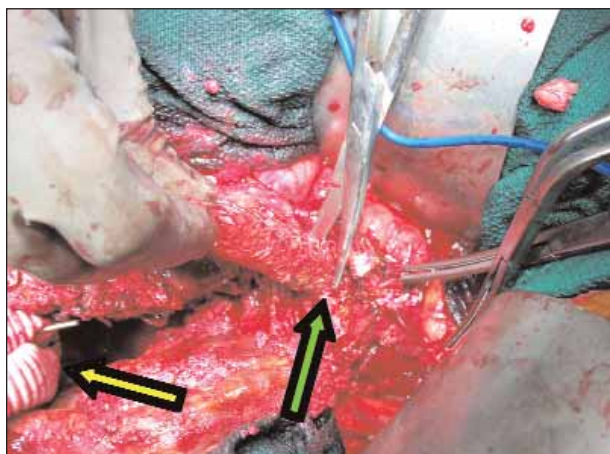


Figure 1. Iliac limb of endograft being cut at the iliac artery orifice (green arrow). Portion of new graft with proximal anastomosis completed is seen (yellow arrow).

treatment of type II endoleak. Patient 4 had a dislocation of the contralateral limb of a bifurcated graft from the common iliac artery, which was treated with use of two Vanguard iliac extensions to re-seat the graft. This patient later developed a separation at the junction of these limbs, which was unsuccessfully treated with two bridging limbs. None of these four patients undergoing secondary interventions presented with rupture.

EVARs requiring late conversion were performed using Talent (n=4), Vanguard (n=2), AneuRx (n=1), and surgeon-made (n=4) grafts. Conversion to open repair was performed for aneurysm rupture in seven patients (four type I endoleaks, two type II endoleaks, one aortoenteric fistula) and aneurysm enlargement in four patients (one type I endoleak, one type II endoleak, one type III endoleak, one endotension). The surgical approach was transabdominal in nine patients. One patient (patient 2) required a left thoracotomy in addition to a transabdominal approach for supraceliac control due to dense adhesions in the upper abdomen. One patient who was converted using a retroperitoneal approach (patient 6) had an occlusion of the right limb of the endograft with a functioning femorofemoral bypass. Mean operating time for these late conversions was 6.4 ± 2.3 hours, with an average blood loss of $3,800 \pm 2,400$ mL. The mean supraceliac and/or suprarenal ischemia time for the six patients requiring this approach was 15 minutes (range, 8-27 minutes).

Complete removal of the endograft with supraceliac cross clamping was performed in two cases. One of these patients (patient 1) had a known type I endoleak but refused intervention. He went on to rupture and did not survive the operation due to a massive myocardial infarction. The other patient (patient 2) had an aorto-

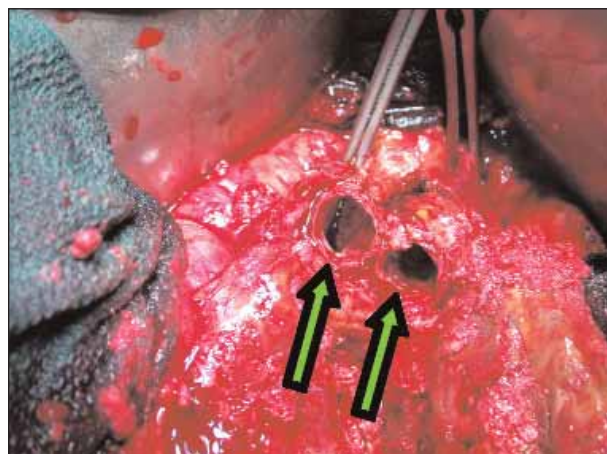


Figure 2. Residual graft limbs at iliac orifices (green arrows).

teric fistula and died 2 weeks after the procedure after graft explantation and axillobifemoral bypass. In the remaining nine cases, the endograft was either completely (n=1) or partially (n=6) removed, or left *in situ* (n=2). Supraceliac balloon control (n=2), supraceliac clamping (n=1), suprarenal clamping (n=1), or infrarenal clamping (n=5) was utilized in these cases. All nine of these patients survived the operation. Distal arterial control was achieved using clamps on the common iliac arteries, although Fogarty balloon control can also be used. In the setting of an unsupported graft (MEGS), the graft itself was clamped within the aneurysm sac.

The two cases in which the endografts were left *in situ* were performed as follows. In the first procedure performed for endotension, the surgeon-made aorto-unifemoral (MEGS) graft was divided within the aneurysm sac. A standard tube graft was placed over the endograft (as a sleeve). The endograft was then sutured back together, restoring continuity and flow. Next, the standard graft was sutured both proximally and distally, incorporating the endograft in the anastomosis proximally. Thus, flow was maintained through the endograft and buttressed by the standard graft. Any further transudate was then contained by the standard graft preventing the development of endotension. The second procedure was performed for rupture. At the time of surgery, the graft was noted to be well-incorporated both proximally and distally. Four bleeding lumbar arteries were oversewn, and the sac was closed tightly over the endograft. In the remaining seven cases, the endograft was transected, and the proximal portion only (n=6) or the proximal and distal portions (n=1) were excised. The proximal graft was removed in those cases in which proximal stent migration was present, facilitating its extraction from the neck. When the proximal graft was removed, a standard aortic graft was placed between the

proximal neck and the remaining endograft (Figures 1 through 4). To avoid future distal type I endoleaks, the distal end of the new graft (standard) was sewn to the residual endografts, as well as to the iliac artery orifices. All surviving patients continued to do well and remained without complications associated with the endograft remnant at a mean follow-up of 26 months (range, 3-64 months). One patient had a small myocardial infarction 1 month after the procedure (patient 7), and one patient developed a small-bowel obstruction necessitating lysis of adhesions 2 months postoperatively (patient 4). The perioperative morbidity and mortality rate for all patients was 27%. Patients with any or all graft left *in situ* had a perioperative morbidity rate of 13%, whereas patients whose grafts were completely excised had a perioperative morbidity of 67%.

TECHNICAL CONSIDERATIONS

The late removal of aortic endografts is technically challenging, especially when performed in the acute setting.¹⁻⁹ The overall delayed conversion rate for patients undergoing EVAR has been estimated to be between 0.6% and 4.5%. The mortality rate seen in our patients is comparable to that of other series and underscores the difficulty in performing these procedures.

The exact approach to the late removal of endografts depends on several factors, including the type and condition of the endograft originally placed; the presence of suprarenal stents and/or hooks or barbs; the presence of any additional grafts, cuffs, or coils placed as secondary interventions; whether the proximal and distal fixation points are intact; the current aneurysm morphology; the presence of periaortic scarring or inflammation; and most importantly, the urgency of the repair. Local tissue reaction with at least some incorporation of endografts has been shown, especially at the proximal portion. Although not sufficient to provide secure long-term fixation, these changes contribute to the difficulties associated with late endograft removal. Simple traction or traction with compression of the graft may not be enough to permit graft retrieval. It may be necessary to cut either the proximal bare stents or the proximal graft itself, including stents, and wire cutters should be available for this purpose. Endografts with stents located on the outside of the graft material may also be more difficult to remove than those with stents located inside or contained within the graft material because of the inflammatory reaction incited by the stents. Additionally, when stents are positioned outside the graft, they may cause more damage to the native arteries during removal than would be the case if only the graft material were exposed to the native artery.

As can be the case in the setting of aneurysm rupture,

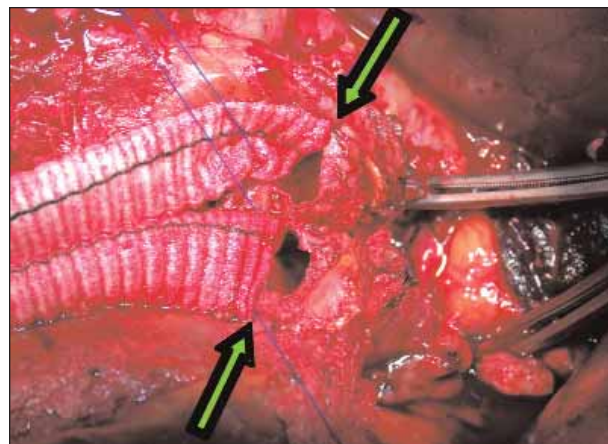


Figure 3. Standard graft being anastomosed to residual endograft incorporating iliac artery orifices (green arrows).

we have found that the use of a compliant balloon placed in the supraceliac aorta via a brachial or femoral approach can decrease the time until proximal aortic control is achieved by an open approach. It may also reduce the need for what can be difficult dissection of the suprarenal and/or supraceliac aorta, as well as the necessity for an extensive arteriotomy. Once the graft has been removed or infrarenal control has been achieved, the balloon can be deflated, reperusing the visceral vessels.

DISCUSSION

In our series, all patients (except one) were converted using a midline transperitoneal approach. Although we prefer a midline transperitoneal incision for these cases, the retroperitoneal approach does facilitate exposure of the suprarenal and, if required, supraceliac aorta. The disadvantages of the retroperitoneal approach in this setting include limited exposure to the right iliac system. This could, however, be easily overcome by making an incision in the right retroperitoneum. Additionally, should the orifice of the right renal artery be damaged during explantation, control and exposure of the artery may be difficult via this approach.

Although excision of the proximal endograft has been the focus of most reports regarding delayed conversions, removal of the distal endograft may also be prohibitive. Removal of the distal limbs often requires significant traction and/or probing of the iliac arteries, which can render these arteries unsuitable as target vessels for outflow.

Although complete removal of the endograft and replacement with a standard graft during delayed conversion is preferable, we believe that in many cases, complete or even partial endograft removal may be unnecessary and may unduly complicate the procedure, adding to its

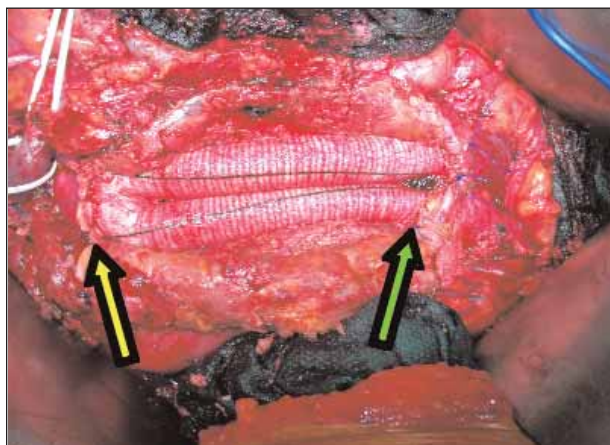


Figure 4. Completed repair. Proximal anastomosis (yellow

arrow). In only one of nine patients who survived the perioperative period, the endograft was completely excised. We can only speculate as to whether partial or complete graft preservation could have improved the outcome in any of the three patients with complete endograft removal relative to the group with partial or complete endograft preservation.

In cases in which the standard graft is anastomosed to the endograft, we recommend incorporating the native artery into the suture line (Figures 3 and 4) such that the seal is not completely dependent on the fixation provided by the endograft. Additionally, suturing to an endograft alone may not provide as durable an anastomosis as suturing to standard grafts. Another measure that can be employed in cases in which a portion of the endograft is left *in situ* is to close the aneurysm sac tightly over the entire new graft complex to prevent any kinking, twisting, or buckling of the graft that could lead to limb dislodgment.

In the case of the patient with endotension (patient 10), the graft (MEGS) remained firmly seated both proximally (suprarenal balloon-expandable stent) and distally (endoluminal anastomosis). The repair was designed to further secure the proximal anastomosis, to protect against the development of type I endoleak and to eliminate the effect of any fluid translocation from the graft material into the aneurysm sac. Patient 11 had a rupture due to a type II endoleak that could not be adequately characterized preoperatively and, in the setting of an enlarging aneurysm, the patient was scheduled for surgery. At operation, the endograft was extremely well-seated, and attempts to remove all or part of it would likely have resulted in significant trauma to the vessels involved, as well as complicated the operation in this patient with multiple comorbidities.

CONCLUSION

Open repair in the setting of a long-standing endo-

graft offers several unique technical challenges but can be successfully accomplished in most patients. With the large numbers of endografts being implanted worldwide, the problem of delayed conversion to open repair will only increase in importance. The basic principles and techniques of endograft explantation should be familiar to all vascular surgeons. Due to the wide variety of devices available (old and new), surgeons must also be familiar with these devices and their basic characteristics. Although the approach to each patient requiring delayed conversion must be individualized, preservation of all or part of the endograft is possible in many patients. This technique simplifies the operative approach, reduces the amount of dissection required, and is often preferable to complete endograft removal. Whether the residual portions of previously placed endografts may lead to future problems, such as infection or anastomotic aneurysms, is not currently known, but the benefits of this approach seem to outweigh any potential risks. ■

Evana C. Lipsitz, MD, is Associate Professor of Surgery, Montefiore Medical Center and the Albert Einstein College of Medicine, Bronx, New York. He has disclosed that he holds no financial interest in any product or manufacturer mentioned herein. Dr. Lipsitz may be reached at (718) 920-2016; elipsitz@aol.com.

Takao Ohki, MD, PhD, is Chief and Professor of Vascular Surgery, Montefiore Medical Center and the Albert Einstein College of Medicine, Bronx, New York. He has disclosed that he is the Founder of Vascular Innovation, and is a consultant for Cordis, Medtronic, Gore, CardioMEMS, and Aptus Inc. Dr. Ohki may be reached at (718) 920-4707; takohki@msn.com

1. May J, White GH, Harris JP. Techniques for surgical conversion of aortic endoprosthesis. *Eur J Vasc Endovasc Surg.* 1999;18:284-289.
2. Lipsitz EC, Ohki T, Veith FJ, et al. Delayed open conversion following endovascular aortoiliac aneurysm repair: partial (or complete) endograft preservation as a useful adjunct. *J Vasc Surg.* 2003;38:1191-1198.
3. Bockler D, Probst T, Weber H, et al. Surgical conversion after endovascular grafting for abdominal aortic aneurysms. *J Endovasc Ther.* 2002;9:111-118.
4. Lyden SP, McNamara JM, Sternbach Y, et al. Technical considerations for late removal of aortic endografts. *J Vasc Surg.* 2002;36:674-678.
5. Harris PL, Vallabhaneni SR, Desgranges P, et al. Incidence and risk factors of late rupture, conversion, and death after endovascular repair of infrarenal aortic aneurysms: the EUROSTAR experience. European Collaborators on Stent/graft techniques for aortic aneurysm repair. *J Vasc Surg.* 2000;32:739-749.
6. Jacobowitz GR, Lee AM, Riles TS. Immediate and late explantation of endovascular aortic grafts: the endovascular technologies experience. *J Vasc Surg.* 1999;29:309-316.
7. de Vries JP, van Herwaarden JA, Overtoom TT, et al. Clinical outcome and technical considerations of late removal of abdominal aortic endografts: 8-year single-center experience. *Vascular.* 2005;13:135-140.
8. Kong LS, MacMillan D, Kasirajan K, et al. Secondary conversion of the Gore Excluder to operative abdominal aortic aneurysm repair. *J Vasc Surg.* 2005;42:631-638.
9. Tiesenhausen K, Hessinger M, Konstantiniuk P, et al. Surgical conversion of abdominal aortic stent-grafts: outcome and technical considerations. *Eur J Vasc Endovasc Surg.* 2006;31:36-41.