

# Percutaneous Removal of a Misplaced “Permanent” LGM Vena Tech Filter

An incorrectly placed filter is retrieved before it migrates to the heart.

BY EYAL BARZEL, MD, AND JAMES MCGUCKIN, MD

## CASE PRESENTATION

A critical-care trauma patient, with severe head trauma was undergoing surgical procedures performed as per the trauma team protocol, which included prophylactic filter placement. In anticipation of a prolonged recovery, a permanent implant was chosen rather than a retrievable filter. An LGM Vena Tech inferior vena cava (IVC) filter (Braun, Bethlehem, PA) was placed through its 11-F sheath. The filter placement kit provided by the manufacturer allows this filter to be placed either from a femoral or jugular approach, but the operator must properly orient the filter when loading it into the sheath. The surgical resident who loaded the filter mis-

“A misplaced filter may not function properly in preventing pulmonary emboli, and it is also an embarrassment to the physician.”

understood the instructions, and inadvertently loaded the filter upside-down.

When the filter was deployed in the IVC, the surgical team saw it migrate fluoroscopically and lodge near the diaphragmatic hiatus. The barbs of the LGM Vena Tech filter are designed to penetrate the wall of the IVC to prevent migration toward the heart. The upside-down filter did not resist migration because its barbs could not engage the caval wall. The interventional radiology team was asked to remove the filter if possible. The filter is demonstrated on an initial fluoroscopic image from the retrieval that was subsequently performed (Figure 1).

## COURSE OF ACTION

The primary concern for the patient's safety was to prevent further migration of the filter into the heart. If the filter entered the right ventricle, it might cause severe arrhythmias or become entangled with a heart valve, resulting in deadly cardiac dysfunction. Filter migration might occur spontaneously due to respiratory variation, Valsalva maneuver, or as a result of daily life activities. It could also occur during an attempt to retrieve the filter. The primary goal then was to stabilize the filter during possible retrieval.

A filter kit was opened, and a “bench” evaluation was performed. Although not sold for “over-the-wire” deployment, the filter was designed with a hole in its

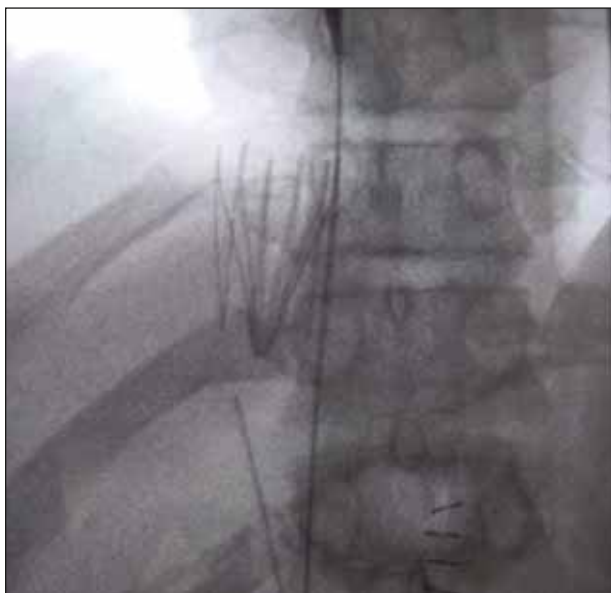

Figure 1. Upside-down filter in the IVC, lodged at the diaphragmatic hiatus.

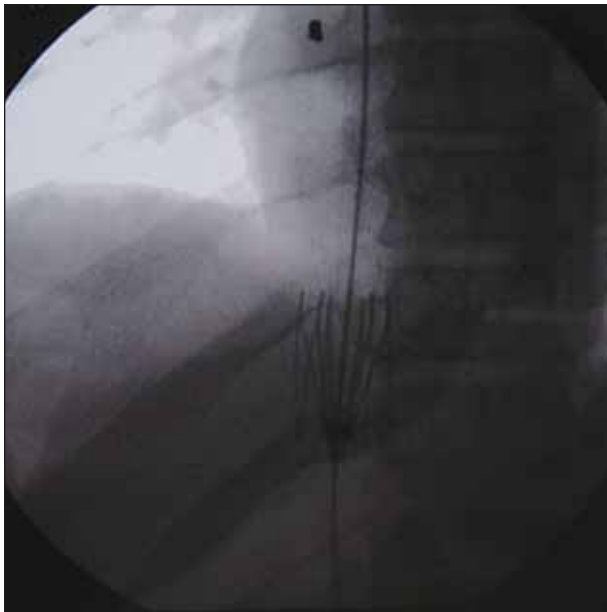

Figure 2. The tip of a 14-F sheath positioned within the center of the filter appears as a horizontal band. A guidewire stabilizes the filter, but is not in fact through the center hole.

center. A .035-inch guidewire passes easily through the center hole. A guidewire placed through this hole would stabilize the filter and prevent migration to the heart.

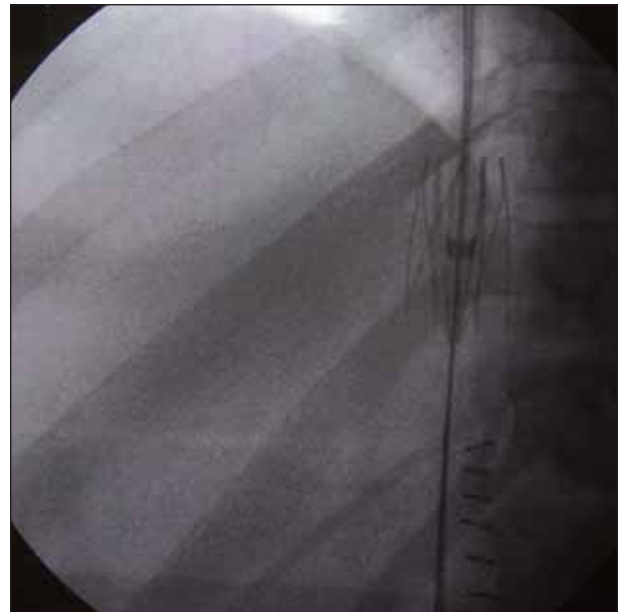

Figure 3. A second guidewire placed successfully through the center hole of the filter. The first wire was subsequently removed.

With the guidewire controlled at both ends, it is possible to pass a dilator from above and a sheath from below and partially resheath the filter. The dilator tip is partially

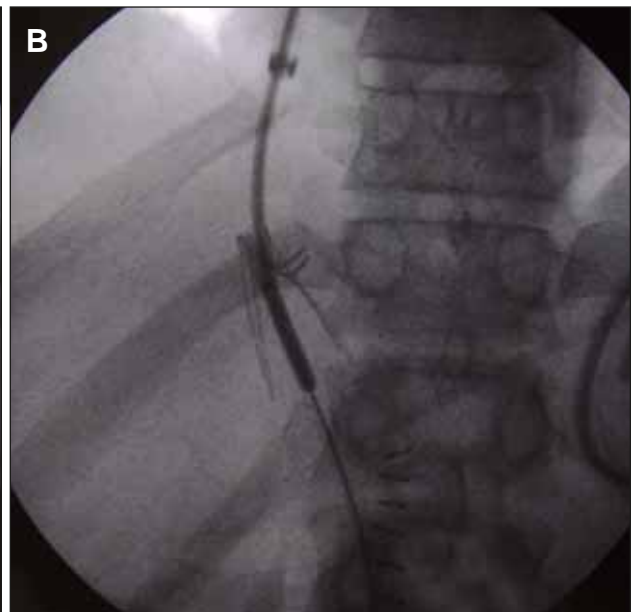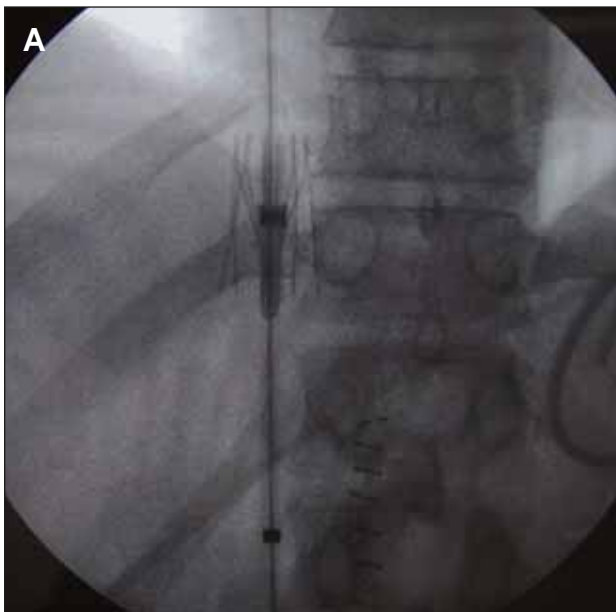


Figure 4. A single guidewire traverses the center hole of the filter. The tip of an 11-F sheath, advanced over the wire from below, appears as a black band inferior to the filter. A 6-F dilator (not radiopaque) advanced over the wire from above engages the filter and deforms its center as compared with Figure 3. The stabilizing bars prevent the filter from traveling caudally down the IVC (A). The dilator held the filter in place so the 11-F sheath could be advanced over the filter until only the stabilizing bars were left exposed (B).

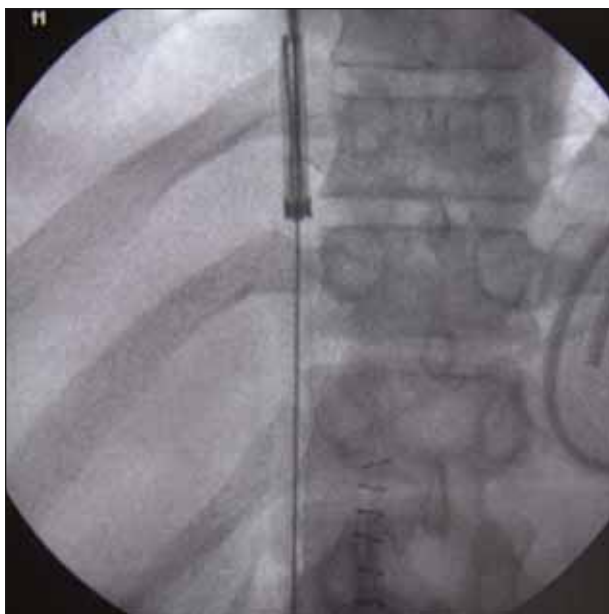


Figure 5. The 14-F sheath was advanced over the stabilizing bars and 11-F sheath, completely resheathing the filter.

cut off to make the end flat so that it properly engages the filter. The filter cannot be completely resheathed with one sheath because it has vertical stabilizing bars that are attached to each of its legs. These stabilizing bars are designed to prevent tilting of the filter when properly placed in the IVC. These stabilizing bars will not enter a sheath advanced from below. However, once partially resheathed, a second larger sheath advanced over the wire from above can resheath the stabilizing bars. Once entrapped within the sheaths, by moving both sheaths along the wire, it should then be possible to reposition or remove the filter. This was tried several times with different sheath and dilator combinations *ex vivo*, until it was clear that this could be accomplished.

Using ultrasound guidance, a 40-cm-long, 14-F sheath was placed via a right internal jugular vein puncture, and an 11-cm-long, 14-F sheath was placed via a right femoral vein puncture. The 40-cm sheath was advanced up to the filter. A .035-inch, 280-cm, angled Glidewire (Boston Scientific Corporation, Natick, MA) was used to engage the filter hole with the aid of a 65-cm, 5-F Berenstein catheter (Cook Incorporated, Bloomington, IN). The wire tip was then retrieved from the femoral approach using a nitinol snare (ev3 Inc., Plymouth, MN). Multiple angled images suggested that the wire was through the center hole (Figure 2). However, when a dilator was passed from above, it did not engage the filter, suggesting that the wire was next to, but not through, the center hole. It did seem to be partially sta-

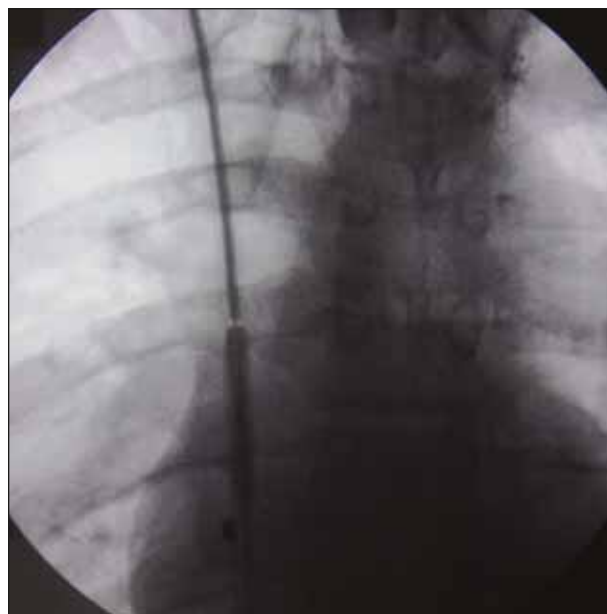


Figure 6. The 11-F sheath was advanced as far as it would go, and the collapsed filter is now within the 14-F sheath in the middle of the chest.

bilizing the filter, and an attempt with a second Glidewire was successful (Figure 3).

The first wire was removed, and the 11-F deployment sheath that comes with the filter kit was then advanced over the wire from below, as a 6-F dilator with its tip cut off was advanced over the wire from above. As a result, the filter was partially resheathed (Figure 4A,B). Subsequently, the 40-cm, 14-F sheath was advanced from above and the stabilizing bars were resheathed (Figure 5). The 11-F sheath was advanced as far as it would go within the 14-F sheath (Figure 6).

Unfortunately, it was not long enough to advance the filter in the sheath out the jugular vein. However, the 11-F sheath was then pulled back out of the 14-F sheath, and the filter remained behind within the 14-F sheath. This occurred because of friction between the 14-F sheath and filter, which has barbs that are designed to limit forward motion of the filter. The 14-F sheath with the filter inside was then pulled out of the body (Figure 7). A Simon nitinol IVC filter (Bard Incorporated, Philadelphia, PA) was then deployed from a right femoral approach. A postprocedure inferior vena cogram was unremarkable (Figure 8).

## DISCUSSION

IVC filters can be safely retrieved shortly after placement if they can be captured and resheathed. In this case, the filter was "captured" on a guidewire. Recently,

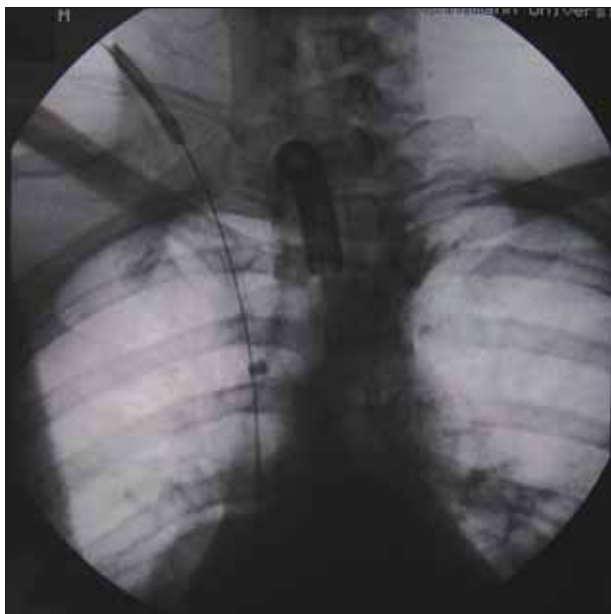


Figure 7. As the 14-F sheath is removed, the filter travels with it, and is seen in the sheath exiting the neck.

the FDA has approved filters that are specifically designed to be retrievable. These include the Gunther Tulip filter (Cook Incorporated, Bloomington, IN) and the Recovery nitinol filter (Bard Incorporated).<sup>1,2</sup> These filters are currently being used in patients whose contraindication to anticoagulation is short term.

Standard IVC filters are considered permanent implants. They are generally low in profile, and are easy to place with a low complication rate in experienced hands. By design, they may be more resistant to migration than currently available temporary filters. Until this is disproved, they will probably remain the primary filter used in most patients, whose contraindication to anticoagulation is long-term, or in whom anticoagulation alone is not sufficient.

The difficulty in removing a permanent implant depends on its design and represents an unusual challenge to an interventionist, but has been previously reported.<sup>3-6</sup>

A misplaced filter may not function properly in preventing pulmonary emboli, and it is also an embarrassment to the physician placing the filter. It may also lead to vessel thrombosis, as trapped emboli may be deflected toward the caval wall, leading to further stagnation and clot propagation. Nevertheless, as long as it is placed within the venous system, and is in a stable position, it is not likely to do the patient any harm. The poorly positioned filter can be left alone, and a second

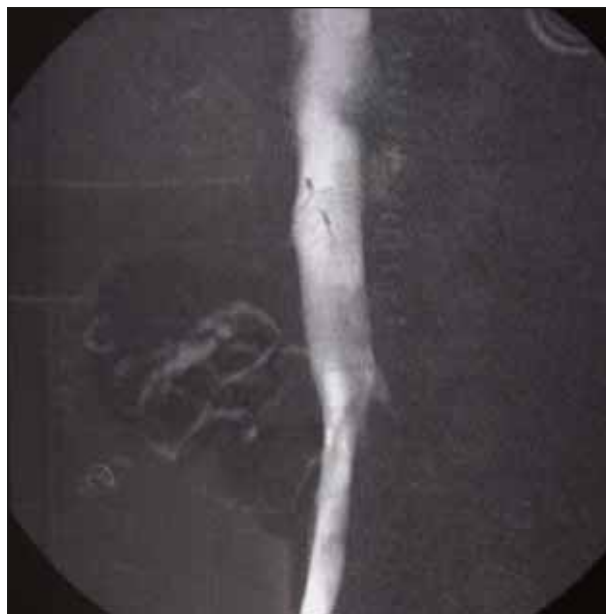

Figure 8. A Simon nitinol IVC filter has been properly deployed, and a postprocedure inferior vena cavogram shows normal findings.

filter can be placed properly. However, an unstable filter with a potential to migrate to the heart should be retrieved or repositioned and placed in a stable location position, if possible. ■

*Eyal Barzel, MD, is the Director of Research and Staff Physician at the Philadelphia Vascular Institute, Philadelphia, Pennsylvania. He has disclosed that he holds no financial interest in any product or manufacturer mentioned herein. Dr. Barzel may be reached at (215) 742-5662; eyal@barzel.org*

*James McGuckin, MD, is Medical Director of Philadelphia Vascular Institute, Philadelphia, Pennsylvania. He has disclosed that he holds no financial interest in any product or manufacturer mentioned herein. Dr. McGuckin may be reached at (215) 742-5662; jamesmcguckin@earthlink.net.*

1. Millward SF, Olivia VL, Bell SD, et al. Gunther Tulip retrievable vena cava filter: results from the Registry of the Canadian Interventional Radiology Association. *J Vasc Interv Radiol.* 2001;12:1053-1058.
2. Asch MR. Initial experience in humans with a new retrievable inferior vena cava filter. *Radiology.* 2002;225:835-844.
3. Arjomand H, Surabhi S, Wolf NM. Right ventricular foreign body: percutaneous transvenous retrieval of a Greenfield filter from the right ventricle: a case report. *Angiology.* 2003;54:109-113.
4. Nutting C, Coldwell D. Use of a TrapEase device as a temporary caval filter. *J Vasc Interv Radiol.* 2001;12:991-993.
5. Rosenblum JD, Boyle CM. Percutaneous retrieval of a Vena-Tech filter displaced during central line placement. *AJR.* 1996;166:994-995.
6. Salampour H, Rivits SM, Kaufman JA. Percutaneous transfemoral retrieval of a partially deployed Simon nitinol filter misplaced into the ascending lumbar vein. *J Vasc Interv Radiol.* 1996;7:917-919.