

# Embolization of a Type I Endoleak

A challenging presentation treated using hydrocoils, bare platinum coils, and n-BCA as embolic agents.

BY DANIEL PUTTERMAN, MD; ERIC J. GANDRAS, MD;  
CRAIG R. GREBEN, MD; AND AVI SETTON, MD

**E**ndovascular repair of abdominal aortic aneurysms (EVAR) has proven to be a safe and effective treatment option when favorable anatomy is present. Type I endoleaks are uncommon but can occur when there is angulation of the aneurysm neck, thrombus within the neck, or migration of the graft. Treatment options include extension of the graft proximally or embolization of the leak. Embolic agents previously described include fibered coils and liquid agents such as n-butyl cyanoacrylate (n-BCA). This article describes embolization of a type I endoleak using a combination of hydrogel-coated and bare platinum microcoils along with n-BCA.

## CASE REPORT

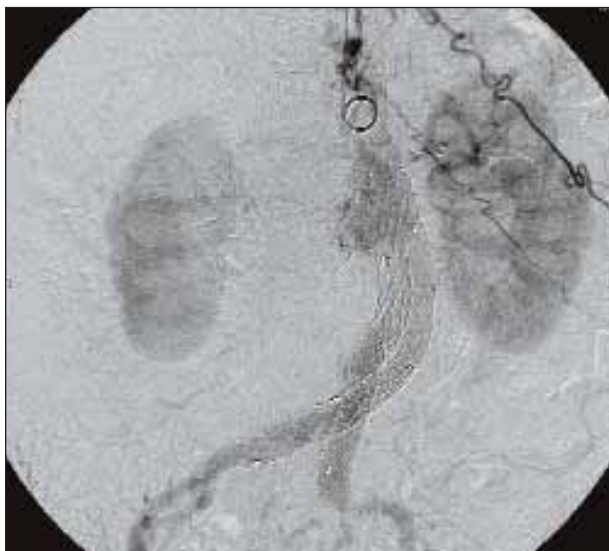
The patient is a 79-year-old female with a history of hypertension, insulin-dependent diabetes mellitus, asthma, and chronic obstructive pulmonary disease, who was found to have a 6-cm infrarenal abdominal aortic aneurysm. The anatomy of the aneurysm was favorable for an endovascular approach except for the presence of thrombus laterally within the neck. The risk of open aneurysm repair was believed to be greater than that of endovascular repair. The patient subsequently underwent successful endovascular repair with an AneuRx modular bifurcated graft (Medtronic, Inc., Minneapolis, MN) without incident. The patient did not return for her initial follow-up, a contrast-enhanced computed tomography (CT) scan of the abdomen, until 9 months after repair. The CT scan demonstrated an endoleak proximally along the right lateral graft, which suggested a type I leak and interval enlargement of the aneurysm to 6.5 cm (Figure 1). Angiography confirmed that a type I endoleak was present with good correlation with the location identified on the CT

scan along the right aspect of the proximal graft (Figure 2). It also appeared that the graft had slipped caudally, approximately 1 cm from where it had been placed originally.

Because of the patient's age and associated comorbidities, we decided to attempt embolization of the endoleak rather than attempt extending the graft further proximally, which would require suprarenal fixation. Thrombus at the neck was also a concern with respect to our ability to obtain an adequate seal if the graft was extended. Attempts at catheterizing the aneurysm sac from a femoral approach were unsuccessful due to the geometry of the graft and leak. Catheterization of the sac was possi-

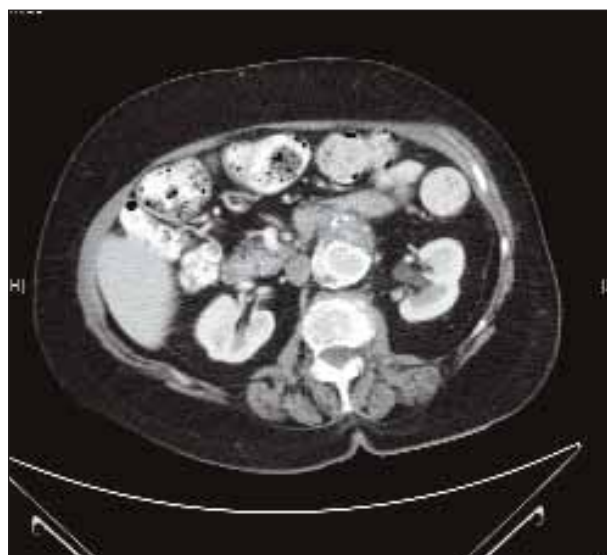

Figure 1. A contrast-enhanced CT scan demonstrates contrast within the aneurysm sac along the right aspect of the graft consistent with a type I endoleak.



**Figure 2.** An aortogram demonstrates a type I endoleak corresponding to the leak identified on CT imaging.

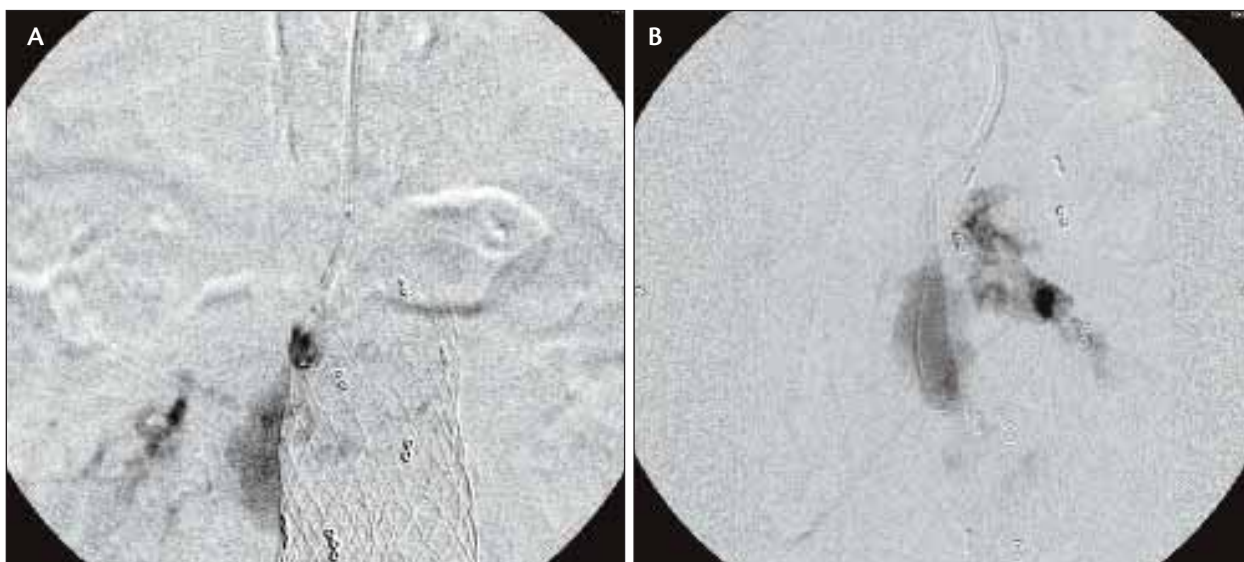
ble with a reverse curve catheter, but a stable position could not be maintained to embolize the sac. The patient returned for a repeat angiogram via a left brachial approach. Via the left brachial artery, a 6-F Envoy (Codman Neurovascular, Raynham, MA) guiding catheter was placed into the abdominal aorta, and via this catheter, a Prowler Plus (Codman Neurovascular) microcatheter and a Silver Speed 14 (ev3, Plymouth, MN) guidewire were used to catheterize the aneurysm sac (Figure 3). The sac was embolized using a combination of bare platinum and hydrogel-coated detachable microcoils (MicroVention Terumo, Aliso Viejo, CA)

(Figure 4). The embolization was completed with an injection of 0.6 cc of 50% n-BCA (Cordis Corporation, Warren, NJ) at the top of the coil mass to further seal the entry into the aneurysm sac. Postembolization images demonstrated no further endoleak with successful exclusion of the aneurysm sac; there were no complications (Figure 5). A noncontrast CT scan the day after embolization showed good correlation between the location of the embolization and the endoleak as demonstrated by the pretreatment CT and the lack of complications (Figure 6).

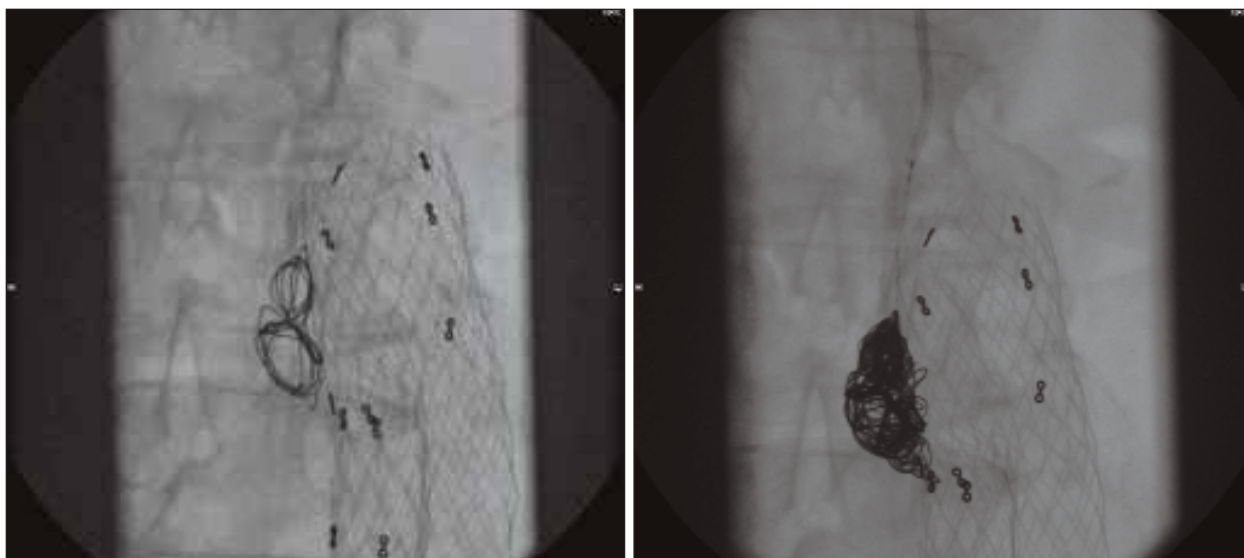
## DISCUSSION

EVAR has evolved to become a successful alternative to open surgical repair. Persistent flow within the aneurysm sac as the result of a leak and subsequent rupture of the aneurysm is the most serious complication of EVAR. Leaks have been classified according to the sites of blood flow.<sup>1</sup>

Type I endoleaks occurring at the proximal fixation point are high-pressure leaks with an increased risk of rupture, and therefore necessitate urgent intervention. They can occur for several reasons including angulation at the aneurysm neck, mural thrombus at the landing site, graft malposition, migration, or underdilatation.<sup>2</sup> Surgical repair techniques include the use of extension cuffs and repeat balloon angioplasty. However, repair of proximal type I endoleaks by graft extension has the associated risk of excluding the renal arteries.<sup>3</sup> Consideration for embolization is therefore often given to patients with challenging anatomy or with comorbidities precluding repeat surgery. In the patient presented, the combination of thrombus at the neck and migration of the graft both contributed to the development of a type I leak. As more



**Figure 3.** Selective angiography (A) and superselective catheterization of the proximal leak with a microcatheter (B) via a brachial approach.



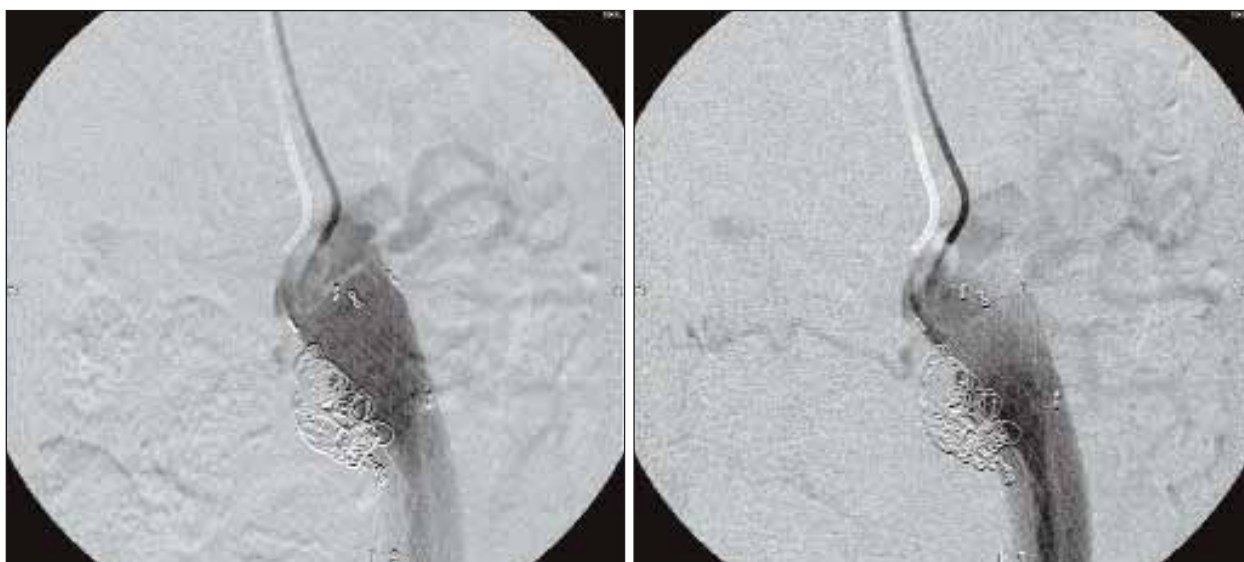
**Figure 4.** Embolization of the aneurysm sac at the leak using bare platinum microcoils and hydrocoils.

aneurysms are detected in older patients with more comorbidities, it will be less desirable to treat these patients with open repair because of the risks involved. Consequently, there will be patients with less-than-optimal anatomy who will undergo endovascular repair, resulting in endoleaks that will need to be addressed with embolization techniques.

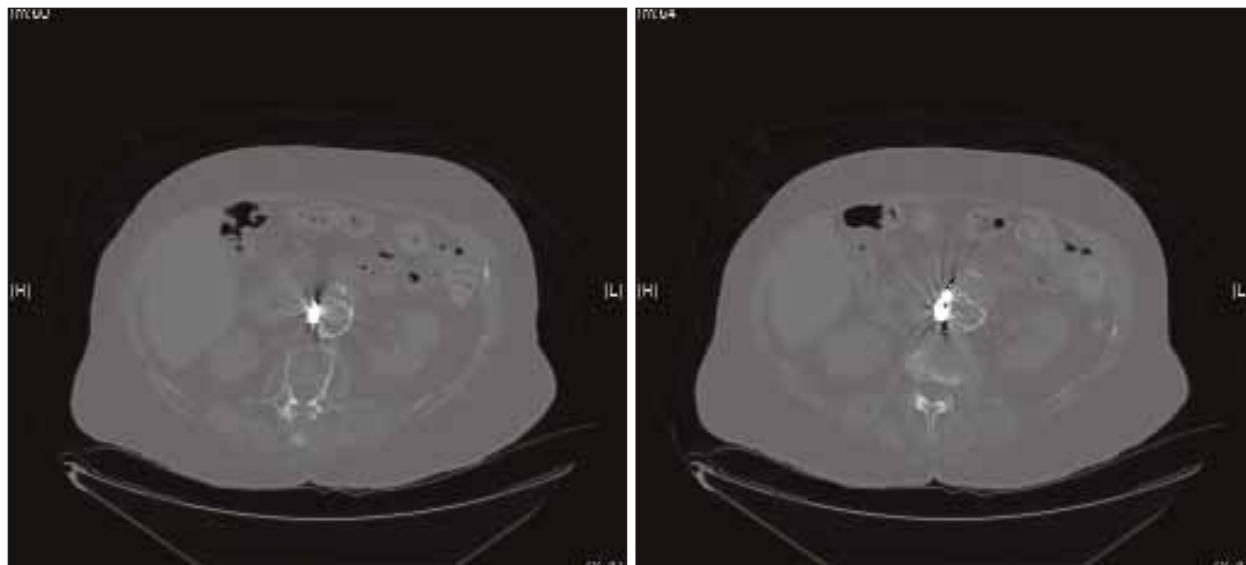
Proximal endoleak embolization with coils has been described in the literature;<sup>4</sup> however, coil embolization can be susceptible to recanalization. Proximal type I endoleaks have also been treated with n-BCA.<sup>5</sup> Solid n-BCA polymer is attractive because its increased strength, compared to

fresh thrombus, may have a greater likelihood of sealing a high-flow leak with less likelihood of recanalization. The inability to precisely control a liquid embolic agent, with embolization into systemic vessels arising from the aorta or vessels originating from the sac itself, can have devastating consequences. More recently, successful transarterial embolization of type I endoleaks has been reported using a combination of coils and liquid embolic agents designed to take advantage of both systems.<sup>6</sup>

Repair of type I endoleaks using hydrocoils has not been previously reported. The hydrocoil combines a platinum coil coated with an outer hydrogel coating. The hydrogel



**Figure 5.** A postembolization angiogram demonstrates complete exclusion of the aneurysm with resolution of the type I endoleak.



**Figure 6.** A noncontrast CT scan 24 hours after embolization demonstrates the coil mass and acrylic glue in the location of the former endoleak.

polymer expands when exposed to blood to provide improved packing density and greater mechanical stability when compared to standard platinum coils. The HEAL (HydroCoil for Endovascular Aneurysm Occlusion) study demonstrated decreased cerebral aneurysm recurrence when greater than 75% of the coil length was hydrogel-coated.<sup>7</sup> Additionally, the detachable nature allows for precise positioning, which will diminish the risk of coil migration. The density packing, precision of deployment, and ability to utilize small delivery systems are performance elements that make hydrocoils a preferred embolic agent at our institution, either alone or in combination with bare platinum coils and n-BCA.

Treatment using this technique requires direct access into the aneurysm sac. In this case, we were able to access the sac via a brachial approach by advancing a microcatheter between the sac and the stent graft. Attempts at catheterization from the femoral approach were limited due to the angle of entry into the sac. With the stability of the guiding catheter obtained through the brachial approach, embolization could be performed without complication. Although the long-term efficacy of this approach is not yet proven and lifelong monitoring is essential, embolization of a type I endoleak is an elegant solution to a challenging and potentially life-threatening clinical problem. ■

*Daniel Putterman, MD, is an interventional radiologist in the Division of Vascular and Interventional Radiology, Department of Radiology, at North Shore University Hospital in Manhasset, New York. He has disclosed that he has no financial interest in any product or manufacturer mentioned*

*herein. Dr. Putterman may be reached at (516) 562-4834; dputterman@nshs.edu.*

*Eric J. Gandras, MD, is Associate Chief of the Division of Vascular and Interventional Radiology, Department of Radiology at North Shore University Hospital in Manhasset, New York. He has disclosed that he has no financial interest in any product or manufacturer mentioned herein. Dr. Gandras may be reached at (516) 562-2979; egandras@nshs.edu.*

*Craig R. Greben, MD, is Chief of the Division of Vascular and Interventional Radiology, Department of Radiology at North Shore University Hospital in Manhasset, New York. He has disclosed that he has no financial interest in any product or manufacturer mentioned herein. Dr. Greben may be reached at (516) 562-4809; craiggreben@gmail.com.*

*Avi Setton, MD, is Chief of the Division of Neurointerventional Radiology, Department of Radiology at North Shore University Hospital in Manhasset, New York. He has disclosed that he has no financial interest in any product or manufacturer mentioned herein. Dr. Setton may be reached at (516) 562-3021; asetton@nshs.edu.*

1. White GH, Yu W, May J, et al. Endoleak as a complication of endoluminal grafting of abdominal aortic aneurysms: classification, incidence, diagnosis, and management. *J Endovasc Surg.* 1997;4:152-168.
2. Tummala S, Powell A. Imaging of endoleaks. *Tech Vasc Interv Radiol.* 2001;4:208-212.
3. Becquemin JP, Kelley L, Zubilewicz T, et al. Outcomes of secondary interventions after abdominal aortic aneurysm endovascular repair. *J Vasc Surg.* 2004;39:298-305.
4. Golzarian J, Struyven J, Abada HT, et al. Endovascular aortic stent grafts: transcatheter embolization of persistent perigraft leaks. *Radiology.* 1997;202:731-734.
5. Maldonado TS, Rosen RJ, Rockman CB, et al. Initial successful management of type I endoleak after endovascular aortic aneurysm repair with n-butyl cyanoacrylate adhesive. *J Vasc Surg.* 2003;38:664-670.
6. Peynircioglu B, Tiryakbey B, Ezkan M, et al. Use of glue and microcoils for transarterial catheter embolization of a type 1 endoleak. *Diagn Interv Radiol.* 2008;14:111-115.
7. Cloft HJ; HEAL Investigators. HydroCoil for Endovascular Aneurysm Occlusion (HEAL) study: 3-6 month angiographic follow-up results. *Am J Neuroradiol.* 2007;28:152-154.