

# Hypogastric Artery Embolization During EVAR

Using coil embolization and endovascular plug deployment to occlude the hypogastric artery.

BY BRIAN S. KNIPP, MD, AND ENRIQUE CRIADO, MD, FACS

**A** bdominal aortic aneurysms (AAAs) are a major medical problem with substantial mortality. Repair in the emergent setting is associated with very high mortality rate, and therefore, elective repair of AAA is advocated for aneurysms of sufficient size or with rapid growth. Open repair of AAAs in an elective setting still carries significant morbidity, especially in high risk patients.<sup>1</sup> Endovascular aneurysm repair (EVAR) was initially developed as an alternative treatment for AAAs in high-risk patients. During the past decade, however, the indications for EVAR have expanded to include patient preference, lower-risk patients, and those with increasingly complex anatomy. Due to its safety and efficacy with improvements in device development, streamlining of delivery systems, and the availability of long-term outcome data,<sup>2-4</sup> EVAR is arguably becoming the first-line treatment for aortic aneurysms.

One of the limiting factors of the procedure is iliac artery anatomy.<sup>5</sup> Aneurysmal involvement of the common iliac artery, or a limited landing zone proximal to the common iliac artery bifurcation, often necessitates extension of the endograft into the external iliac artery. A minimum of 10 mm is generally necessary for an adequate distal seal in the common iliac artery. Hypogastric artery interruption procedures are therefore necessary to prevent a type II endoleak in 20% to 32% of EVAR cases involving the common iliac artery.<sup>5-9</sup> A variety of procedures have been proposed for approaching situations when the hypogastric artery must be covered by

the iliac limb endograft. Surgical techniques designed to preserve hypogastric perfusion include relocation of the hypogastric artery to the ipsilateral external iliac artery directly<sup>10</sup> or via bypass graft,<sup>11</sup> femorohypogastric bypass,<sup>12</sup> external iliac-to-hypogastric stent graft placement with femorofemoral bypass and a contralateral aortouni-iliac graft,<sup>13</sup> or implanting an iliac bifurcation

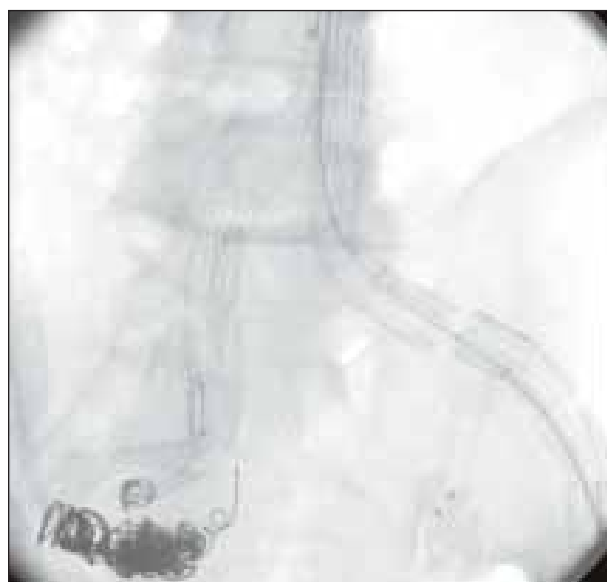
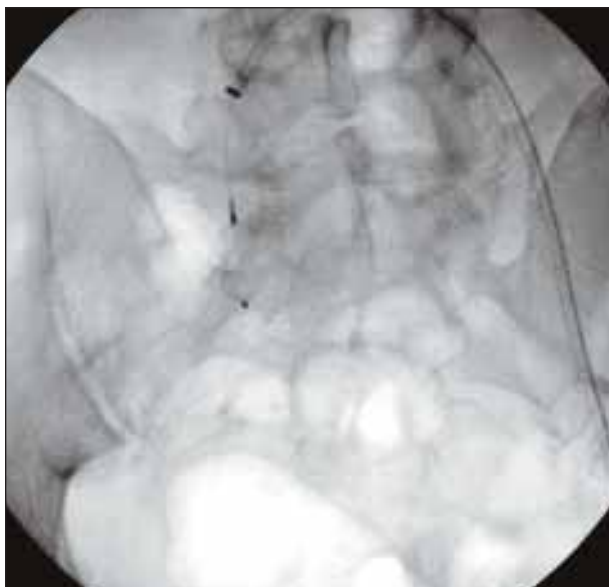

Figure 1. Deployment of numerous coils in the right hypogastric artery during EVAR. Note the number of coils necessary to embolize the vessel while the left is occluded with a single nitinol plug.



**Figure 2.** Deployment of the Amplatzer Vascular Plug ([AVP] AGA Medical Corporation, Plymouth, MN) in the right hypogastric artery using a contralateral femoral approach.

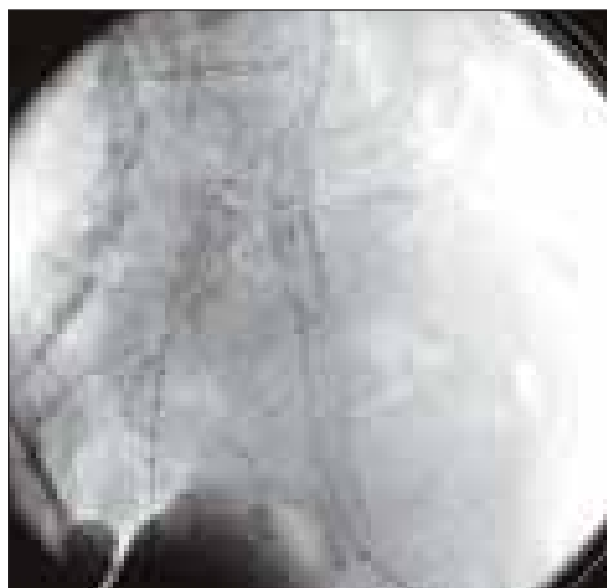stent graft in both the external iliac and hypogastric arteries.<sup>14</sup> The focus of this article, however, will be on embolization techniques for occlusion of the hypogastric artery by coil and vascular plug deployment.

## COIL EMBOLIZATION

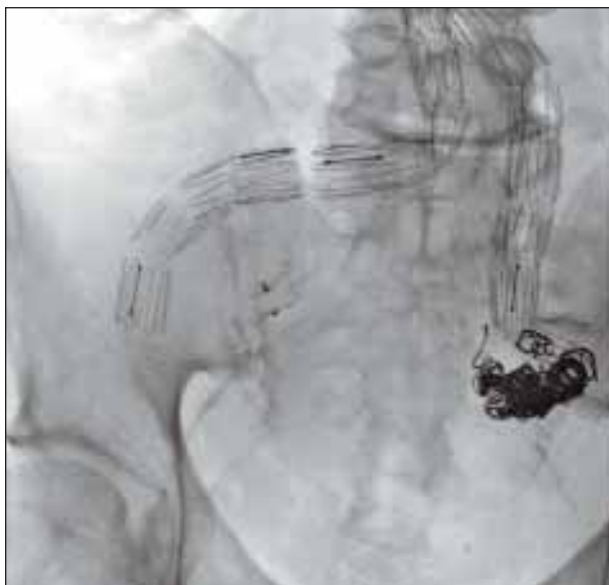The placement of aortoiliac stent grafts requires planning to prevent a variety of complications, most notably endoleaks. A type II endoleak refers to blood flowing retrograde from an artery covered by the endograft into the perigraft aneurysm sac while keeping it pressurized and potentially producing aneurysm expansion. In cases in which the ostium of the hypogastric artery is covered, the usual practice is to embolize the vessel, although there are instances when this may not be necessary.<sup>8</sup> Embolization of the hypogastric artery using coils during EVAR was first described by Parodi in one of his early publications on endovascular management of aneurysms (Figure 1).<sup>15</sup> Although this procedure can be technically challenging, initial technical success rates were approximately 95%.<sup>16</sup> However, embolization using coils can be a costly procedure. A large number of coils are usually necessary to occlude a hypogastric artery, which can lead to thousands of dollars in additional costs; one study estimated a cost of \$3,500 per occluded artery for the coils alone.<sup>2,16,17</sup>

Ischemic complications after hypogastric artery coil embolization are quite common and range in severity from mild erectile dysfunction or buttock claudication

to colonic ischemic perforation or massive gluteal necrosis. To prevent these complications, if the inferior mesenteric artery is sacrificed (as is the case with all EVAR repairs) preservation of at least one hypogastric artery should be planned as part of the procedure. Combined collateral flow from the marginal artery of Drummond to the inferior mesenteric artery and from the hypogastric arteries is crucial for colon viability. This principle, however, has been questioned in the endovascular setting. Bilateral hypogastric occlusion has been shown in some series to be safe if staged appropriately, although others have reported complications in up to 39% of patients undergoing staged hypogastric occlusion.<sup>18-20</sup> Although there are reports of mortality after hypogastric embolization,<sup>21,22</sup> buttock claudication is the most common postoperative complaint, ranging in frequency from 12% to 58% of cases.<sup>2,8,16,23-27</sup> Erectile dysfunction has also been reported in 0% to 20% of cases.<sup>2,8,23,24,26,27</sup> One of the major drawbacks of the coil embolization technique is the potential for placement or migration of coils into the distal hypogastric circulation, which has been shown to be associated with more frequent and severe symptoms.<sup>4,23,25</sup> To prevent distal embolization, a nest of larger coils is created in the main trunk of the hypogastric artery before placing smaller coils. Anatomic selection is also crucial; larger hypogastric arteries may lead to more frequent embolization of coils because the size discrepancy is larger.<sup>23</sup> Regardless of the iliac anatomy, coils are difficult to locate with



**Figure 3.** Deployment of the AVP to embolize the right hypogastric artery to permit deployment of a right iliac stent graft for exclusion of an isolated common iliac aneurysm.



**Figure 4.** Deployment of AVP in the right hypogastric artery after coiling of the left hypogastric artery. Note the difference in the number of devices used.

precision in the most proximal internal iliac artery and tend to slide downstream more often than not, occluding, in some cases, the early branches of the artery. This hinders collateral flow to the hypogastric bed and could be the reason that coil embolization may have a higher rate of ischemic complications compared with plug placement, which can be done with controlled precision.

In cases of bilateral hypogastric artery involvement, the timing of embolization is critical. Most practitioners will embolize one hypogastric artery several weeks before the EVAR procedure, allowing time for collateral flow development from the contralateral pelvic circulation. Management of the contralateral hypogastric artery is somewhat controversial. Although some interventionists will embolize the second side without a revascularization procedure, it is our practice to revascularize the contralateral hypogastric artery whenever possible (usually with a polytetrafluoroethylene graft from the external iliac artery). Failure to do so may lead to an unwarranted risk of colonic and pelvic ischemia and gluteal claudication.

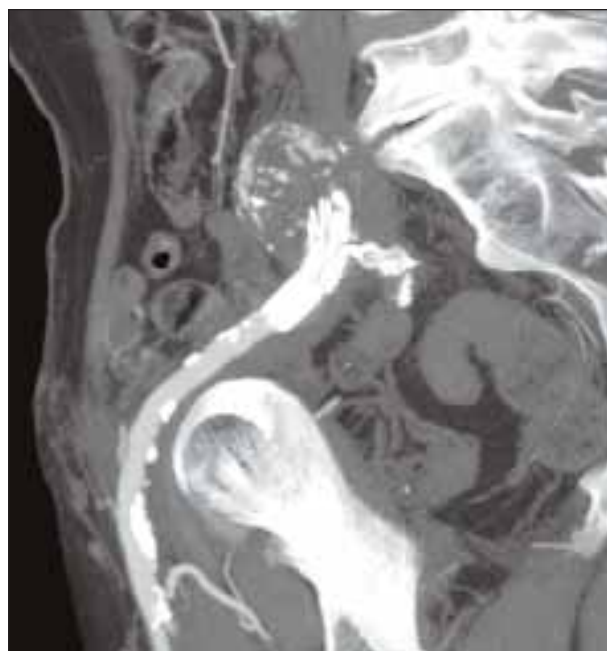
#### AMPLATZER VASCULAR PLUG

The AVP is a relatively new, magnetic resonance imaging-compatible, nitinol-based, self-expanding, cylindrical device that is made from 144 nitinol mesh wires secured on both ends with radiopaque platinum marker bands.<sup>28,29</sup> The delivery device is comprised of a stainless

steel microscrew assembly that allows deployment and resheathing of the device until correct placement is ensured; the microscrew is then released, allowing the device to be permanently implanted (Figures 2 and 3). This device is available in a wide range of sizes. The 4-, 6-, and 8-mm AVP devices are 7 mm long (unconstrained) and require a 5-F access sheath. The 10- and 12-mm plugs are 7 and 8 mm long, respectively, and require a 6-F sheath. The 14- and 16-mm devices are 8 mm long and require an 8-F sheath.<sup>2,7,28</sup>

A new version of the plug, the Amplatzer Vascular Plug II (AGA Medical Corporation), is similar in concept but has multilayered nitinol wires in three lobes. The new plug has a variety of reported applications, including occlusion of arteriovenous malformations, cranial aneurysms, arteriovenous fistulae, or branch vessel ostia in preparation for endovascular procedures.<sup>28,30,31</sup> A recent case report describes management of a common iliac aneurysm via ipsilateral hypogastric coiling, placement of proximal and distal AVPs in the common iliac artery, and a femorofemoral bypass.<sup>32</sup>

The AVP has the advantages of ease of use, good visibility under fluoroscopy, and a limited need for contrast, permitting its use intraoperatively with EVAR in more than 70% of cases in one series.<sup>26</sup> In addition, its screw-release mechanism allows the AVP to be resheathed and repositioned under fluoroscopy as many times as necessary until it is placed in its intended position. Most



**Figure 5.** Coronal reformat of a CT arteriogram involving an AVP. Note how close to the orifice the plug can be placed. There is essentially no artifact from the plug.

**TABLE 1. OUTCOMES FOR COIL EMBOLIZATION OR AMPLATZER VASCULAR PLUG (%)**

Investigator	Embolizations	Bilateral	Intraop.	Hematoma	Dsxn.	Technical Failure	ED	Buttock Claudication	Distal Embolization
<b>Coil Embolization</b>									
Ha (2005) <sup>2</sup>	10	1 (10)		0 (0)		3 (30)	0 (0)	3 (30.0)	2 (20)
Kritpracha (2003) <sup>23</sup>	20	0 (0)	11 (55)			0 (0)	1 (5)	9 (45)	1 (5)
Wolpert (2001) <sup>24</sup>	18	7 (38.9)		2 (11.1)			2 (11.1)	8 (44.4)	
Mehta (2001) <sup>27</sup>	154	20 (13)					9 (5.8)	18 (11.7)	
Cynamon (2000) <sup>25</sup>	32							13 (40.6)	
Pellerin (2008) <sup>26</sup>	6		2 (33.3)	0 (0)			0 (0)	2 (33.3)	
Vandy (2008) <sup>16</sup>	19	1 (5.3)			1 (5.3)	1 (5.3)		7 (36.8)	2 (10.5)
Farahmand (2008) <sup>8</sup>	76	3 (3.9)					15 (19.7)	44 (57.9)	
Totals <sup>a</sup>	335	32 (10.8)	13 (50)	2 (5.9)	1 (5.3)	4 (8.2)	27 (95)	104 (31)	5 (10.2)
<b>Amplatzer Plug</b>									
Ha (2005) <sup>2</sup>	5	0 (0)		1 (20)		0 (0)	0 (0)	2 (40)	0 (0)
Kickuth (2007) <sup>7</sup>	9	1 (11.1)	1 (11.1)	0 (0)	0 (0)	0 (0)	0 (0)	3 (33.3)	0 (0)
Pellerin (2008) <sup>26</sup>	7		5 (71.4)	0 (0)			0 (0)	1 (14.3)	
Resnick (2008) <sup>35</sup>	10							1 (10)	
Vandy (2008) <sup>16</sup>	23	0 (0)				0 (0)		2 (8.7)	0 (0)
Totals <sup>a</sup>	54	1 (2.7)	6 (37.5)	1 (4.8)	0 (0)	0 (0)	0 (0)	9 (16.7)	0 (0)
Abbreviations: Dsxn, arterial dissection; ED, erectile dysfunction; Intraop, embolizations performed in the same setting as EVAR as opposed to a staged procedure.									
<sup>a</sup> Includes all studies in which the outcome of interest was reported for each data element.									

hypogastric embolizations with the AVP require only a single device (Figure 4). Another advantage is the lack of artifact on computed tomography (CT), which allows CT angiograms to be more accurate in finding endoleaks or other pelvic pathology during follow-up (Figure 5).

There are no reports of initial technical failure in the literature, although there are case reports of the need for additional coils or a second device deployment.<sup>16</sup> However, spontaneous recanalization of an AVP leading to a hypogastric artery aneurysm rupture has been reported.<sup>33</sup> In general, this procedure has minimal morbidity. The potential for ischemic complications seems to be substantially lower using the AVP compared with

coiling. Buttock claudication rates are reported at 8.7% to 33.3%, and erectile dysfunction is essentially unreported (Table 1). In addition, there are no reports of distal embolization with the device.

A drawback associated with the use of AVP is the necessity for a landing zone in the hypogastric artery. Ideally, the area where it is deployed should be a short segment of medium size and relatively consistent diameter (ie, not tapered), but the AVP anchors well in arteries of almost any shape as long as its diameter is properly oversized relative to the artery. The ample range of sizes from 4- to 16-mm diameters is useful for medium- and small-sized arteries. Some authors have suggested that the inability to deploy the AVP using the over-the-wire



technique prevents application via long catheters or into tricky locations; however, this problem may apply to other remote anatomical locations but not the generally accessible hypogastric artery.<sup>7</sup> In our experience with more than 50 hypogastric artery embolizations during EVAR, we have not encountered a situation when the AVP could not be deployed via ipsilateral or, more commonly, the contralateral femoral approach.

## CONCLUSION

There is an expanding armamentarium for the vascular specialist dealing with the problematic common iliac artery. Larger distal cuff sizes and branched iliac limbs are examples of new devices that may prevent the necessity of hypogastric artery occlusion.<sup>5,34</sup> The development of more advanced branched aortic endografts will allow for management of increasingly complex arterial anatomy without the need to occlude vessels. However, until these technologies become mature, hypogastric interruption continues to be an effective and safe technique to use when necessary during EVAR. ■

*Brian S. Knipp, MD, is Senior Surgery Resident, Section of Vascular Surgery, Department of Surgery, University of Michigan, in Ann Arbor, Michigan. He has disclosed that he holds no financial interest in any product or manufacturer mentioned herein.*

*Enrique Criado, MD, FACS, is Professor of Surgery, Section of Vascular Surgery, Department of Surgery, University of Michigan, in Ann Arbor, Michigan. He has disclosed that he holds no financial interest in any product or manufacturer mentioned herein. Dr. Criado may be reached at (734) 936-0250; [ecriado@umich.edu](mailto:ecriado@umich.edu).*

1. Zarins CK, White RA, Schwarten D, et al. Aneurysm stent graft versus open surgical repair of abdominal aortic aneurysms: multicenter prospective clinical trial. *J Vasc Surg.* 1999;29:292-305; discussion 306-308.
2. Ha CD, Calcagno D. Amplatzer vascular plug to occlude the internal iliac arteries in patients undergoing aortoiliac aneurysm repair. *J Vasc Surg.* 2005;42:1058-1062.
3. Schoder M, Zaunbauer L, Hölzenbein T, et al. Internal iliac artery embolization before endovascular repair of abdominal aortic aneurysms: frequency, efficacy, and clinical results. *AJR Am J Roentgenol.* 2001;177:599-605.
4. Lee C, Dougherty M, Calligaro K. Concomitant unilateral internal iliac artery embolization and endovascular infrarenal aortic aneurysm repair. *J Vasc Surg.* 2006;43:903-907.
5. Henretta JP, Karch LA, Hodgson KJ, et al. Special iliac artery considerations during aneurysm endografting. *Am J Surg.* 1999;178:212-218.
6. Wain RA, Marin ML, Ohki T, et al. Endoleaks after endovascular graft treatment of aortic aneurysms: classification, risk factors, and outcome. *J Vasc Surg.* 1998;27:69-78; discussion 78-80.
7. Kickuth R, Dick F, Triller J, et al. Internal iliac artery embolization before endovascular repair of aortoiliac aneurysms with a nitinol vascular occlusion plug. *J Vasc Intervent Radiol.* 2007;18:1081-1087.
8. Farahmand P, Becquemin JP, Desgranges P, et al. Is hypogastric artery embolization during endovascular aortoiliac aneurysm repair (EVAR) innocuous and useful? *Eur J Vasc Endovasc Surg.* 2008;35:429-435.
9. Tefera G, Turnipseed WD, Carr SC, et al. Is coil embolization of hypogastric artery necessary during endovascular treatment of aortoiliac aneurysms? *Ann Vasc Surg.* 2004;18:143-146.

10. Parodi JC, Ferreira M. Relocation of the iliac artery bifurcation to facilitate endoluminal treatment of abdominal aortic aneurysms. *J Endovasc Surg.* 1999;6:342-347.
11. Faries PL, Morrissey N, Burks JA, et al. Internal iliac artery revascularization as an adjunct to endovascular repair of aortoiliac aneurysms. *J Vasc Surg.* 2001;34:892-899.
12. Rhee RY, Muluk SC, Tzeng E, et al. Can the internal iliac artery be safely covered during endovascular repair of abdominal aortic and iliac artery aneurysms? *Ann Vasc Surg.* 2002;16:29-36.
13. Bergamini TM, Rachel ES, Kinney EV, et al. External iliac artery-to-internal iliac artery endograft: a novel approach to preserve pelvic inflow in aortoiliac stent grafting. *J Vasc Surg.* 2002;35:120-124.
14. Brenner BJ, Faries P, Connelly T, et al. An in situ adjustable endovascular graft for the treatment of abdominal aortic aneurysms. *J Vasc Surg.* 2002;35:114-119.
15. Parodi JC. Endovascular repair of abdominal aortic aneurysms and other arterial lesions. *J Vasc Surg.* 1995;21:549-555; discussion 556-557.
16. Vandy F, Criado E, Upchurch GR Jr, et al. Transluminal hypogastric artery occlusion with an Amplatzer vascular plug during endovascular aortic aneurysm repair. *J Vasc Surg.* 2008;48:1121-1124.
17. Marty B, Perruchoud C, Wicky S, et al. Atheroembolization: a harmful complication of therapeutic internal iliac artery occlusion. *J Vasc Surg.* 2002;36:1062-1065.
18. Yano OJ, Morrissey N, Eisen L, et al. Intentional internal iliac artery occlusion to facilitate endovascular repair of aortoiliac aneurysms. *J Vasc Surg.* 2001;34:204-211.
19. Lyden SP, Sternbach Y, Waldman DL, et al. Clinical implications of internal iliac artery embolization in endovascular repair of aortoiliac aneurysms. *Ann Vasc Surg.* 2001;15:539-543.
20. Razavi MK, DeGroot M, Olcott C 3rd, et al. Internal iliac artery embolization in the stent-graft treatment of aortoiliac aneurysms: analysis of outcomes and complications. *J Vasc Intervent Radiol.* 2000;11:561-566.
21. Sandison AJ, Edmondson RA, Panayiotopoulos YP, et al. Fatal colonic ischaemia after stent graft for aortic aneurysm. *Eur J Vasc Endovasc Surg.* 1997;13:219-220.
22. Kwok PC, Chung TK, Chong LC, et al. Neurologic injury after endovascular stent-graft and bilateral internal iliac artery embolization for infrarenal abdominal aortic aneurysm. *J Vasc Intervent Radiol.* 2001;12:761-763.
23. Kritpracha B, Pigott JP, Price CI, et al. Distal internal iliac artery embolization: a procedure to avoid. *J Vasc Surg.* 2003;37:943-948.
24. Wolpert LM, Dittich KP, Hallisey MJ, et al. Hypogastric artery embolization in endovascular abdominal aortic aneurysm repair. *J Vasc Surg.* 2001;33:1193-1198.
25. Cynamon J, Lerer D, Veith FJ, et al. Hypogastric artery coil embolization prior to endoluminal repair of aneurysms and fistulas: buttock claudication, a recognized but possibly preventable complication. *J Vasc Intervent Radiol.* 2000;11:573-577.
26. Pellerin O, Caruba T, Kandounakis Y, et al. Embolization of the internal iliac artery: cost-effectiveness of two different techniques. *Cardiovasc Intervent Radiol.* 2008;31:1088-1093.
27. Mehta M, Veith FJ, Ohki T, et al. Unilateral and bilateral hypogastric artery interruption during aortoiliac aneurysm repair in 154 patients: a relatively innocuous procedure. *J Vasc Surg.* 2001;33(2 Suppl):S27-32.
28. Ratnam LA, Walkden RM, Munneke GJ, et al. The Amplatzer vascular plug for large vessel occlusion in the endovascular management of aneurysms. *Eur Radiol.* 2008;18:2006-2012.
29. White HA, Travis SJ. The Amplatzer vascular plug. *Cardiovasc Intervent Radiol.* 2008;31:448-449.
30. Chaudhuri A, Tibballs J, Nadkarni S, et al. Digital embolization due to partially uncovered left subclavian artery post TEVAR: management with amplatzer vascular plug occlusion. *J Endovasc Ther.* 2007;14:257-259.
31. Tuite DJ, Kessel DO, Nicholson AA, et al. Initial clinical experience using the Amplatzer Vascular Plug. *Cardiovasc Intervent Radiol.* 2007;30:650-654.
32. Coupe NJ, Ling L, Cowling MG, et al. Treatment of a common iliac aneurysm by endovascular exclusion using the Amplatzer vascular plug and Femorofemoral Crossover Graft. *Cardiovasc Intervent Radiol.* In press.
33. Dorenberg EJ, Hatsahl G, Andersen R, et al. Recurrent rupture of a hypogastric aneurysm caused by spontaneous recanalization of an Amplatzer vascular plug. *J Vasc Intervent Radiol.* 2006;17:1037-1041.
34. Kritpracha B, Pigott JP, Russell TE, et al. Bell-bottom aortoiliac endografts: an alternative that preserves pelvic blood flow. *J Vasc Surg.* 2002;35:874-881.
35. Resnick S, Eskandari M. Outcomes of Amplatzer Vascular Plugs for occlusion of internal iliacs during aortoiliac aneurysm stent grafting. *Ann Vasc Surg.* 2008;22:613-617.