

# Do We Really Need a New Varicose Vein Technique?

A hybrid embolization technique involving occlusion coils and alcohol sclerosis.

BY MICHEL K. BARSOUM, MB, CHB; THOM W. ROOKE, MD; AND HARALDUR BJARNASON, MD

Interest in minimally invasive therapies for varicose veins is increasing, especially for incompetence at the saphenofemoral junction. There are currently several such techniques from which to choose. Ligation of the saphenous vein at the saphenofemoral junction has been advocated, but unfortunately, gravitational reflux and hydrostatic forces are not well controlled using this procedure.<sup>1</sup> Sclerotherapy (foam or liquid) is another approach, but it often fails in the presence of saphenofemoral reflux.<sup>2</sup> Radiofrequency and laser ablation, two popular new procedures, are not entirely without shortcomings because they may produce skin burns or cause thrombosis, which may propagate into the deep venous system and put the patient at increased risk for pulmonary embolism. Variable incidence of deep venous thrombosis has been reported.<sup>3-5</sup> Stripping of the great saphenous vein, a procedure still widely performed, requires approximately 2 weeks of restriction from work and driving. Even the less-invasive options, such as laser or radiofrequency ablation techniques, may require 3 days before normal activity can be resumed. Moreover, ambulatory phlebectomy and laser or radiofrequency ablation often use large volumes of tumescent anesthesia, and also this thermal injury may cause pain and skin damage with inflammation.

## AN OLD IDEA

For many decades, percutaneous coil occlusion and alcohol ablation have been used to treat incompetent spermatic and ovarian veins, bleeding varices, and venous malformations. We have treated several patients with saphenous vein incompetence using coil embolization and

alcohol ablation in the past. Accordingly, we have performed a retrospective study to estimate the safety and efficacy of this approach for treating greater saphenous vein (GSV) varicosities, especially those with incompetence of the saphenofemoral junction.

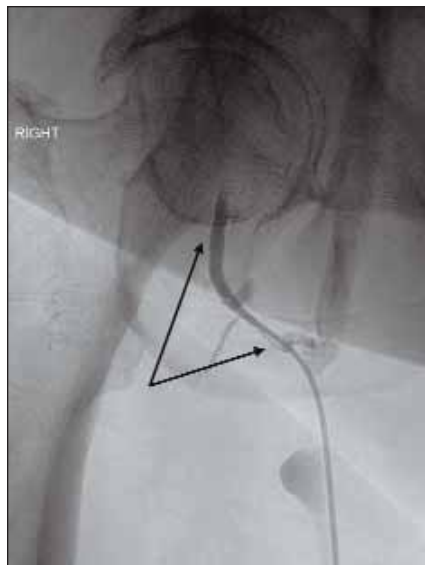
## THE COIL AND ALCOHOL ABLATION TECHNIQUE

All of the procedures were performed in the interventional radiology catheterization suites at our two interventional sites. The procedure is performed using local anesthesia with intravenous sedation. After ultrasound-guided puncture of the saphenous vein in the lower leg (Figure 1), an introducer sheath is placed. A 5-F angiographic catheter is then placed into one of the small tributaries of the saphenous vein proximally, via the superficial epigastric vein, for example (Figure 2).


An embolization coil (Nester Embolization Coil, Cook Medical, Bloomington, IN) is then placed into the tributary for anchoring and then curled up in the GSV. On average, two additional coils are then placed adjacent to this coil or until complete occlusion of the saphenous vein has been obtained (Figure 3). This is done using fluoroscopic guidance. Subsequently, 5 to 10 mL of absolute alcohol is injected into the vein peripheral to the coils as the catheter is pulled to the introducer sheath. The patient is then instructed to wear a full-length compression stocking (30 to 40 mm Hg) for 3 days and nights and then for 5 weeks during the day. When indicated, bilateral procedures can be done in the same sitting, and the patients can resume their normal

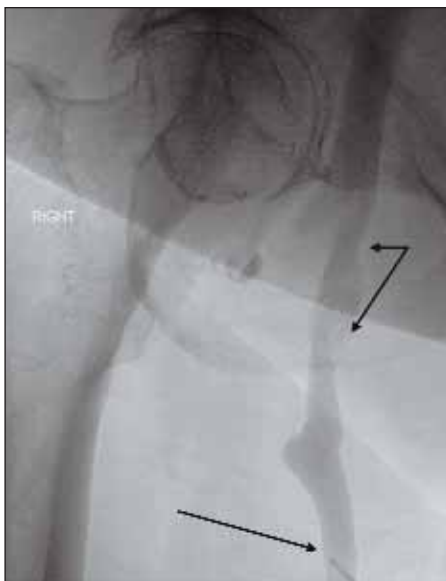

Figure 1. The 5-F catheter (arrow) has been brought into the proximal GSV, and a venogram depicts the saphenofemoral junction (split arrow).



**Figure 2.** The 5-F catheter has now been brought into the superficial epigastric vein (split arrow), verified by contrast injection.



**Figure 3.** Three coils have now been placed into the GSV. The first coil was anchored into a tributary to reduce the risk of dislodgement.

daily routines on the following day. Most patients require additional local sclerotherapy for smaller varicosities. This is usually performed 5 to 6 weeks after the procedure.

### Analyses

Wilcoxon signed-rank test was used to determine if the posttreatment venous return rate differed significantly from baseline. Due to potential correlation, if both legs were treated, only one leg chosen at random was included in the analysis. Statistical significance was considered to be  $P < .05$ .

### Results

We treated 125 patients (161 legs) with 36 bilateral procedures. Technical success (100%) was defined as successful occlusion of the GSV with coils and injection of alcohol.

Strain-gauge plethysmography was performed on 93 patients (121 legs) before the procedure and on 50 patients (69 legs) after the procedure. Forty-five of the 50 patients had pre- and posttreatment strain-gauge plethysmography. The baseline median venous refill rate was 10.2 mL/100 mL tissue per minute with a mean of  $12.2 \pm 8.8$  mL/100 mL tissue per minute (normal  $< 5$ ). After the procedure, the median venous refill rate was 5.5 mL/100 mL tissue per minute with a median change in venous refill rate of  $-6$  mL/100 mL tissue per minute with a mean of  $-7.7 \pm 8.9$  mL/100 mL tissue per minute (95% CI,  $-5$ – $-10.4$ ;  $P \leq .001$ ). Posttreatment venous refill rates were significantly improved compared to the preprocedural values.

Duplex ultrasonography was performed on 123 patients on 160 legs before the procedure and in 79 patients on 106 legs after it. Based on the ultrasonography, the mean saphenofemoral junction diameter was  $1.1 \pm 0.3$  cm. Based on Duplex ultrasonography of 106 legs, the GSV remained occluded in 77 legs; minimal recanalization was noted in six legs.

Before coil embolization of the 161 legs, pain with edema was reported in 36 legs, pain without edema in 28 legs, edema alone in three legs, skin changes/dyscoloration in 13 legs, ulcer in three legs, and cosmetic dissatisfaction in three legs. After coil embolization with alcohol sclerotherapy, symptoms resolved completely in 62 legs and partially resolved in

three legs (one patient was lost to follow-up). The three venous ulcers healed, and leg edema was resolved in all cases.

### Complications

One patient had one small nonocclusive deep venous thrombosis and was kept on anticoagulation for 3 months. There were three episodes of coil displacement. All episodes occurred early in our experience, before starting to anchor the first coil into a tributary vein. One of the patients had transient fever and myalgia immediately after the procedure. Symptomatic superficial vein thrombosis was noticed in two of the patients. There were no episodes of pulmonary embolism and no deaths.

### ADVANTAGES

There were no cases of pulmonary embolism in this series. We did not search for thrombi at 1 to 2 weeks after the procedure. There were no cases of infection or ulceration as reported with vein stripping. Coils and alcohol ablation required small volumes of local anesthetic. In comparison, classic vein stripping often requires general anesthesia and ambulatory phlebectomy, and laser or radiofrequency ablation typically use large volumes of tumescent anesthesia. In all cases, our patients were dismissed home 4 hours after the procedure and were able to return to work the next day. In contrast, vein stripping and laser or radiofrequency ablation often require more time off from work.

### Limitations

Fluoroscopy has been utilized in this technique. It is essential that the interventionist is familiar with coils and catheters to perform coil embolization and alcohol ablation, and a skilled staff and access to these sets of equipment are mandatory.

### FUTURE ASPECTS

Increased use of ultrasound, even in obese patients, may be possible. Other sclerosing agents besides alcohol might be substituted. Head-to-head studies using hybrid techniques versus radiofrequency or laser ablation could be undertaken to assess the relative recurrence of symptoms, costs, and the rate of complications seen with each of these procedures.

### CONCLUSION

Percutaneous coil occlusion and alcohol ablation is an effective and safe treatment for symptomatic GSV varicosity with or without saphenofemoral junction incompetence. ■

*Michel K. Barsoum, MB, ChB, is from the Division of Cardiovascular Diseases, Section of Vascular Diseases at the Mayo Clinic College of Medicine, in Rochester, Minnesota. He*

*has disclosed that he holds no financial interest in any product or manufacturer mentioned herein. Dr. Barsoum may be reached at [barsoum.michel@mayo.edu](mailto:barsoum.michel@mayo.edu).*

*Thom W. Rooke, MD, is from the Division of Cardiovascular Diseases, Section of Vascular Diseases at the Mayo Clinic College of Medicine, in Rochester, Minnesota. He has disclosed that he holds no financial interest in any product or manufacturer mentioned herein. Dr. Rooke may be reached at [rooke.thom@mayo.edu](mailto:rooke.thom@mayo.edu).*

*Haraldur Bjarnason, MD, is with the Section of Interventional Radiology, Department of Radiology, Mayo School of Graduate Medical Education, College of Medicine, Mayo Clinic, in Rochester, Minnesota. He has disclosed that he holds no financial interest in any product or manufacturer mentioned herein. Dr. Bjarnason may be reached at (507) 255-8454; [bjarnason.haraldur@mayo.edu](mailto:bjarnason.haraldur@mayo.edu).*

1. McMullin GM, Coleridge Smith PD, Scurr JH. Objective assessment of high ligation without stripping the long saphenous vein. *Br J Surg*. 1991;78:1139-1142.
2. Bergan JJ. Surgical management of primary and recurrent varicose veins. In: Gloviczki P, Yao JST, eds. *Handbook of Venous Disorders*. Andover, UK: Chapman & Hall; 1996:399.
3. Hingorani A, Ascher E, Markevich N, et al. Deep venous thrombosis after radiofrequency ablation of greater saphenous vein: a word of caution. *J Vasc Surg*. 2004;40:500-504.
4. Lurie F, Creton D, Eklof B, et al. Prospective randomized study of endovenous radiofrequency obliteration (closure procedure) versus ligation and stripping in a selected patient population (EVOLVeS Study). *J Vasc Surg*. 2003;38:207-214.
5. Merchant RF, DePalma RG, Kabnick LS. Endovascular obliteration of saphenous reflux a multicenter study. *J Vasc Surg*. 2002;35:1190-1196.

## COMMENTARY

### By José I. Almeida, MD

As a vascular surgeon with a busy 100% office-based venous practice, I wanted to comment on the technique and data described in this article. The authors ask a question in the title: Do we really need a new technique? My response is that new techniques are useful only when they offer improvements over existing techniques. Dr. Barsoum and coauthors describe a hybrid embolization technique involving occlusion coils and alcohol sclerosis as an alternative treatment for great saphenous vein (GSV) reflux disease. This GSV embolization procedure was performed on 161 legs in a hospital catheterization laboratory, and then the patients were studied with plethysmography and duplex imaging. Most patients benefited; however, successful GSV occlusion was noted in only 73% of limbs, and the authors made no mention of follow-up intervals. The details are provided in their monograph.

Patients who undergo the procedure described in this article are subjected to ionizing radiation and injected with a potentially nephrotoxic contrast agent. Expensive foreign bodies (coils) are placed in the GSV permanently. Three coils dislodged in their series. Alcohol injection is then performed using an agent known for its potential to cause skin ulcerations. The technique described by Barsoum et al is not approved by the FDA for saphenous reflux. Patients require 4 hours of recovery time before discharge, and then they wear compression hose for 5 weeks thereafter. Many patients require additional visits for sclerotherapy to treat remaining varicose veins.

On balance, GSV thermal ablation with radiofrequency or lasers in combination with microphlebectomy offers the patient a rapid, office-based procedure performed entirely with ultrasound under local anesthesia. This FDA-approved procedure leaves no foreign body and requires no ionizing radiation or contrast. The procedure is covered by insurance when billed using standard CPT codes. Patients are in and out of the office in 1 hour, including recovery. They return to work on the same day and wear compression hose for only 2 weeks. Their varicose veins are absent after the treatment, with no need for additional therapy. Extensive literature reports successful ablation in 98% of cases, with deep vein thrombosis seen in 1% in contemporary studies. This has been our experience over the past 7 years in more than 3,000 cases treated.

I commend the authors for their genuine interest in lower extremity venous disease, and I congratulate them for their creative, minimally invasive approach. However, with all due respect, I will not be offering their procedure to any of my patients. ■