

# The Contemporary CLI Toolbox

A close look at the available devices and techniques for treating today's critical limb ischemia patients.

BY DAVID E. ALLIE, MD; RAGHOTHAM R. PATLOLA, MD; AGOSTINO INGRALDI, MD;  
CHRIS J. HEBERT, RT(R), RCIS; AND CRAIG M. WALKER, MD

Critical limb ischemia (CLI) or end-stage lower extremity ischemia continues to be a huge global, clinical, and economic burden with >220,000 to 240,000 amputations performed yearly in the US and Europe.<sup>1,2</sup> These reports of CLI burden may even be underestimated.<sup>3</sup> Fundamental steps to improve CLI outcomes include improved global awareness, multidisciplinary education, and potentially a more refined, contemporary endovascular strategy committed to treating CLI in a similar fashion as the interventional cardiologist treats coronary artery disease or at least similar to the left anterior descending (LAD) artery. In that spirit, at the 4th International Multidisciplinary CLI Summit held September 11, 2008, at the 9th Annual New Cardiovascular Conference in New Orleans, a highly successful session entitled *Treating the Infrapopliteals Like the LAD* was created. This forum was created in order to advocate a more contemporary peripheral vascular interventional (PVI) approach to treating CLI. We have developed new strategies to treat CLI, facilitated by our ever-expanding CLI toolbox.

An integral part of any change in CLI treatment strategies is the development of new PVI tools dedicated to treating all infrainguinal arteries, including the infrapopliteals. Since the turn of the 21st century, our interventional CLI toolbox has steadily grown. This article reviews today's interventional devices, as well as several key noninterventional options within the CLI toolbox that have a potential to improve our patients' CLI clinical outcomes (Figure 1).

## DIAGNOSIS

The podiatrist, wound care specialist, or referring primary care physician most often makes the clinical diagnosis of CLI due to a poorly healing wound. It is incum-

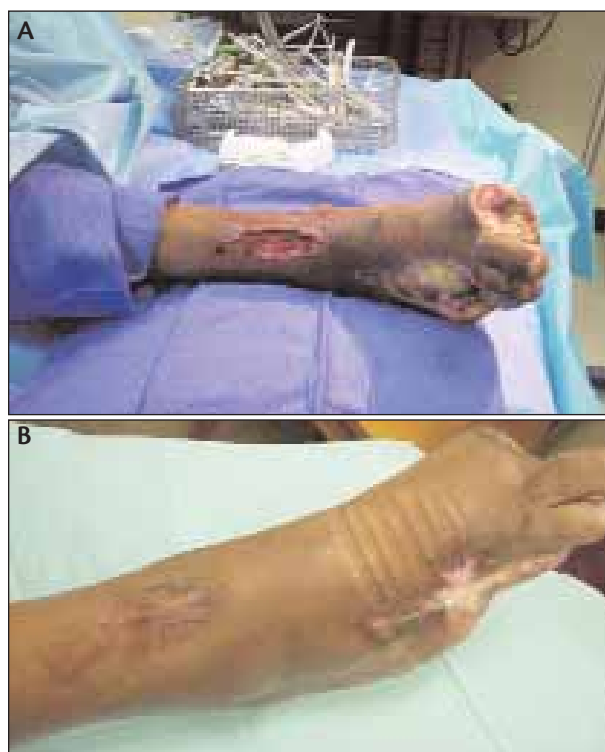

Figure 1. Rutherford class >6 scheduled for amputation after multiple failed surgical and nonsurgical attempts (A). Results 2 months after successful infrapopliteal laser/PTA, bioengineered skin substitutes, hyperbaric oxygen therapy, and maximal medical therapy for microcirculatory dysfunction (B). The multidisciplinary referrals and communication among podiatry, orthopedic, diabetes, plastic surgery, nursing, nutritional, and wound care specialists are additional integral components of the limb salvage toolbox are not comprehensively reviewed in this article but hopefully will be covered in future issues.

bent upon us as vascular interventionists and/or endovascular surgeons, and as a larger health care community, to continue to enhance awareness and education regarding new revascularization tools and to optimize referrals for revascularization rather than primary amputations in the majority of CLI patients.<sup>4</sup> It has been well established that if a wound does not heal by 20% to 25% in 4 weeks that it has a high likelihood of vascular insufficiency, and those patients should be referred to a vascular specialist.<sup>5</sup> However, adherence to this standard remains poor. More aggressive noninvasive vascular testing in wound care centers, podiatry offices, and primary care offices would likely result in improved outcomes.

There are now several ankle-brachial index (ABI) or ABI-like evaluation systems available, with specific programs designed to place these units in wound care clinics, podiatry offices, and primary care offices to enhance vascular education and referrals. Examples of noninvasive vascular testing CLI tools include the Revo 1100 by Unetix, Inc. (North Kingston, RI), the PADnet System by BioMedix Vascular Solutions (St. Paul, MN), and the SensiLase System by väsamed, Inc. (Eden Prairie, MN). The SensiLase System is a laser Doppler examination combining skin perfusion pressure and pulse volume recording to assess wound healing and capillary circulation for predicting the level of amputation. The OxyVu (Hypermed, Inc., Waltham, MA), a camera-based diagnostic tool that quantifies hyperspectral tissue oxygenation in diabetic foot ulcers, has the potential to objectively assess pedal microcirculatory disease and function.

After the clinical diagnosis has been confirmed by ABI and/or duplex ultrasound, we have found multichannel computed tomography angiography (CTA) to be extremely helpful in the overall management of CLI.<sup>6,7</sup> In addition to an extremely accurate diagnosis, an abdominal CTA with runoff has provided the following clinical management benefits: identification of optimal vascular access site, vessel sizing, lesion morphology (presence of calcium, thrombus, plaque, dissections, etc.), previously placed stents, stent fractures, chronic total occlusions (CTOs), vascular tortuosity, renal artery stenosis, and aneurysmal disease. Therefore, CTA has the potential to facilitate the definitive PVI approach by decreasing total procedure time, radiation and contrast exposure, and optimizing periprocedural decision making through preprocedural planning of almost every aspect of the case including choosing the CLI tools and PVI strategies to be used. Ultimately, CTA can lead to improved overall outcomes in CLI patients who are inherently at risk for peri- and postprocedural complications, including vascular access management complications, contrast-induced nephropathy, and early PVI failure.

## MEDICAL THERAPY

Although the mainstay of treating CLI is revascularization, there is likely an unappreciated and important role for both pre- and postrevascularization medical therapy focused on optimizing antiplatelet therapy, statin therapy, microcirculatory dysfunction, and wound healing. The role of medical therapy in CLI was addressed by an expert panel of multidisciplinary physicians during the 4th Annual CLI Summit. The panel discussed many of the available options, including the following:

- (1) Clopidogrel 75 mg and aspirin 81 to 325 mg per day for maximum platelet inhibition for at least 3 months if tolerated, but most CLI patients will likely benefit from dual therapy for life.
- (2) Daily statin therapy regardless of the cholesterol level. This recommendation was based on recent evidence that statins have overall cardiovascular benefits despite a normal cholesterol level with possible mechanisms of action being anti-inflammatory, vasodilation, and improved microcirculatory function.
- (3) Amlodipine besylate 5 mg per day for vasodilation and microcirculatory function maintenance.
- (4) Cilostazol 50 to 100 mg twice per day in patients with ejection fraction >40% and no history of congestive heart failure, for potential antirestenosis benefits and improved microcirculatory function.
- (5) Metanx (PamLab, LLC, Covington, LA) one tablet twice per day. This vitamin consists of high-dose, rapidly absorbable B<sub>12</sub>, B<sub>6</sub>, and folic acid, which appears to improve wound healing and neurovascular function in patients with diabetic neuropathy and CLI. The proposed mechanisms of action include a decrease in serum homocysteine levels with a resultant increase in nitric oxide with improved microcirculatory function.<sup>8-10</sup> More clinical data are needed, however.
- (6) Vitamin C 500 mg twice per day and multivitamins with zinc to improve wound healing. Again, no data are yet available.
- (7) Strict diabetes control was recommended.

## BALLOON AND SPECIALTY BALLOONS

Plain old balloon angioplasty still remains inferior to percutaneous transluminal angioplasty (PTA) plus stenting in most superficial femoral artery (SFA) lesions, but Cordis Corporation (Warren, NJ) has developed a new 5- and 6-mm 220-mm-long balloon that facilitates CLI cases with long lesions or in-stent restenosis requiring PTA. The newer-generation dedicated tibial balloons have smaller profiles, thinner walls, longer shafts, higher strengths, lower pressures, hydrophilic coatings, tapering tips, and

come in diameters as small as 1.5 mm and lengths of 12 cm. The Amphirion (Invatec S.p.A., Roncadelle, Italy) and Savvy Long balloon (Cordis Corporation) are two examples of the new generation of dedicated tibial balloons. It was only 3 to 4 years ago that we would do almost anything to avoid tibial PTA and its inevitable dissections, but today we have lowered our threshold for this procedure. In addition, we now advocate longer (3–5 minute) low-pressure inflations.

The Cutting Balloon (Boston Scientific Corporation, Natick, MA) is an option in SFAs and tibial vessels, especially in more discrete calcified lesions. The novel AngioSculpt Scoring Balloon (AngioScore Inc., Fremont, CA) is a similar technology with a spiral, multiple-wire nitinol cage surrounding a semicompliant balloon that was recently approved and is available for treating SFA and tibial disease. The AngioSculpt is available in diameters from 2 to 5 mm with lengths of 20 to 40 mm, making it a useful tool in treating more localized lower extremity disease and especially anastomotic lesions in bypass grafts. The PolarCath cryoplasty balloon (Boston Scientific Corporation) is available in sizes from 2 to 6 mm, in lengths from 20 to 100 mm, and we continue to find uses in recurrent lesions in areas where stents are prone to complications, such as the popliteal or common femoral artery.

The VasculTrak 2 (IDev Technologies, Inc., Houston, TX) balloon is a recently commercially available specialty PTA system offered in diameters from 2 to 6 mm with lengths from 20 to 200 mm, making it extremely useful in a wide variety of both discrete and diffuse SFA, popliteal, and infrapopliteal lesions. The VasculTrak 2 is highly trackable and easily deliverable. This balloon is delivered by two wires along the longitudinal axis, which allows for maximal focal pressure PTA. Slower balloon inflations are advocated to allow for focal pressure PTA, which in concept may decrease the incidence and severity of intimal hyperplasia. Our initial results have been excellent, especially in delivering this long catheter-based technology into the infrapopliteal vessels down to the ankle, which will allow a single inflation to cover the entire infrapopliteal and occasionally the popliteal artery. We have recently reported our results of utilizing the VasculTrak 2 in infrapopliteal disease with a 100% delivery rate with only 20% requiring adjunct therapy (stenting) (Figure 2).<sup>11</sup>

Drug-eluting balloons are not currently available in the US but have achieved CE Mark approval in Europe. The European-based THUNDER trial has been published, comparing a paclitaxel-coated balloon to PTA.<sup>12</sup> Encouraging results were reported, and a similar balloon should be available in the US within the next 12 to 18

months. Balloon-based technology combined with radiofrequency and thermal energy is being developed by Minnow Medical (San Diego, CA). This device will deliver a series of radiofrequency microfilaments arranged on the balloon that can be individually calibrated and controlled. This would potentially afford highly selective delivery of radiofrequency thermal energy within the target vessel in hopes to deliver positive plaque modification and improve nonstent results.

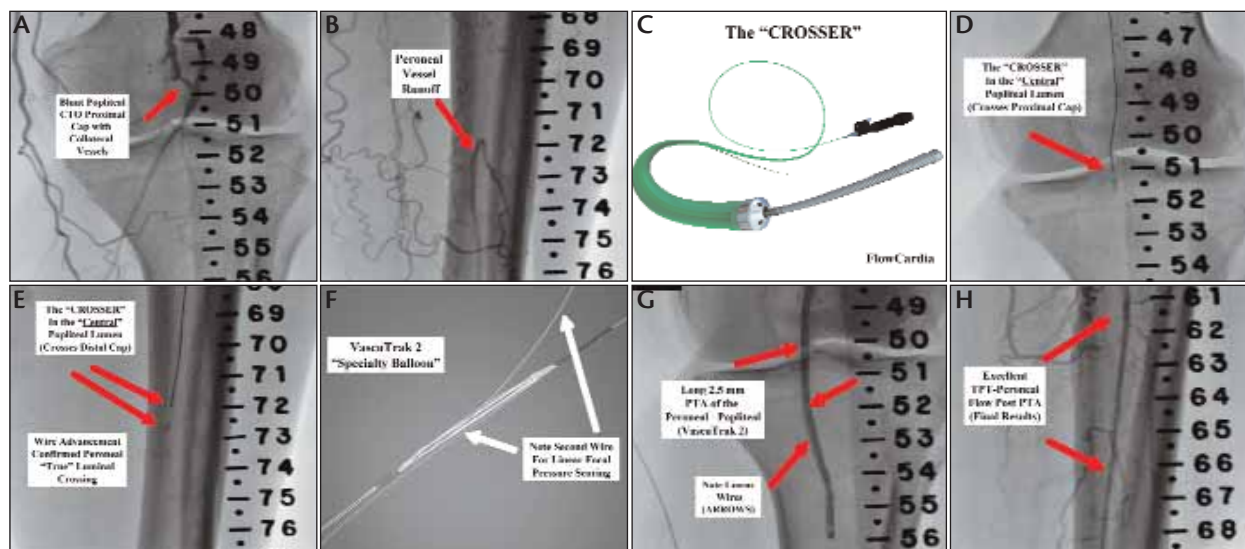
## ATHERECTOMY

Pulsed excimer laser offers the unique ability to deliver thrombus and atheroablative atherectomy. The 308-nm cool Excimer laser catheter (Spectranetics Corporation, Colorado Springs, CO) delivers intense, controllable ultraviolet energy in extremely short, pulsed durations, ablating tissue with reduced thermal injury and reduced potential for distal embolic complications. The catheter diameter sizes range from 0.9 to 2.5 mm, making this technology especially applicable to infrapopliteal vessels and even pedal vessels in the foot. The recent Turbo laser design (Spectranetics Corporation) has added 20% to 30% more optical fibers and energy with a continuous-on mode, which enhances the efficacy and ease of use.

In a CLI patient population with sparse published data, the landmark LACI trial enrolled 155 CLI patients with 423 lesions in 15 US and German sites.<sup>12</sup> The 6-month LACI results included a 93% limb salvage rate with overall low periprocedural complications and a 6-month reintervention rate of 16% with only 2% requiring bypass surgery. The LACI trial clearly demonstrated that endovascular interventions in CLI could achieve high limb salvage rates (93%) in fragile and complex CLI patients with low complications who had no other surgical options.<sup>13</sup>

The Diamondback 360° Orbital Atherectomy System (OAS) (Cardiovascular Systems, Inc., St. Paul, MN) is a diamond-coated atherectomy device capable of achieving up to two-times luminal gain, with crowns from 1.25 to 2.5 mm in diameter. The orbital design will often allow one crown size to treat vessels of different sizes, affording cost containment. Animal and bench studies have shown that the average size of the atherectomy-generated particles is 2  $\mu$ m in diameter and is therefore capable of removal through the normal reticuloendothelial system. The US pivotal trial reported a low rate of major adverse events at 30 days (3.2%), no major amputations at 6 months, and a low complication rate, including a <1% distal embolization rate. We have found the Diamondback 360° particularly helpful in debulking the highly calcified and recalcitrant tibial lesions that are very common in elderly diabetic CLI patients (Figure 3).

Vascular calcification continues to be one of the



**Figure 2.** A CLI patient with popliteal and infrapopliteal CTOs. Note the massive collaterals and blunt popliteal CTO cap with immediate collateral vessel (A). Massive collaterals fill a small, single peroneal vessel runoff to the foot (B). The Crosser device (FlowCardia, Inc., Sunnyvale, CA) (C). The proximal cap was crossed by the device in 20 seconds (D). The Crosser device was advanced through the central vessel lumen, and the wire advanced out of the device, confirming true peroneal luminal location (E). A long 2.5- X 120-mm VascuTrak 2 focal pressure scoring balloon PTA for 3 minutes was performed (F, G). Excellent results after popliteal PTA (4- X 60-mm VascuTrak 2) and peroneal PTA showing several novel contemporary interventional tools facilitating limb salvage revascularization (H).

Achilles' heels in the endovascular management of the CLI patient. A recent report from the Cleveland Clinic states that 51 patients undergoing major lower limb amputation identified severe tibial vessel calcifications of 70% of all tibial arteries and only 30% of the more proximal popliteal or SFA.<sup>14</sup> Interestingly, clinical factors such as diabetes, hyperlipidemia, and renal disease were not associated with heavy calcification, but smoking was identified as a risk factor; therefore, it appears distal vessel calcifications are extremely common and the rule, not the exception, in treating CLI. This underscores the potential benefits of the Diamondback 360° because it is a tool designed specifically for use in calcified vessels.

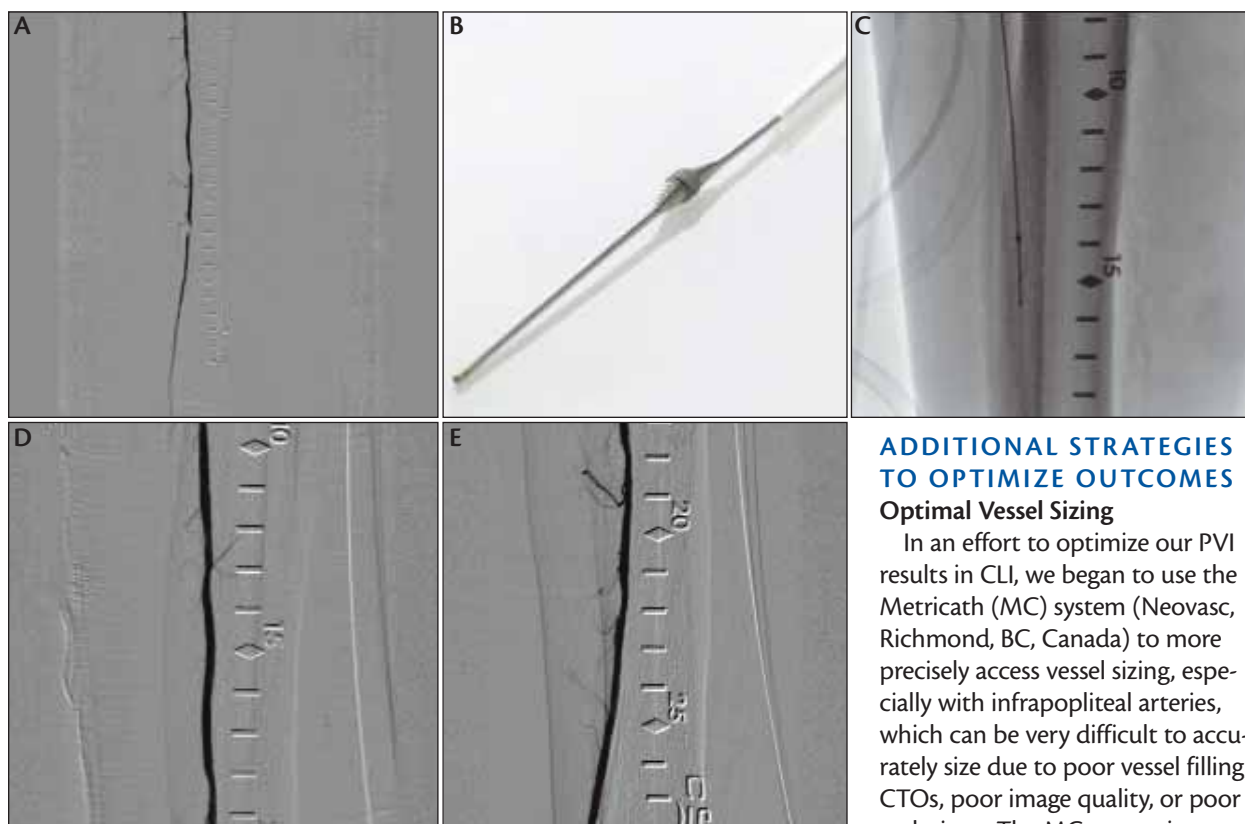
The SilverHawk (ev3 Inc., Plymouth, MN) is a mono-rail catheter with a carbide cutting blade system (8,000 rpm) that excises atherosclerotic plaque, which is collected in a nose cone for removal. The recently introduced SilverHawk DS, or MiniHawk, has a lower-profile design, allowing treatment in smaller infrapopliteal and pedal vessels (as small as 1.5 mm in diameter). The RockHawk has a plaque excision design allowing utilization in calcified lesions. Pathway Medical Technologies, Inc. (Kirkland, WA) recently released their atherectomy device, the Jetstream catheter, which provides simultaneous atherectomy with aspiration to remove thrombotic, atherosclerotic, and atherectomized debris. Atherectomy is accomplished using a unique propri-

etary device tip with small cutting blades, and the Jetstream device has recently received a thrombectomy indication. There has been limited US experience with this device at this time, but promising results have been reported from Europe.

## STENTING IN CLI

Dr. Krishna Rocha-Singh discusses below-the-knee stenting in another article in this issue of *Endovascular Today* (page 57), but infrapopliteal stenting has become more prevalent in our CLI patient population. Several years ago, our standard treatment would have been laser atherectomy followed by PTA. We would have spent a significant amount of time trying to "tack up" a dissection with PTA. Today, we freely stent these areas of dissection that have improved our CLI results. There has been a shift in attitude regarding infrapopliteal stent usage, especially in patients with CLI. We still try to avoid infrapopliteal stenting if possible, but if dissection or less-than-optimal flow occurs, we have lowered our threshold for placing bare-metal stents, a drug-eluting coronary stent (DES), or a small-diameter nitinol stent (Xpert, Abbott Vascular, Santa Clara, CA). There are supportive data regarding each of these therapies, and the below-the-knee trial results with the Xpert stent are nearing completion. Use of coronary DES below the knee remains controversial, but European and US data have consistent-





**Figure 3.** CLI patient with three significant posterior tibial lesions at 12, 19, and 22 cm (A). The Diamondback 360° OAS 1.75-mm Classic Crown (B, C) was run for 5 minutes 45 seconds. Final stand-alone results after orbital atherectomy (D, E).

### ADDITIONAL STRATEGIES TO OPTIMIZE OUTCOMES

#### Optimal Vessel Sizing

In an effort to optimize our PVI results in CLI, we began to use the Metricath (MC) system (Neovasc, Richmond, BC, Canada) to more precisely assess vessel sizing, especially with infrapopliteal arteries, which can be very difficult to accurately size due to poor vessel filling, CTOs, poor image quality, or poor technique. The MC system is a novel system consisting of a low-pressure 1.8- to 4-mm-diameter balloon catheter and an external computerized console that calcu-

ly shown better acute and long-term results using DES versus bare-metal stents in treating the infrapopliteal arteries.<sup>15-18</sup>

The most recent advancement in nitinol-based, self-expanding, peripheral stent technology applicable to CLI patients has been the development of the Supera stent by IDEV Technologies. Advantages of the interwoven wire nitinol Supera include longer stent lengths >200 mm, potential for a tapered stent design, and a wide range of stent diameters as small as 2 to 2.5 mm. Currently, the Supera is available in 3- to 6-mm diameters, which makes it very useful in CLI patients requiring stenting of the proximal infrapopliteal arteries distally that require the stents to extend proximally back to and across the popliteal artery and even into the SFA. A potential disadvantage of the first-generation delivery system is that it is different from older devices and requires a short learning curve. Excellent results have been obtained in Europe, where approximately 18 months of experience have been reported.<sup>19,20</sup> We have had a similar 6-month experience with no stent fractures or kinking observed and a >90% patency rate.

lates vessel luminal diameters and cross-sectional areas to the hundredth of a millimeter. The balloon is advanced to the target site over either a .014- or .018-inch wire using standard interventional techniques. The balloon is automatically inflated until it conforms to the size and shape of the vessel lumen, and the console software calculates the average luminal diameter to the hundredth millimeter. This has provided us quick, cost-effective, IVUS-equivalent vessel-sizing information that facilitates our definitive PVI decisions, especially if specialty-balloon PTA or infrapopliteal stenting is required.

Before adopting the MC system, we rarely (if ever) used the balloon-compliance charts or balloon-expandable stent-sizing charts that accompany all balloons and stents and are also calibrated to the hundredth millimeter. Since adopting the MC system in our lab, our selections of peripheral balloons, specialty balloons, laser catheters, atherectomy devices, and infrapopliteal stents have been made with more precise vessel sizing information, and we now rely on the compliance charts during each PVI. We recently reported our initial experience in MC sizing versus operator estimation in 69 vessels during 55 PVIs for

CLI and found approximately 50% of all vessel sizes were overestimated or underestimated by  $\pm 6.5$  mm, and the final treatment frequently changed with a significant increase in infrapopliteal stenting. We believe this PCI-like approach to treating infrapopliteal vessels will help to improve PVI outcomes.<sup>21,22</sup>

## Crossing CTOs

In the spirit of treating the infrapopliteals like the LAD, we have tried to utilize and optimize true luminal or central luminal crossing of peripheral CTOs without creating subintimal dissection planes analogous to the way CTOs are crossed during PCI. We believe a central luminal, non-subintimal CTO crossing would allow optimal definitive therapy without taking away any device or technology options, whereas a non-true luminal, subintimal CTO crossing would eliminate or compromise several options, including most atherectomy technologies. We have recently adopted the Crosser (FlowCardia, Inc., Sunnyvale, CA) as our first-line strategy in crossing and treating peripheral CTOs (Figure 2). The Crosser uses ultrahigh-frequency ultrasound energy delivered at the device tip over a .014- or .018-inch wire to facilitate CTO crossing. The device tip is then slowly advanced through the entire length of the CTO, and the wire is advanced through the device tip only after the device has crossed into the patent distal true lumen as identified under angiographic guidance. We have just completed a 6-month analysis in approximately 100 CTOs, and we were able to obtain first-line true luminal crossing in 90% of the cases without a single perforation or complication. In those unsuccessful cases, we are increasingly using creative direct pedal access approaches to achieve endovascular revascularization. The pedal-plantar loop technique will be addressed in depth by Dr. Marco Manzi in this issue (page 62).

We now advocate the Crosser in all lower extremity CTOs as a first-line crossing strategy before any attempts with contemporary wire-crossing strategies. We believe this will maximize our ability to secure a central luminal crossing, avoid unwanted dissection tracts, and optimize all definitive therapeutic PVI options; this central luminal crossing pathway will become increasingly important with the development of drug-eluting balloons and future bioabsorbable technologies, which, similar to contemporary atherectomy technologies, are designed to perform optimally in a nonsubadventitial dissection plane. The Crosser has allowed us to almost completely eliminate popliteal sticks and the need for re-entry devices in our CLI cases. We have found the Crosser to be a safe and consistently effective option for the interventional treatment of CLI and complex infrainguinal CTOs.

## Embolic Protection Devices

Although still considered controversial because of a lack of randomized data, we have adopted embolic protection devices (EPDs) as a top-shelf tool in our CLI toolbox. Our experience has been that in select higher-risk CLI cases, the incidence of micro- and macroscopic debris is  $>70\%$ , which has been confirmed by several other reports.<sup>23-27</sup> We have lowered our threshold for using the SpiderX EPD (ev3 Inc.) in our CLI patients with adequate distal landing zones and single-vessel runoff, acute symptoms, suspected thrombus, CTOs, highly calcific and atherosclerotic lesions, in-stent restenosis, lower extremity bypass grafts, and in any case with a high likelihood of distal embolic debris. We have found this device to be easily delivered (we often utilize delivery and partial capture the EPD with a .035-inch Spectranetics Quick-Cross catheter).

Our experience with EPDs in CLI patients has been very favorable to date, and distal filter protection has provided many of our complex CLI patients with a protective safety net during creative limb salvage PVI in which even microembolic debris could have catastrophic complications. Creative EPD strategies are now applied in high-risk patients who otherwise would have been extended only an open surgical bypass option. Another benefit is that the EPD has allowed us to be more aggressive with all of our atherectomy debulking cases. The filter EPD is rapidly becoming as important a tool in our CLI toolbox as any of the other emerging infrainguinal endovascular revascularization tools and has expanded our abilities to apply endovascular techniques to an increasingly more complex subset of CLI patients. Randomized data are certainly needed to validate efficacy and justify costs.

## Targeted Renal Therapy

The CLI patient has a higher incidence of diabetes, pre-existing chronic kidney disease, and advanced age when compared to a PCI patient population. Therefore, CLI patients are at much higher risk for CIN during PVI. The use of CTA, the need for multiple or frequent secondary PVIs, and the complexity of PVI cases further underscore the CLI patient's risk for worsening renal function and CIN. We have adopted targeted renal therapy (TRT) using the Benephit catheter system (AngioDynamics, Queensbury, NY) as a strategy in preventing CIN in our high-risk CLI patients.

TRT is an emerging novel treatment in which high-dose fenoldopam (FEN), a selective renal dopamine-1 receptor agonist and renal arteriolar vasodilator, is infused into both renal arteries via the 5-F bifurcated Benephit PV Catheter Infusion System. TRT has been

shown to significantly increase the glomerular filtration rate by 25% versus placebo and IV-FEN ( $P < .001$ ), which may have important clinical implications in CIN prophylaxis.<sup>28-31</sup> The recently published Be-RIte Registry reported the real-world TRT results in 501 high-risk PCI, PVI, and surgical patients.<sup>29</sup> TRT was reported to be safe, feasible, and simple with a statistically significant decreased incidence of CIN (8.2% vs 27.3%,  $P = < .0001$ ) when compared to the validated Mehran score of predicting CIN in high-risk patients. Randomized, validated data remain pending, but we have found TRT to be valuable in our high-risk patients, especially the 30% to 40% of CLI patients who require bilateral PVIs or secondary reinterventions within 12 months. Our typical patient would have a creatinine clearance of  $< 60$  mL/min and a peri- and postprocedural infusion of FEN at  $0.4 \mu\text{g/kg}$  per min would be administered from 1 to 4 hours. The sheath is removed with manual compression. TRT should not be a substitute for renal hydration, which is the only validated CIN prophylaxis strategy. We also advocate the Acist CVi device (Acist Medical Systems, Inc., Eden Prairie, MN) for contrast delivery, as it has been shown to allow decreased contrast use and optimal contrast utilization in PVI.<sup>32,33</sup>

### Vascular Access Management

The CLI patient poses several challenges with vascular access including a higher risk of vascular access management (VAM) complications. We believe close scrutiny of the preprocedure CTA will optimize the vascular access route, because the CLI patient will often have challenging variables such as iliofemoral vascular calcifications, grafts, tortuosity, thrombus, aneurysms, groin scarring, and stents. In an effort to decrease bleeding complications and optimize our anticoagulation strategy, we utilize direct thrombin inhibition with bivalirudin (Angiomax, The Medicines Company, Parsippany, NJ) and avoid heparin and its multiple limitations in our CLI patients. Additionally, we will use IIb/IIIa inhibition in our most challenging CLI patients who are not at high risk for distal macro- or microembolization, slow flow or no flow, or with advanced tissue loss in which any peri- or postprocedural platelet aggregation would be poorly tolerated. There are no randomized data supporting direct thrombin inhibition or IIb/IIIa use in CLI, but we and others have found this strategy to be safe and feasible.<sup>34-36</sup>

We avoid using all vascular closure devices (VCDs) during PVI primarily because the devices are not reliable in challenging vascular access cases, and we do not want to leave VCD debris (suture, staple, collagen, thrombin, glue, etc.) behind that could further compromise previous vascular access and injure the already diseased

vascular access vessel. We always stick with fluoroscopy and use the Pinnacle TIF Tip Introducer Sheath (Terumo Interventional Systems, Somerset, NJ) as our introductory sheath in all cases. The novel TIF sheath was developed for scarred groins and calcified vessels and uses a smoother and stiffer dilator with a proprietary treatment at the dilator-sheath tip transition zone to avoid sheath kinking, peeling, fish mouthing, need for stiffer wires, microsheaths, and additional maneuvers that are often necessary just to gain vascular access during PVI. We believe this optimal arteriotomy will decrease vessel and perivascular tissues and facilitate all other aspects of VAM.

After PVI, we use the Catalyst System (formerly Boomerang) (Cardiva Medical, Mountain View, CA) to assist arteriotomy closure in all vessels including femoral, brachial, popliteal, and axillary artery access. The Catalyst System allows natural elastic recoil of the vessel wall to convert the larger 6- to 8-F arteriotomy to an 18-gauge needle hole where the system is removed, and light manual compression is applied; therefore, VAM is facilitated without leaving any VCD debris behind. Integral to this VAM strategy is the use of bivalirudin with a  $T_{1/2} = 22$  minutes versus heparin 2 to 4 hours so that the patient is at normal anticoagulation levels when the temporary Catalyst disk is removed, and the 18-gauge needle hole is compressed.

### CONCLUSION

Our contemporary CLI tool box continues to expand, much like the interventional and noninterventional treatments for coronary artery disease during the previous 2 to 3 decades. We believe it is now time to approach the infrapopliteals and CLI patients in a similar fashion as cardiologists refined the treatments for coronary artery disease and the LAD. Hopefully, analogous to PCI, these contemporary refined CLI strategies will result in improved outcomes and fewer amputations. It will be up to us as advocates of the contemporary CLI tool box to justify these strategies with validated outcomes and cost-analysis data. ■

*The authors thank Kelly Tilbe, NCMA, for her help with manuscript preparation.*

*David E. Allie, MD, is Medical Director of Cardiovascular and Endovascular Surgery, Louisiana Cardiovascular and Limb Salvage Center, APMC, in Lafayette, Louisiana. Dr. Allie has disclosed that he is on the medical advisory board and is the recipient of PVD training and research grant support from AngioScore, Spectranetics, FlowCardia, Neovasc, Bracco, Cardiva Medical, The Medicines Company, IDEV,*

and Terumo. He has also disclosed that he has received PVD training support from CSI. He received research grant funding from FlowMedica in 2008 prior to the AngioDynamics acquisition of FlowMedica and that he has stock equity in IDEV. He discloses that he received no funding for this manuscript. Dr. Allie may be reached at (337) 456-6523; david.allie@cv-limbsalvage.com.

Raghotham R. Patlola, MD, is an interventional cardiologist at the Cardiovascular Institute of the South in Lafayette, Louisiana. He has disclosed that he holds no financial interest in any product or manufacturer mentioned herein. Dr. Patlola may be reached at (800) 582-2435; raghotham.patlola@cardio.com.

Agostino Ingraldi, MD, is an interventional cardiologist at the Cardiovascular Institute of the South in Lafayette, Louisiana. He has disclosed that he holds no financial interest in any product or manufacturer mentioned herein. Dr. Ingraldi may be reached at (800) 582-2435; agostino.ingraldi@cardio.com.

Chris J. Hebert, RT(R), RCIS, is Director of Cardiovascular Services at the Cardiovascular Institute of the South and Director of the Catheterization Lab at Southwest Medical Center in Lafayette, Louisiana. He has disclosed that he holds no financial interest in any product or manufacturer mentioned herein. Mr. Hebert may be reached at (800) 582-2435; chris.hebert@hcahealthcare.com.

Craig M. Walker, MD, is Medical Director/Founder of the Cardiovascular Institute of the South in Houma, Louisiana. He has disclosed that he is a consultant to Boston Scientific Corporation, Cardiva, CV Therapeutics, Edwards Life Sciences, ev3, Flowmedica, IDEV, Possis, Spectranetics, and Terumo. He has disclosed that he has participated in PVD training courses by ev3, IDEV, Medtronic, and Spectranetics. He has stock equity in Cardiva, CV Therapeutics, IDEV, Spectranetics, and vased. He has also disclosed that he serves on the medical/scientific boards for IDEV, Spectranetics, and vased and that he is on the speaker's bureau for Abbott, AstraZeneca, Bristol-Myers Squibb/Sanofi Pharmaceutical, Cardiva, CV Therapeutics, Pfizer, Sanofi, and Spectranetics. Dr. Walker may be reached at (800) 445-9676; craig.walker@cardio.com.

1. US Department of Health and Human Services. National Center for Health Statistics. National Hospital Discharge Survey: Annual Summary with Detailed Diagnosis and Procedure Data. Data from the National Hospital Discharge Survey. Series 13. 1983-2000.
2. Yost ML. Peripheral Arterial Disease: A Report by The Sage Group. 2004;Vol. II.
3. Yost ML. Critical Limb Ischemia. Volume II. Western Europe epidemiology. Atlanta (GA): The Sage Group; 2008.
4. Allie DE, Hebert CJ, Lirtzman MD, et al. Critical limb ischemia: a global epidemic. A critical analysis of current treatment unmasks the clinical and economic costs of CLI. *EuroIntervention* J. 2005;1:75-84.
5. Lavery LA, Boulton AJ, Niezgoda JA, et al. A comparison of diabetic foot ulcer outcomes using negative pressure wound therapy versus historical standard of care. *Int Wound J*. 2007;4:103-113.
6. Allie DE, Hebert CJ, Walker CM. Multidetector computed tomography angiography: two decades of evolution in this imaging modality have produced some powerful and unprecedented options. *Endovasc Today*. 2004;3:20-28.

7. Allie DE, Patlola RR, Ingraldi A, et al. Expanding the role of PV-CTA in the overall management of PVD. *Endovasc Today*. 2008;3:46-61.
8. Boykin JV, Baylis C. Homocysteine: a stealth mediator of impaired wound healing: a preliminary study. *Wounds*. 2006;18:101-116.
9. Allie DE. Breakthrough medical approach in the management of patients with diabetic neuropathy: a compendium of case studies and clinical decision making. Introduction. *Vasc Disease Management*. 2005;November/December(suppl).
10. Heneghan HM, Sultan S. Homocysteine, the Cholesterol of the 21st Century. Impact of hyperhomocysteinemia on patency and amputation-free survival after intervention for critical limb ischemia. *J Endovasc Ther*. 2008;15:399-407.
11. Patlola RR, Allie DE, Ingraldi A, et al. Early results of focal pressure balloon angioplasty in critical limb ischemia. Abstract presented at CRT 2009, Omni Shoreham Hotel. Washington, DC, March 4-6, 2009.
12. Tepe G, Zeller T, Albrecht T, et al. Local delivery of paclitaxel to inhibit restenosis during angioplasty of the leg. *N Engl J Med*. 2008;14:689-699.
13. Laird JR, Zeller T, Gray BH, et al, for the LACI Investigators. Limb salvage following laser-assisted angioplasty for critical limb ischemia: results of the LACI multicenter trial. *J Endovasc Ther*. 2006;13:1-11.
14. Bishop PD, Feiten LE, Ouriel K, et al. Arterial calcification increases in distal arteries in patients with peripheral arterial disease. *Ann Vasc Surg*. 2008;22.
15. Fierling JF, Wesolowski AA, Lade S. Primary stent-supported angiography for treatment of below-knee critical limb ischemia and severe claudication. *JACC*. 2004;9:101-106.
16. Scheinert D. The Cypher below the knee pilot study. Presented at EuroPCR in Paris, France; May 2005.
17. Siablis D, Kraniotis P, Karnabatidis D, et al. Sirolimus-eluting versus bare metal stents for bailout after suboptimal infrapopliteal angioplasty for critical limb ischemia: 6-month angiographic results from a nonrandomized prospective single-center study. *J Endovasc Ther*. 2005;12:685-695.
18. Rand T. Infrapopliteal stenting: early data and experiences with a promising option for preventing amputation. *Endovasc Today*. 2006;5:56-58.
19. Scheinert D. SFA Stent Technology Update. Presented at: TCT 2008, Washington Convention Center, Washington, DC, October 12-17, 2008.
20. Scheinert D. News in SFA stent technology. Presented at Leipzig Interventional Course (LINC), Heart Center & University of Leipzig, Leipzig, Germany, 14-17, 2009.
21. Allie DE, Hebert CJ, Patlola RR, et al. Optimizing infrapopliteal interventions with "vesel sizing" therefore treating the "infrapops like the LAD": a safety and feasibility analysis of the Metracath system. *Am J Cardiol*. 2008;102(suppl):TCT-607.
22. Allie DE, Hebert CJ, Patlola RR, et al. Optimal vessel sizing in peripheral vascular interventions: treating the peripheral and infrapopliteal arteries like the LAD. *Endovasc Today*. 2009;1:34-38.
23. Allie DE. Distal embolization in lower extremity interventions: it's time we "get our heads out of sand." *Vasc Disease Management*. 2008;January 1. Available at <http://vasculardiseasemanagement.com/article/8245>
24. Allie DE. To PROTECT or not to PROTECT? In lower extremity angioplasty procedures, "Why not?" Is the question! *J Endovasc Ther*. 2008;15:277-282.
25. Shammass NW, Dippel EJ, Coiner D, et al. Preventing lower extremity distal embolization using embolic filter protection: results of the PROTECT registry. *J Endovasc Ther*. 2008;15:270-276.
26. Karnabatidis D, Katsanos K, Kagadis GC, et al. Distal embolism during percutaneous revascularization of infraaortic arterial occlusive disease: an underestimated phenomenon. *J Endovasc Ther*. 2006;13:269-280.
27. Suri R, Wholey MH, Postak D, et al. Distal embolic protection during femoropopliteal atherectomy. *Cathet Cardiovasc Interv*. 2006;67:417-422.
28. Teirstein PS, Price MJ, Mathur VS, et al. Differential effects between intravenous and targeted renal delivery of fenoldopam on renal function and blood pressure in patients undergoing cardiac catheterization. *Am J Cardiol*. 2006;97:1076-1081.
29. Weisz G, Filby SJ, Cohen MG, et al. Safety and performance of targeted renal therapy: the Be-RIte Registry. *J Endovasc Ther*. 2009;16:1-12.
30. Allie DE, Hebert CJ, Patlola RR, et al. A review of the early experience with targeted renal therapy for renal function preservation during endovascular and surgical treatments for cardiovascular disease. *Expert Review*. *EuroIntervention* 2007;3:121-127.
31. Allie DE, Hebert CJ, Walker CM. Automated contrast injection and targeted renal therapy: strategies to prevent contrast-induced nephropathy and treat renal insufficiency in patients with peripheral arterial disease. *Vasc Disease Manag*. 2006;3:248-254.
32. Goldstein JA, Kern M, Wilson R. A novel automated injection system for angiography. *J Interv Cardiol*. 2001;14:147-152.
33. Anne G, Gruberg L, Huber A, et al. Traditional versus automated injection contrast system in diagnostic and percutaneous coronary interventional procedures: comparison of the contrast volume delivered. *J Invas Cardiol*. 2004;16:360-362.
34. Allie DE, Hebert CJ, Lirtzman MD, et al. Continuous tenecteplase (TNK) infusion combined with peri/postprocedural platelet glycoprotein IIb/IIIa inhibition in peripheral arterial thrombolysis: initial safety and feasibility experience. *J Endovasc Ther*. 2004;11:427-435.
35. Allie DE, Hebert CJ, Lirtzman MD, et al. Combined glycoprotein IIb/IIIa and direct thrombin inhibition with eptifibatide and bivalirudin in the interventional treatment of critical limb ischemia: a safety and feasibility report. *Vasc Disease Manag*. 2006;3:368-375.
36. Shammass NW, Dippel EJ, Shammass GA, et al. Utilization of GP IIb/IIIa inhibitors in peripheral percutaneous interventions: current applications and in-hospital outcomes at a tertiary referral center. *J Invasive Cardiol*. 2008;20:266-269.