

# Pros and Cons of IVUS Imaging for Endovascular Procedures

An overview of IVUS technology, discussing both its ideal uses and the potential drawbacks that must be considered.

BY TAKAO OHKI, MD, PhD

Intravascular ultrasound (IVUS) is an alternative or adjunctive imaging technique for endovascular procedures, assisting with evaluating vessel morphology in the peripheral vasculature by providing a cross-sectional image of the vessels. IVUS may be used during endovascular aneurysm repair (EVAR), thoracic endovascular aneurysm repair (TEVAR), carotid, subclavian, mesenteric, renal, iliac, superficial femoral artery (SFA), popliteal, and inferior vena cava (IVC) filter procedures. The IVUS catheters required are selected based on the guidewire platform for the endovascular procedure (eg, .014-, .018-, or .035-inch).

IVUS catheters are designed for use as an adjunct to conventional angiographic procedures to provide an image of the vessel lumen and its wall structures. IVUS consoles may

be either “roll-around” systems or integrated into an endovascular procedure room. This article outlines the benefits of incorporating IVUS technology, as well as discussing the added costs and time requirements.

## CLINICAL ADVANTAGES

### CT Measurement Confirmation in Stent Graft Placement

Preprocedure CT scans provide anatomical diameter and length measurements for EVAR and TEVAR case planning. If, on CT, the proximal neck diameter (Figure 1) or length is considered to be “borderline” within the sizing criteria for endovascular stent graft placement, IVUS can be used to further assess the diameter and length of the landing zone. Also, if the CT scan was obtained some time before the EVAR or TEVAR procedure, aortic diameters may change

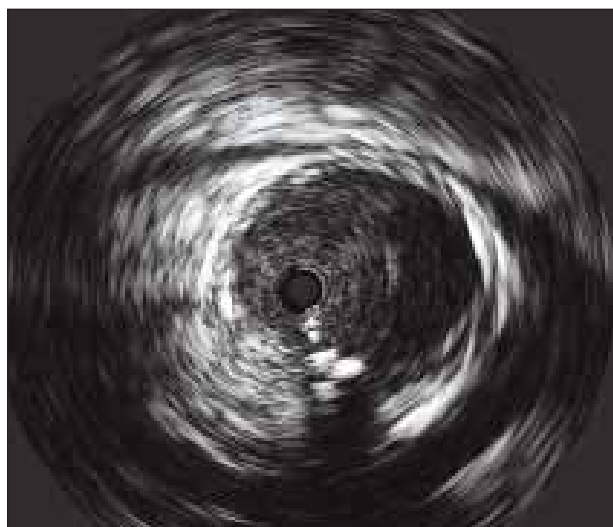


Figure 1. Grayscale IVUS image of a proximal infrarenal neck.

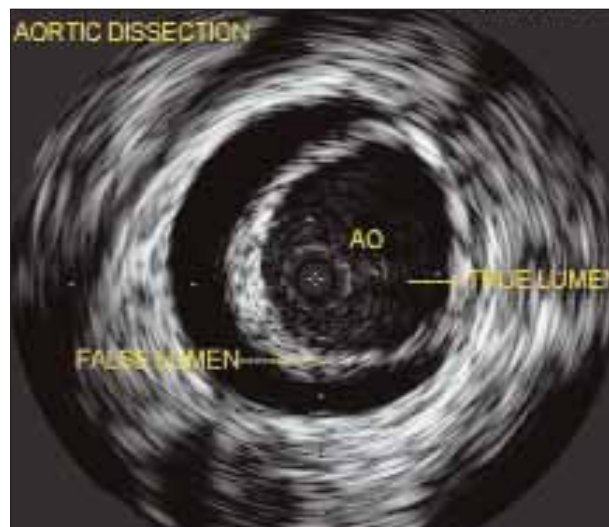

Figure 2. Grayscale IVUS image of an aortic dissection.

due to possible aneurysm growth or hemodynamic volume differences. IVUS can be used at the time of the endovascular procedure to confirm these measurements.

### Contrast Reduction

Incorporating IVUS can reduce the amount of contrast required during EVAR or TEVAR procedures, in that the patient's anatomy may be mapped using IVUS instead of a bolus angiogram. In order to do so, the .035-inch IVUS catheter is advanced over the starter guidewire, and the transducer is positioned above the proximal landing zone. The IVUS catheter is slowly retracted, and the side branches are identified. Some physicians place a radiopaque ruler under the patient to assist with side branch location. The side branch is centered on the fluoroscopic image to reduce parallax, and a technician can record the locations and measurements. When the stent graft is being deployed at the proximal landing zone, a small amount of contrast is injected to confirm placement. The bolus angiogram can be saved until the end of the procedure to assess endoleak status.

### In the Absence of CT or MR

If no CT or MR imaging is available before the procedure, which can occur if a patient arrives as an outside referral or in acute cases, IVUS can allow the interventionist to obtain real-time diameter and length measurements to assist in selecting properly sized endograft devices during the endovascular procedure.

### Dissection

Another application of IVUS is to identify the true lumen versus the false lumen in dissection cases (Figure 2).<sup>1,2</sup> An over-the-wire IVUS catheter allows the interventionist to advance the guidewire, then the IVUS catheter, then guidewire, then IVUS catheter to ensure that the interventional equipment stays in the true lumen while being advanced.

### IVC Filter Placement

Some physicians use IVUS as an adjunct modality during IVC filter placements. IVUS may identify the renal veins and the position at which to deploy the filter. After gaining experience interpreting angiography and IVUS images, some physicians prefer to perform bedside IVC filter placements. This can be especially helpful in patients who have had hip surgery, bariatric surgery, or trauma, and may be difficult to move, or simply if the endovascular suite is booked. Placement of IVC filters with real-time IVUS imaging requires two venous access sites, one for the filter delivery system and one for the IVUS catheter.<sup>3</sup> Alternate deployment methods with a single puncture technique have been described.<sup>4,5</sup>

### Completeness of Treatment

For peripheral endovascular procedures, IVUS can be used to assess the completeness of treatment, such as stent-wall apposition and results after percutaneous transluminal angioplasty, atherectomy, or laser procedures. IVUS after EVAR and TEVAR procedures may provide information regarding stent graft landing zone apposition.

### Incorporating Virtual Histology and ChromaFlo

Virtual histology (VH) IVUS may help in determining which patients are candidates for carotid stenting versus those who are better suited for carotid endarterectomy. Fibrous, fibro-fatty, dense calcium, and necrotic core areas are color coded by the platform's software (Figures 3 and 4). The science and application of VH IVUS for carotids is being investigated.<sup>6</sup> Some physicians, including myself, are interested in studying the SFA with VH IVUS to see if plaque morphology can help in better understanding how to treat the SFA with endovascular devices.

ChromaFlo IVUS demonstrates colorized blood flow inside the vessel lumen, which is helpful in distinguishing echolucent disease from luminal blood flow. ChromaFlo may assist with detecting blood flow outside the vessel. A small intimal flap after intervention can be detected before it is flow limiting, and the flap can be addressed with interventional techniques before the patient leaves the endovascular suite to prevent a possible secondary procedure.

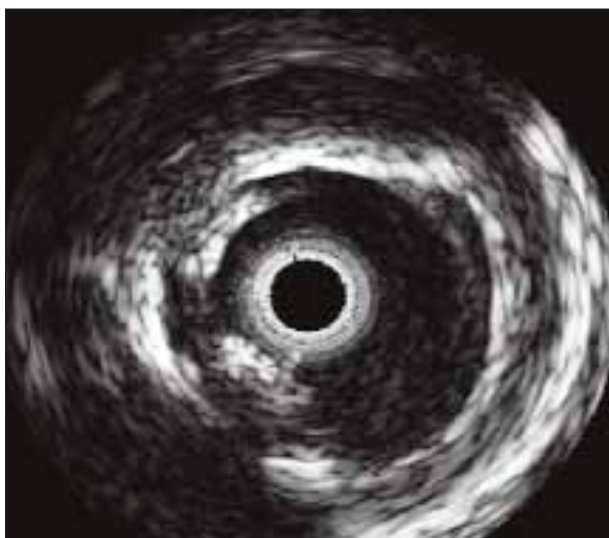
## DISADVANTAGES TO CONSIDER

### Adding to Procedural Times

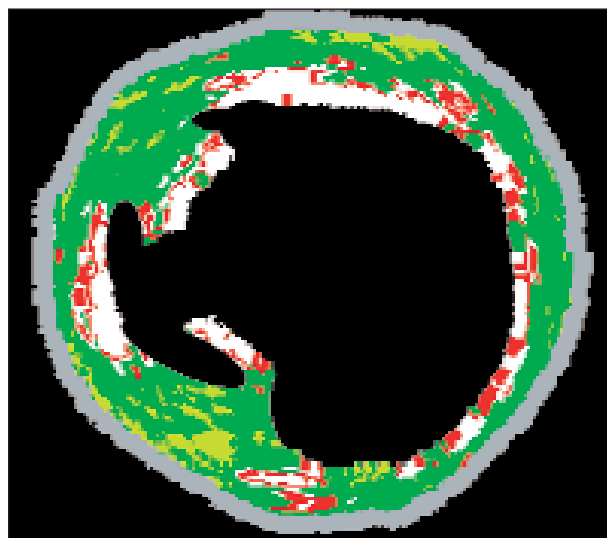
As adjunctive therapeutic devices come with certain drawbacks that must be weighed against their advantages, so too do adjunctive imaging modalities. One such consideration is that use of IVUS may add time to the procedure. This is especially the case if the IVUS system and catheters are not regularly located in the procedure room; it takes time to locate the system, bring it into the room, and get it up and running. If the nurses or technicians do not use IVUS routinely, taking measurements will use even more time.

### Cost

In most instances, the facility needs to purchase the IVUS console and catheters. The IVUS console is generally considered capital equipment, and the facility may have budget processes that make such expenditures difficult, such as that it may take additional time for the facility to approve purchase of the IVUS consoles. Also, IVUS catheters are disposable materials. They may be used multiple times within one procedure, but they are intended strictly for one-patient, one-time use.



**Figure 3.** Grayscale IVUS image of a carotid artery showing presence of an eccentric, echogenic plaque that is less likely to generate embolic material.



**Figure 4.** VH IVUS image of a carotid artery (fibrous = green; fibro-fatty = light green; dense calcium = white; necrotic core = red). VH allows one to diagnose vulnerable/unstable plaque. This image also shows presence of an ulcer.

## Reimbursement Barriers

As is the case with all technologies, reimbursement for IVUS use varies according to the country in which the procedure is performed. For example, when I am practicing in the US, I use IVUS less frequently because all endovascular procedures are reimbursed under a lump-sum global payment in the US. Thus, the fewer devices one uses, the more profit the hospital receives. On the other hand, when I am practicing in Japan, I use IVUS for nearly all of my arterial interventions, including EVAR, TEVAR, and lower-extremity interventions. This is because in Japan, devices are charged to the carrier on a fee-for-service (or fee-for-device) basis.

## The Learning Curve

Physicians, nurses, and technicians starting to use IVUS will have to work through a learning curve in order to properly interpret the images generated and maximize the usefulness of the technology. During this time, endovascular procedures may need to be coordinated with the manufacturer's representative so that case support can be scheduled and provided.

## SUMMARY

The incorporation of IVUS may help vascular interventionists meet clinical needs such as assessing "no-neck" EVAR or TEVAR patients, reducing contrast in patients with compromised renal function, identifying thrombus and calcium, and assessing stent-wall apposition. Diameter and length measurements may also be confirmed in real time. In dissection cases, IVUS may be instrumental in identifying true versus false lumens. However, the cons of using IVUS include

added time expenditure, costs, and learning the skills required for IVUS interpretation. The cost of IVUS may also need to be included in the facility budget, which could involve additional hurdles. Developing a solid understanding of the steps required for obtaining IVUS images and measurements may reduce the time required during the procedure, but this takes time and training. If an efficient routine is established, as it is in my OR in Japan, the time to record IVUS measurements is clearly reduced. The IVUS console is always in the room and is routinely utilized. Our physicians and staff members are comfortable acquiring and interpreting IVUS images. In weighing the pros and cons of IVUS, I believe that it is fair to say, "More information is better than less." ■

*Takao Ohki, MD, PhD, is Chairman, Department of Surgery and Professor and Chief, Division of Vascular Surgery; Jikei University School of Medicine, in Tokyo, Japan, and Professor of Surgery, North Shore LIJ Health System, Albert Einstein College of Medicine, in New York. He has disclosed that he holds no financial interest in any products or manufacturer mentioned herein. Dr. Ohki may be reached at takohki@msn.com.*

1. Song, T, Donayre, C, Kopchok, G, White, R. Intravascular ultrasound use in the treatment of thoracoabdominal dissections, aneurysms and transections. *Seminars in Vasc Surg.* 2006;19:145-149.
2. Goldstein L, Ramaiah V, McKinsey J. TEVAR for the ruptured thoracic aorta. *Endovasc Today.* 2007;6:74-78.
3. Wellons E, Matsuura J, Shuler F, et al. Bedside intravascular ultrasound-guided vena cava filter placement. *J Vasc Surg.* 2003;38:455-458.
4. Chiu A. Intravascular ultrasound-guided bedside placement of inferior vena cava filters. *Seminars Vasc Surg.* 2006;19:150-154.
5. Jacobs D, Motaganahalli R, Peterson B. Bedside vena cava filter placement with intravascular ultrasound: a simple, accurate single venous access method. *J Vasc Surg.* 2007;46:1284-1286.
6. Diethrich E, Margolis P, Reid D, et al. Virtual histology intravascular ultrasound assessment of carotid artery disease: the CAPITAL study. *J Endovasc Ther.* 2007;14:676-686.