

# Nonstent Endovascular Treatment of SFA Occlusions

High failure rates of balloon angioplasty and stent fracture suggest a need for nonstent alternatives.

BY ROBERT S. DIETER, MD, RVT, AND JOHN R. LAIRD, JR, MD

**P**eripheral arterial disease (PAD) affects at least 8 million to 10 million Americans.<sup>1</sup> The superficial femoral artery (SFA) is one of the most commonly involved arteries in patients with lower-extremity PAD. There are several biomechanical and physical characteristics that may predispose the SFA to the development of atherosclerotic vascular disease, particularly chronic total occlusions (CTOs).

Percutaneous transluminal angioplasty (PTA), as a stand-alone procedure, often fails for the treatment of CTOs of the SFA. Several series have shown patency rates of <20% when PTA is applied for long (>10 cm) SFA occlusions.<sup>2,3</sup> The large plaque/thrombus burden, exten-

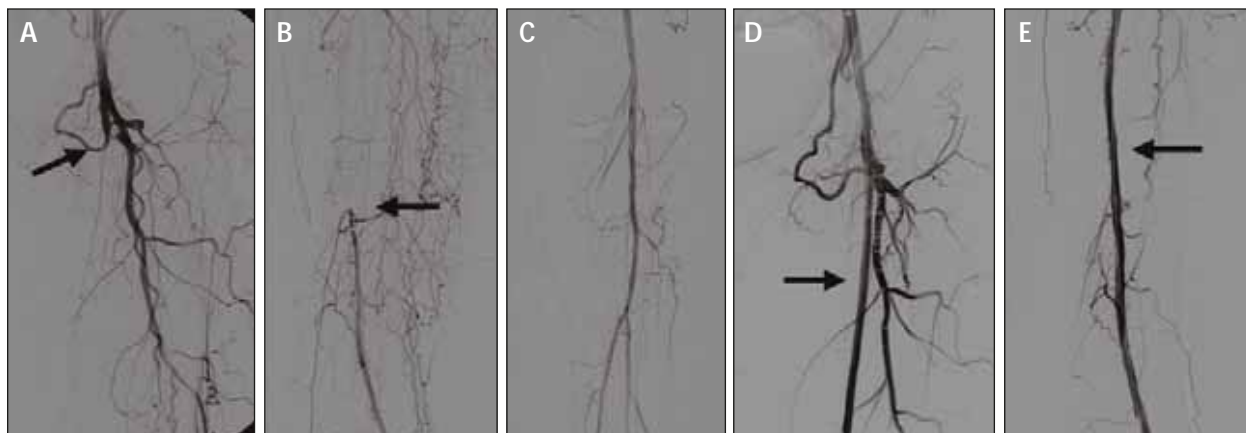“Once SFA in-stent restenosis or occlusion occurs (particularly when it is diffuse), there is no proven effective therapy.”

sive calcification, and poor flow dynamics result in an unfavorable milieu for PTA. Balloon angioplasty provides unsatisfactory acute results due to a high degree of elastic recoil and frequent flow-limiting dissection. Stenting is often performed as a provisional therapy or as a primary treatment option due to the ability of stents to provide a better angiographic result by resisting elastic recoil and sealing dissections. The limitations of stenting in the SFA, however, have been well described. Although short- and intermediate-term patency rates appear improved with newer nitinol stents compared to first-generation stents, issues related to delayed or late in-stent restenosis remain. Once SFA in-stent restenosis or occlusion occurs (particularly when it is diffuse), there is no proven effective therapy. Furthermore, many questions remain regarding the impact of stent fracture in the SFA. Although it appears to be a device-dependent phenomenon, stent fracture has been linked to a higher rate of restenosis. Scheinert et al reported a 67.2% rate of restenosis or occlusion in fractured stents.<sup>4</sup>

Due to the high failure rate of traditional balloon angioplasty in the SFA and limitations of stenting, includ-



Figure 1. Features of the new 2.5-mm Turbo excimer laser catheter (right) compared to the 2.5-mm Extreme catheter (Spectranetics). Increased fiber density provides for greater energy delivery and better debulking.



**Figure 2.** A long occlusion from the origin of the SFA down to the region of the adductor canal (A-C). An excellent result following successful laser angioplasty and adjunctive balloon dilatation (D-E).

ing concern about stent fracture, alternative nonstent options for the endovascular treatment of SFA occlusions have been sought. Leading nonstent modalities include debulking devices such as the excimer laser (ClirPath Excimer Laser, Spectranetics Corporation, Colorado Springs, CO) and excisional atherectomy (FoxHollow Technologies, Redwood City, CA), as well as innovative balloon technologies such as cryoplasty (CryoVascular PolarCath System, Boston Scientific Corporation, Natick, MA).

## EXCIMER LASER

Advances in laser catheter design and refinement of recanalization techniques have resulted in improved results with laser-assisted angioplasty of complex PAD (Figure 1).<sup>5,6</sup> The 308-nm excimer laser utilizes flexible fiber-optic catheters to deliver intense bursts of ultraviolet (UV) energy in short pulse durations. Tissue is ablated only on contact, with minimal surrounding thermal injury. A unique feature of UV light is its ability to ablate plaque and thrombus and thus reduce the potential for embolic complications. Excimer laser atherectomy of peripheral arteries has been practiced commercially in Europe since 1994 and has been shown to be a useful adjunct for the treatment of long SFA occlusions.<sup>5</sup> Debulking with the excimer laser prior to adjunctive balloon angioplasty offers the advantage of a better angiographic result with less dissection and reduced need for stenting (Figure 2). This may be particularly advantageous for long (>20 cm) occlusions in which multiple stents would be required. Furthermore, using the “step-by-step” technique (wireless laser-assisted angioplasty) in which the laser is used to create a wire channel, can be very useful in total occlusions that are refractory to traditional guidewire crossing techniques.<sup>7</sup>

The Peripheral Excimer Laser Angioplasty (PELA) trial, a multicenter, randomized, prospective study, evaluated PTA versus PTA after laser pretreatment for chronic SFA occlusions >10 cm. In patients treated with laser debulking compared to initial PTA, there was a 17% reduction in stent utilization (42% vs 59%, respectively) and less distal embolization (3% vs 9%) with equivalent 1-year patency rates.<sup>8</sup> In the Laser Angioplasty for Critical Limb Ischemia (LACI) trial, 42% of the lesions treated were in the SFA with complex occlusive disease in the majority of patients.<sup>9</sup> This approach resulted in an excellent limb salvage rate of 93% at 6 months.

## FOXHOLLOW ATHERECTOMY

The other commonly employed debulking technique is plaque excision using the the FoxHollow SilverHawk atherectomy catheter (Figure 3). The SilverHawk is a monorail catheter with a carbide cutting blade at the tip. When activated, this blade spins at 8,000 rpm. The SilverHawk is a forward-cutting atherectomy catheter. Plaque is excised as the catheter is advanced through



**Figure 3.** The FoxHollow SilverHawk atherectomy system.

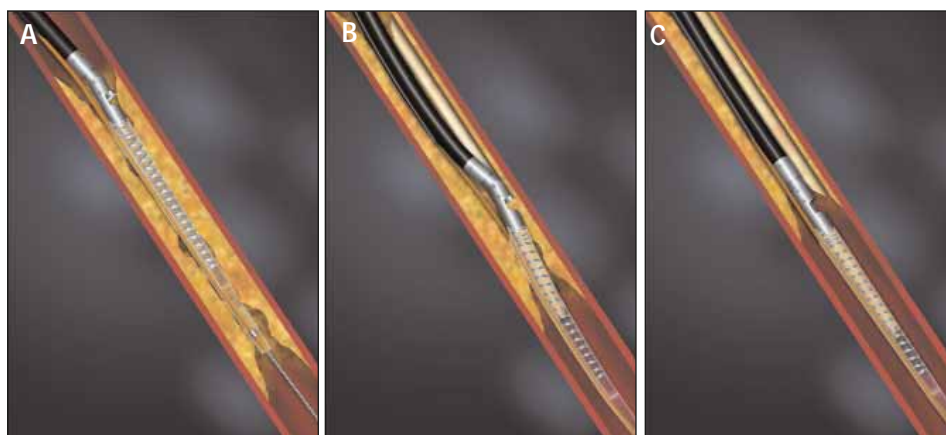


Figure 4. Method of action of the SilverHawk catheter.

the lesion. The excised plaque is collected into the nose cone of the catheter and can subsequently be removed from the body. The nose cone can be cleared and additional passes can be made with the catheter (Figure 4).

The SilverHawk catheter offers the advantage of more effectively debulking lesions compared to excimer laser or other atherectomy devices. In many cases, stand-alone atherectomy can be performed. Disadvantages include the need for a .014-inch guidewire. Most SFA occlusions are best crossed with a .035-inch guidewire. The technique of plaque excision can also be quite tedious when employed in long occlusions. Expense is also an issue. More than one catheter is often required for these procedures at a cost of up to \$2,900 per catheter.

The Treating Peripherals with SilverHawk Outcomes Collection (TALON) registry is a multicenter, prospective, observational database. Recent data from the TALON registry included analysis of 728 patients and 1,517 lesions treated with the SilverHawk catheter.<sup>10</sup> Slightly more than 1:4 lesions were CTOs (28.6%). Approximately 73% required only SilverHawk atherectomy and 6% required adjuvant stenting. At 6 and 12 months, the target lesion revascularization was 10% and 21%, respectively, with a durable response in the ankle-brachial index. No subgroup analysis of the results of excisional atherectomy for femoropopliteal occlusions has been published. Overall, major complication rates in the TALON registry have been remarkably low. There have been recent concerns raised about the potential for distal embolization with this device.

## CRYOPLASTY

Efforts to modify the acute mechanical and cellular stimuli that lead to acute and late restenosis led to the

development of cryoplasty. Cryoplasty combines angioplasty and cold therapy using liquid nitrous oxide as the balloon inflation media. During cryoplasty, the liquid nitrous oxide expands into gas and the PolarCath balloon inflates in stepped 2-atm increments to 8 atm. The phase shift from liquid to gas draws energy, driving the balloon surface temperature down

to the desired temperature of  $-10^{\circ}\text{C}$ . The treatment cycle lasts 20 seconds, the gas is expelled, and the balloon warms and is deflated. The potential advantages of cryoplasty include altered plaque response with more uniform vessel dilation and less medial injury, reduced elastic recoil, positive vessel remodeling, and smooth muscle cell apoptosis (Figure 5).

Cryoplasty has been studied in patients with femoral occlusive disease. In a prospective, multicenter registry, 102 patients with femoropopliteal occlusive disease (14.7% occlusions) were treated with cryoplasty. Procedural success without the need for stents was achieved in 85.3% of cases. The clinical patency rate at 9 months was 82.2%. The duplex primary patency rate was 70.1%, and the primary assisted and secondary patency rates were 94% and 98%, respectively.<sup>11</sup> In the subgroup of patients with CTOs, cryoplasty was a suit-




Figure 5. Current theories regarding the effects of cooling on the vessel wall include altered plaque response, reduced elastic recoil, and apoptosis.

able stand-alone procedure in 67%, with only 33% requiring bail-out stenting (Figure 6). At 9 months, in the subgroup of CTOs treated with cryoplasty, the duplex patency rate was 92.3%, and the clinical efficacy rate was 100%. Interestingly, none of the lesions that required bail-out stenting demonstrated evidence of restenosis at 9 months.

"... results with balloon angioplasty for long SFA occlusions have been particularly disappointing."

Wiechmann et al analyzed their experience with cryoplasty in 41 consecutively treated patients at their center.<sup>12</sup> Of these, 80% were in the SFA and 15% were occlusions. Their immediate technical success (residual stenosis <30%) was 100%. Ten patients had arterial dissections; however, only one was flow-limiting, requiring adjuvant stent placement. At 6 months, follow-up was available in 23 patients. The 6-month clinical patency rate was 87%.

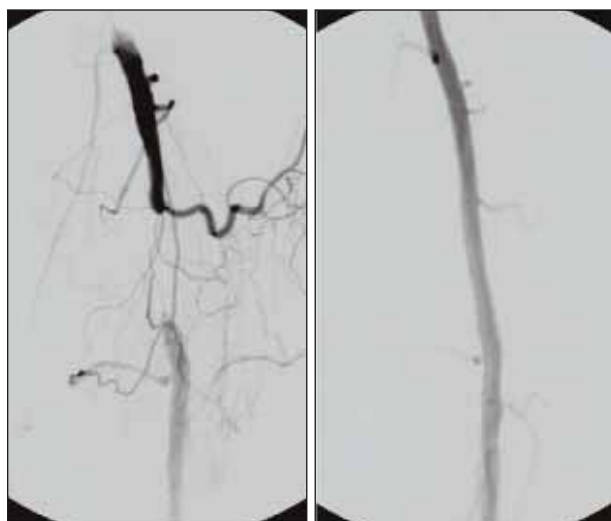
## CONCLUSION

Treatment of femoropopliteal occlusive disease remains one of our greatest challenges. The extensiveness of the disease process in the SFA makes it one of the most difficult vessels to treat. The results with balloon angioplasty for long SFA occlusions have been particularly disappointing. There has been great enthusi-

asm for newer nitinol stents; however, questions remain about the long-term effectiveness of stents and the implications of stent fracture. Consequently, there has been a considerable interest in nonstent technologies that may either reduce the restenosis rate or the utilization of stents in the SFA. At the current time, the three most promising nonstent modalities for the endovascular treatment of SFA occlusions are the excimer laser, cryoplasty, and FoxHollow atherectomy. A number of other promising nonstent technologies are appearing on the horizon. ■

*Robert S. Dieter, MD, RVT, is Director of Vascular Medicine and Peripheral Vascular Interventions, Section of Cardiovascular Medicine, Medical College of Wisconsin, Milwaukee. He has disclosed that he does not hold a financial interest in any product or company mentioned herein. Dr. Dieter may be reached at (414) 456-6817; rdieter@mail.mcw.edu.*

*John R. Laird, Jr, MD, is Director of Vascular Medicine and Peripheral Vascular Interventions, Cardiovascular Research Institute, Washington Hospital Center, Washington, DC. He has disclosed that he is a paid consultant to Spectranetics. Dr. Laird may be reached at (202) 877-5975; John.R.Laird@Medstar.net.*



**Figure 6.** Successful cryoplasty of a short popliteal artery occlusion.

1. Dieter RS, Chu WW, Pacanowski JP Jr, et al. The significance of lower-extremity peripheral arterial disease. *Clinical Cardiol*. 2002;25:3-10.
2. Jeans WD, Armstrong S, Cole SE, et al. Fate of patients undergoing transluminal angioplasty for lower-limb ischemia. *Radiology*. 1990;177:559-564.
3. Capek P, McLean GK, Berkowitz HD. Femoropopliteal angioplasty. Factors influencing long-term success. *Circulation*. 1991;83:170-80.
4. Scheinert D, Scheinert S, Sax J, et al. Prevalence and clinical impact of stent fractures after femoropopliteal stenting. *J Am Coll Cardiol*. 2005;45:312-315.
5. Scheinert D, Laird JR, Schroder M, et al. Excimer laser-assisted recanalization of long, chronic superficial femoral artery occlusions. *J Endovasc Ther*. 2001;8:156-166.
6. Visona A, Perissinotto C, Lusiani L, et al. Percutaneous excimer laser angioplasty of lower limb vessels: results of a prospective 24-month follow-up. *Angiology*. 1998;49:91-98.
7. Boccalandro F, Muench A, Sdringola S, et al. Wireless laser-assisted angioplasty of the superficial femoral artery in patients with critical limb ischemia who have failed conventional percutaneous revascularization. *Catheter Cardiovasc Interv*. 2004;63:7-12.
8. Laird JR. Peripheral excimer laser angioplasty (PELA) trial results. Presentation at Late Breaking Trials. Transcatheter Cardiovascular Therapeutics Annual Meeting, September 2002, Washington, DC.
9. Laird JR, Zeller T, Gray BH, et al. Limb salvage following laser assisted angioplasty for critical limb ischemia: Results of the LACI multicenter trial. *J Endovasc Ther*. 2006;13:1-11.
10. Gammon R. Catheter-based plaque-modification: Cutting balloon and SilverHawk atherectomy (TALON Registry) results. Presentation at the Transcatheter Cardiovascular Therapeutics, October 2005, Washington, DC.
11. Laird JR, Jaff MR, Biamino G, et al. Cryoplasty for the treatment of femoropopliteal arterial disease: results of a prospective, multi-center registry. *J Vasc Intervent Radiol*. 2005;16:1067-73.
12. Weichmann BN, Knight SE. Cryoplasty for treating femoropopliteal occlusive disease. *Endovasc Today*. 2005;June:76-79.