

# Treating Ruptured Abdominal Aortic Aneurysms

Setting up your practice for an endovascular approach.

BY BENJAMIN W. STARNES, MD, FACS

**E**lective endovascular aortic aneurysm repair (EVAR) has become increasingly offered to a majority of patients harboring aortic aneurysms. This technology has enabled definitive improvements in 30-day mortality rates when compared with traditional open surgical repair.<sup>1</sup> Mortality rates for ruptured abdominal aortic aneurysms (rAAAs), however, have not significantly changed in the last 50 years until recently, when select high-volume centers implemented an endovascular approach to this moribund condition.<sup>2</sup> Mehta et al demonstrated an overall mortality rate of 18% for patients undergoing EVAR for rAAA after implementing an endovascular protocol.<sup>2</sup> Despite the impressive reductions in mortality rates, many investigators have been reluctant to incorporate this technology into the management of these complicated patients. This article assists the interested reader in setting up a practice to manage rAAAs utilizing an endovascular approach.

## THE HARBORVIEW EXAMPLE

Harborview Medical Center in Seattle, Washington, is a Level-1 trauma center serving a five-state region representing 25% of the land mass of the US and nearly 15 million people. Approximately 30 to 50 rAAAs are seen and treated annually. In 2007, an endovascular protocol was established to manage this seriously moribund patient population in a timely and efficient manner. Our protocol at Harborview was adopted from that of the Albany Group (Figure 1).<sup>2</sup> The overall 30-day mortality rate when compared to institutional historical controls dropped from 61.5% between 2002 and 2007 to 29% in the first 6 months after instituting the protocol.

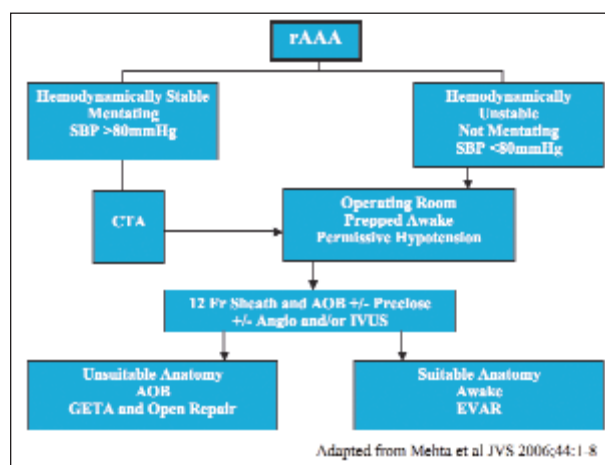


Figure 1. Pathway for patients presenting with rAAA.

## BUILDING YOUR CENTER

It is the author's opinion that certain select centers should seek to build a program for managing rAAAs using an endovascular approach. The creation of an endovascular ruptured aneurysm protocol requires several key requisites for success (Table 1). If a provider is practicing in a hospital that performs only a few of these procedures per year, that provider should be cautious in applying endovascular techniques for the management of rAAAs except in extremely permissive circumstances. In addition, these procedures must be done in an environment where the default operative pathway is conversion to a traditional open procedure. Therefore, a traditional operating room (OR) with endovascular capability or a hybrid endovascular/OR suite remains the best options.

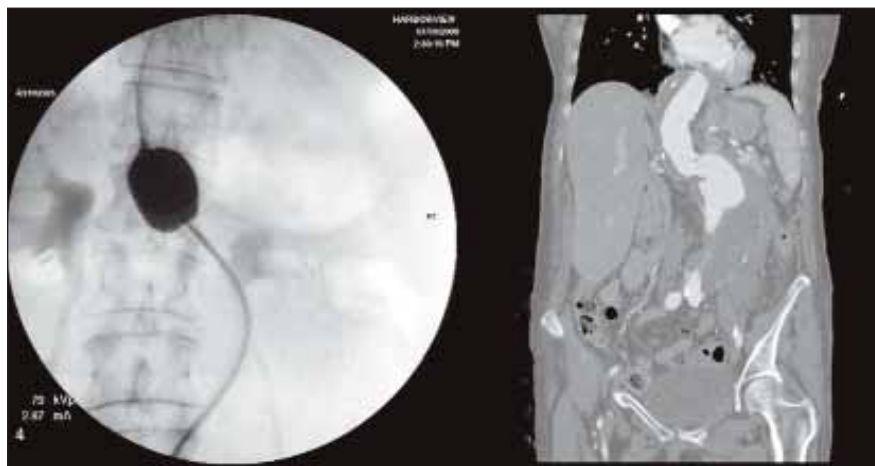


Figure 2. Aortic occlusion balloon for rAAA in a patient unsuitable for endovascular repair.

Institutional requirements include the infrastructure to admit patients with rAAAs into an OR quickly. This requires an emergency department (ED) that can rapidly assess and appropriately resuscitate patients and perform CTA when needed within minutes. Also required are quick turn-around times for transferring a patient from the ED into the OR. This often requires repeated rehearsal on the part of the ED staff, radiology and angiography staff, and OR personnel. Key personnel familiar with endovascular techniques need to be available around the clock. At Harborview, a “rupture room” is maintained after hours and on weekends and is reserved only for incoming patients with ruptured aneurysms. This room has a C-arm, power injector, imaging table, and endovascular inventory in the room and ready for use.

One of the advantages of an “all-endo” approach is the ability to sneak into the aorta with the patient awake and place an aortic occlusion balloon above the renal arteries using solely percutaneous techniques (Figure 2). This can be done under local anesthesia (and often no anesthesia) and helps maintain the patient’s physiologic state (permissive hypotension). Once the aortic occlusion balloon is in place, the anesthesiology team can then choose a method of anesthesia with an emphasis on keeping the patient awake. We have elected to keep patients awake

during EVAR procedures for rAAA using local anesthesia with sedation only. Morbidly obese patients present challenges with conventional imaging, and it has been our practice to electively intubate these patients once an aortic occlusion balloon has been placed.

### ASSEMBLING THE STAFF

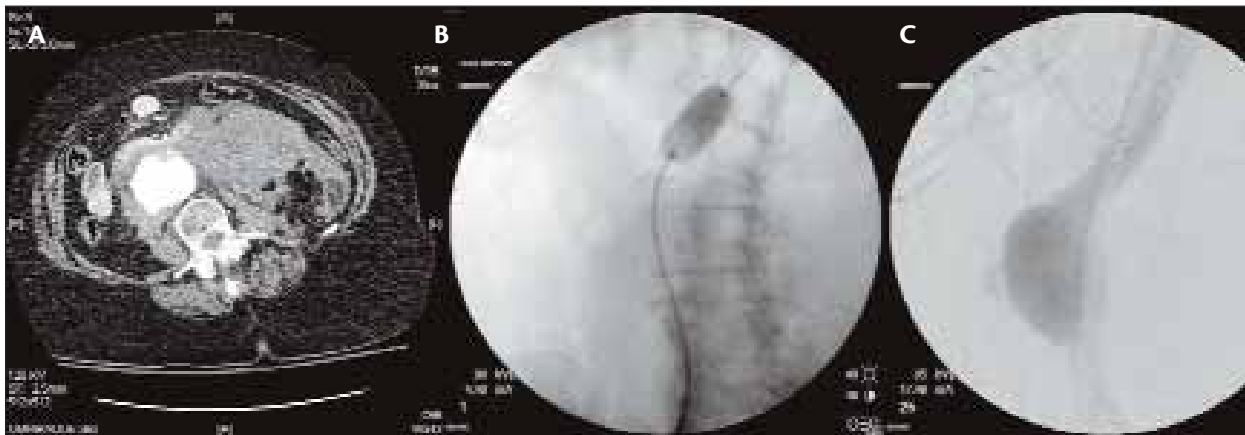
A fully trained staff is essential for a successful endovascular rAAA program. One of the biggest obstacles to establishing a rAAA program is disrupting the status quo and changing

the mindset of providers who care for patients with rAAAs. Different specialties are defined by different “comfort zones.” In managing rAAAs, the comfort zone of a surgeon is to be in an OR and the comfort zone for an anesthesia provider is to have a patient intubated and under general anesthesia. It only takes a few successful cases to convince an anesthesiologist that keeping a patient with a blood pressure of 80 mm Hg hypotensive and awake for rAAA repair can be life-saving. Our anesthesiologists have moved toward being very gentle with administering sedatives during insertion of the Foley catheter and placement of IVs, central lines, and an arterial line. The unfortunate tendency when a patient becomes a little agitated is to reach for whatever anesthetic agent is handy and plow the patient with sedatives. This is exactly what not to do because the patient loses all protective measures, including abdominal wall muscular tone and may become rapidly hypotensive, necessitating urgent intubation and sometimes a rush to convert to open repair (the comfort zone of the nervous endovascular surgeon). Gentle application of anesthetics only until the aortic occlusion balloon is in place is all that is required.

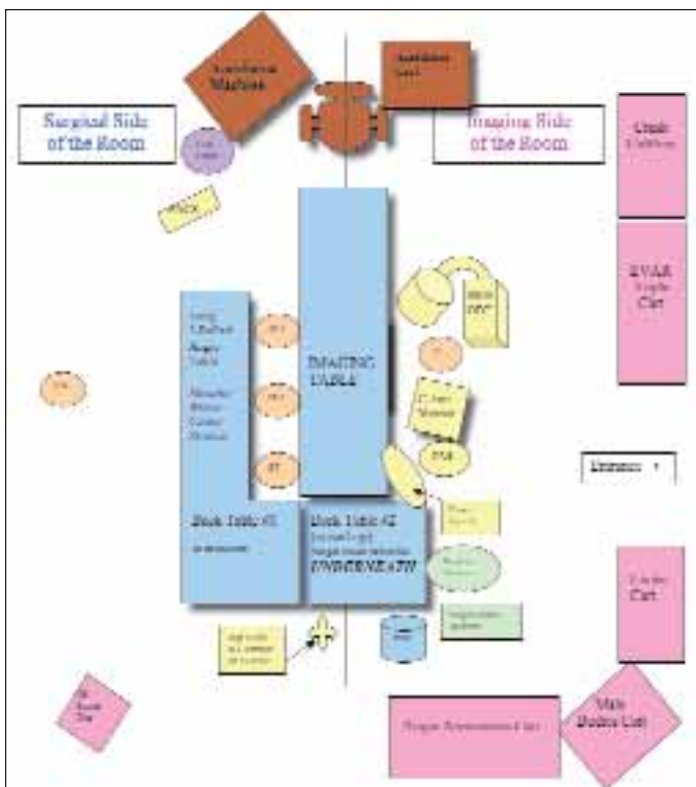
A full complement of endovascular skills is paramount for managing these patients. If certain staff members are uncomfortable with an endovascular approach, those who are comfortable should be immediately available if the patient is a candidate for endovascular repair. These procedures must be done rapidly. It is the author’s opinion that if it normally takes a provider more than 1 hour to perform a standard EVAR under elective conditions, that provider should not be managing patients with rAAAs. One of the most time-consuming aspects of any EVAR can be cannulation of the contralateral gate with a guidewire. Preoperative selection of the graft components and delivery site to best

**TABLE 1. REQUIREMENTS FOR A SUCCESSFUL ENDOVASCULAR rAAA PROGRAM**

• Infrastructure	• Imaging equipment
• Appropriate staffing	• Endovascular inventory
• Anesthesia provider “buy-in”	• Endovascular skill set
	• Expert postoperative care



**Figure 3.** Successful endovascular repair of a ruptured infrarenal aortic aneurysm in an 82-year-old woman awake under local anesthesia. Axial CT image of the large ruptured aneurysm (A). Remote aortic balloon occlusion (B). Aortic stent graft in position before deployment; the aortic balloon has been removed. Note the active extravasation of contrast along the anterior wall of the aneurysm (C).



**Figure 4. The rupture room setup.**

allow for rapid gate cannulation will potentially lead to improved outcomes. A protocol should be considered so that in a rAAA setting, if it takes more than 10 minutes to cannulate the contralateral gate, consideration must be given to converting to an aorto-uni-iliac construct. Prolonged EVAR times and gate cannulation times may ulti-

mately directly correlate with the onset of abdominal compartment syndrome and lead to an increase in subsequent morbidity and mortality. Figure 3 demonstrates a successful repair of an rAAA in which the graft was implanted within 27 minutes of access. Optional and potentially more advantageous approaches to patients with rAAAs involve the use of suture-mediated closure devices for closure of large-bore sheath sites, which saves both time and the potential morbidity for bilateral groin incisions.<sup>3</sup>

## IMAGING SELECTION

Many modern hospitals have built hybrid ORs and modern imaging suites into their existing ORs. If this room is empty when an rAAA case arrives, the patient will ultimately benefit. However, this scenario is not often realistic, and the default in an emergency situation is to use portable imaging and an imaging table in whatever room is available at the time. In the not-too-distant future, flat-panel rotational detectors and portable C-arms with superb imaging will be available for managing rAAAs. Intravascular ultrasound is an incredibly useful tool for intraoperative imaging and sizing if the patient did not have a CTA before presentation. A power injector is crucial for appropriate imaging of the aorta using standard flush aortography. The only factor that is different from standard equipment available for elective EVAR is blood preservation and suction equipment. At Harborview, the Cell-Saver (Haemonetic Corp., Braintree, MA) and Stryker Neptune suction machines (Stryker Corp., Kalamazoo, MI) are maintained in

the rupture room. If at any time a procedure needs to be converted or a decompressive laparotomy needs to be done at the end of the procedure, these machines are critical for preservation and proper blood collection. Our standard rupture room setup is depicted in Figure 4.

## INVENTORY

Placing the properly sized graft into the patient requires a full complement of inventory (Figure 5). Also required is a stock of common catheters, guidewires, and sheaths just as for standard elective EVAR procedures. This inventory should be kept as simple as possible. At Harborview, we have separated the equipment required for an aortic occlusion balloon set for rapid opening at the beginning of the procedure (Table 2). Whatever graft is utilized, once the sizing measurements have been made, whether intraoperatively or in the ED when the patient arrives from an outside hospital with a CTA on transferable electronic media, the graft components should be chosen, opened, and flushed for immediate delivery when needed. In the most common scenario at Harborview, the grafts are opened and prepared before the patient is prepped.

## POSTOPERATIVE CARE

Patients with ruptured aneurysms have unique physiologic conditions and require a tailored approach to

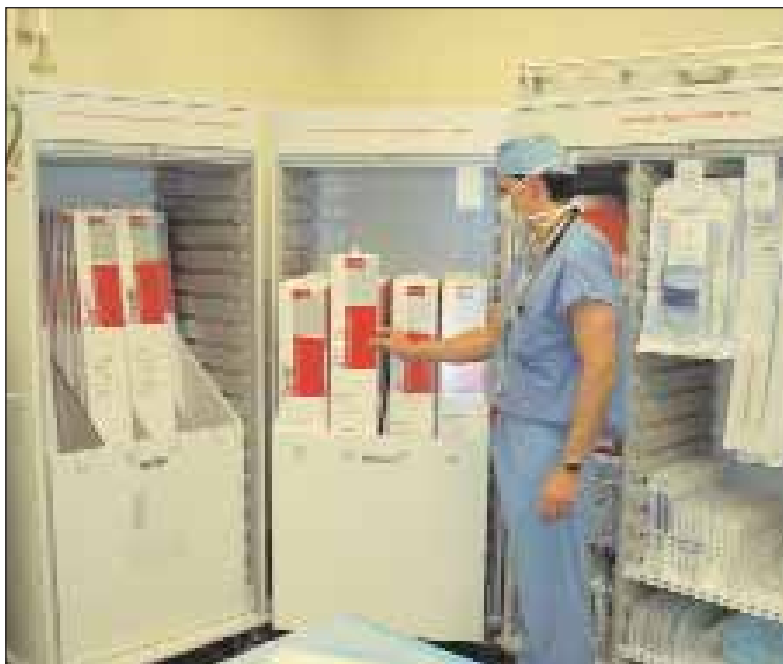

Figure 5. Endovascular inventory.

postoperative management. Surgeons realize that success is not defined only by a successful operation but by the comprehensive management of the patient before, during, and mostly after the operation. Expert intensive care unit management is essential for establishing a successful endovascular rAAA program, and implementation of that program requires a multitude of factors for ultimate success.

## CONCLUSION

Creating a seamless endovascular rAAA program can be challenging but will most assuredly have an impact on mortality versus historical institutional controls undergoing open repair. As technology improves, hopefully so will mortality rates for this deadly condition. ■

*Benjamin W. Starnes, MD, FACS, is Chief, Division of Vascular Surgery, University of Washington, and Chief, Vascular and Endovascular Surgery, Harborview Medical Center, in Seattle, Washington. He has disclosed that he is a paid consultant to Abbott Vascular. Dr. Starnes may be reached at starnes@u.washington.edu. (206) 731-3370.*

TABLE 2. COMPONENTS OF AN AORTIC OCCLUSION BALLOON SET

- Access needle
- .035-inch, 150-cm Bentson starter wire (Cook Medical, Bloomington, IN)
- 45-cm, 12-F sheath (Cook Medical)
- 32-mm Coda Balloon Catheter (Cook Medical)
- .035-inch, 260-cm Amplatz wire (Cook Medical)
- Contrast 50-mL bottle
- 65-cm Kumpe catheter (Cook Medical)
- 30-mL syringe
- Three-way stopcock
- 10-F Prostar device (optional) (Abbott Vascular, Santa Clara, CA)

1. EVAR trial participants. Endovascular aneurysm repair versus open repair in patients with abdominal aortic aneurysm (EVAR trial 1): randomized controlled trial. *Lancet*. 2005;365:2179-2186.
2. Mehta M, Taggart J, Darling RC III, et al. Establishing a protocol for endovascular treatment of ruptured abdominal aortic aneurysms: outcomes of a prospective analysis. *J Vasc Surg*. 2006;44:1-8.
3. Starnes BW, Andersen CA, Ronsivalle JA, et al. Totally percutaneous aortic aneurysm repair: experience and prudence. *J Vasc Surg*. 2006;43:270-276.