

# Plaque Excision and Stent Graft Deployment for SFA Occlusion

A case report on this combination therapy.

BY JOHN PAUL RUNYON, MD

**M**anagement of superficial femoral artery (SFA) occlusive disease remains one of the great challenges for peripheral endovascular therapy. Failure of percutaneous balloon angioplasty as a result of residual luminal narrowing or dissection is a frequent occurrence, especially in patients with calcified lesions, long stenoses, or occlusions.<sup>1</sup> The implantation of nitinol stents for treatment of vascular recoil and dissection may be complicated by stent fracture and intimal hyperplasia.<sup>2</sup> The concomitant treatment of plaque burden, calcification, and thrombus must also be addressed in the treatment of long SFA occlusions.

We describe a case report of the combined use of SilverHawk (FoxHollow Technologies, Menlo Park, CA) plaque excision and Viabahn (Gore & Associates, Flagstaff, AZ) stent graft therapy for the treatment of long SFA occlusive disease.

## CASE REPORT

A 62-year-old man with diabetes, hypertension, hypercholesterolemia, and coronary artery disease presented with Rutherford-Becker category 3 claudication. On examination, his femoral pulses were normal. The posterior tibial and dorsalis pedis pulses could be obtained only by Doppler examination. Lower-extremity arterial duplex evaluation demonstrated bilateral SFA occlusions. The right ankle-brachial index (ABI) was 0.71; the left ABI was 0.81.

Arterial access was achieved via the right common femoral artery. Contralateral access was achieved using a 7-F Destination sheath (Terumo Medical Corporation, Somerset, NJ). Diagnostic angiography confirmed bilateral SFA occlusions, which on the left occurred approximately 1 cm distal to the ostium (Figure 1A). The left SFA was reconstituted at Hunter's canal (Figure 1B).

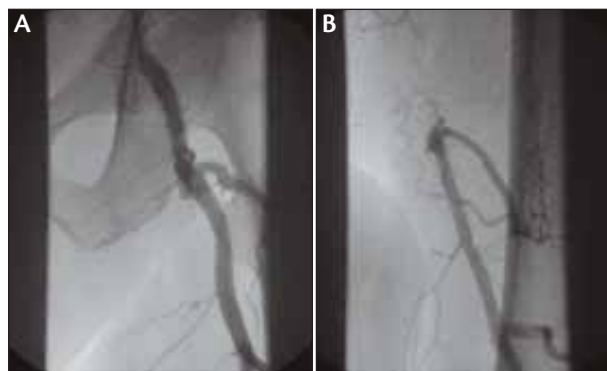
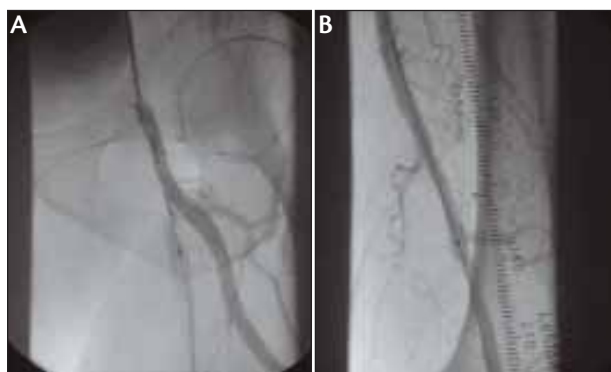

Figure 1. Angiography showing proximal SFA occlusion (A) and distal reconstitution of the SFA (B).

Anticoagulation was achieved using 80 U/kg of heparin. The combination of a stiff angled Glidewire (Terumo Medical Corporation) and a 5-F, nontapered angled Glidecath (Terumo Medical Corporation) was used to cross the total occlusion. A .014-inch Grand Slam guidewire (Abbott Vascular, Redwood City, CA) was then exchanged through the Glidecath and advanced into the popliteal artery.

Plaque excision was performed using the SilverHawk LS-F plaque excision catheter from the proximal occlusion (Figure 2A) to the distal re-entry site and was then followed by balloon angioplasty using a 7-mm X 60-mm Sterling balloon catheter (Boston Scientific Corporation, Natick, MA). The 7-F Destination sheath was exchanged for a 9-F Ring sheath (Cook Incorporated, Bloomington, IN) over a .035-inch, 260-cm, stiff angled Glidewire placed in the popliteal artery. An 8-mm X 15-cm Viabahn stent graft was deployed in the SFA at the distal reconstitution site (Figure 2B). A second 8-mm X 15-cm Viabahn stent graft was placed in an overlapping fashion and



**Figure 2.** Image showing ostial SFA plaque excision with the SilverHawk LS-F plaque excision catheter (A) and distal Viabahn stent graft placement (B).

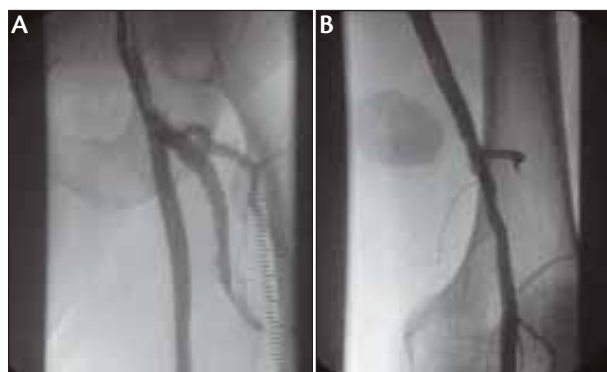
extended to the proximal landing zone. Finally, an 8-mm X 80-mm Powerflex P3 balloon catheter (Cordis Corporation, a Johnson & Johnson company, Miami, FL) was used to post-dilate the stent grafts to 10 atm yielding an excellent angiographic result (Figure 3A, B). Images of the tibial arteries showed no change from the initial diagnostic angiogram. Postprocedure ABI was 1.0, with no elevated velocities throughout the stent graft.

## DISCUSSION

The combination of SilverHawk plaque excision and Viabahn stent grafts addresses many complex issues in treating SFA occlusive disease (Table 1). For example, arterial inflow must be optimized before placement of Viabahn stent grafts. Common femoral artery and ostial SFA disease, as well as lesions involving flexion points, can be treated with plaque excision prior to Viabahn stent graft deployment.<sup>3</sup> SilverHawk plaque excision can also be used to improve arterial outflow in treating popliteal and tibial vessels. Postprocedural arterial runoff has been cited as a predictor of long-term patency,<sup>4</sup> although some reports have been conflicting. Although Fischer et al<sup>5</sup> found lower patency rates after 0- to 1-vessel runoff after Viabahn stent graft deployment, Bray et al<sup>6</sup> found numerically better primary and secondary patency rates after <2-vessel runoff compared to vessels with 2- to 3-vessel runoff. These differences, however, were not statistically

**TABLE 1. ISSUES ADDRESSED BY PLAQUE EXCISION**

- Debulks large plaque burden
- Maximizes stent graft expansion for even deployment
- Optimizes stent graft-to-vessel diameter sizing
- Treats ostial SFA lesions
- Debulks re-entry site
- Treats common femoral artery disease
- Treats outflow disease (popliteal and tibial vessels)



**Figure 3.** Final angiography after plaque excision and Viabahn stent graft placement in the proximal SFA (A) and distal SFA (B).

significant. Hartung et al<sup>7</sup> also recently evaluated the importance of runoff in patients treated with Viabahn stent grafts. They observed that poor runoff was not a contraindication to Viabahn stent grafting because the majority of outflow lesions are improved at the time of intervention. The weight of evidence from the literature supports adequacy of runoff as a predictor of long-term patency. Therefore, runoff should be evaluated before stent graft placement, and improvement of runoff with endovascular techniques should be considered after placement of Viabahn stent grafts in the therapy of long SFA occlusions.

Inadequate and/or incomplete expansion of the Viabahn stent graft after deployment is associated with poor long-term patency. Debulking of plaque burden in SFA occlusions allows for optimal sizing of the Viabahn stent graft. Thus, plaque excision with adjunctive balloon angioplasty offers optimal stent graft-to-vessel diameter sizing prior to stent graft deployment.

The technique of Viabahn stent graft deployment also contributes to long-term patency. The goal for placement of the Viabahn stent graft is to cover as much of the diseased SFA as possible. A “normal SFA segment” to “normal SFA segment” deployment technique decreases the chance of subsequent stenotic lesion forming at the ends of the stent graft. Postdilatation should also be performed only within the confines of the Viabahn stent graft to minimize extra-graft endoluminal injury. The magnitude of intimal hyperplasia has been correlated with the degree of vessel wall injury at the time of intervention.

The technique of placing the Viabahn stent graft from “normal to normal” SFA at times may jeopardize collateral vessels, as demonstrated by Saxon et al.<sup>8</sup> However, this technique has not led to any adverse clinical sequelae, even in patients who have developed acute thrombosis of their stent graft. Nevertheless, the consequences of acute ischemia—should collateral vessels be compromised by

Viabahn stent graft deployment—must be considered at the time of the procedure.

The results of treatment of long SFA occlusions with Viabahn stent grafting have been encouraging. Kedora et al<sup>9</sup> recently reported a randomized comparison of percutaneous Viabahn stent grafting versus prosthetic femoral-popliteal bypass in treating SFA occlusive disease. They observed Viabahn stent grafting to be comparable to surgical revascularization with conventional femoral to above-the-knee bypass using prosthetic grafting. The 12-month primary patency after Viabahn stent grafting was 73.5% versus 74.2% in the femoral-popliteal surgical group. Weighted mean patency rate for clinical series of SFA occlusions treated with Viabahn stent grafting demonstrates a 1-year primary patency of 70% and a 2-year primary patency rate of 67%.

## CONCLUSION

The pairing of SilverHawk plaque excision and Viabahn stent grafting is a promising combination for the treatment of SFA occlusive disease. Plaque excision may solve many challenges in the treatment of SFA occlusive disease. The Viabahn stent graft provides a flexible, fracture-resistant stent that serves as a “SFA endoluminal bypass graft.”

Ongoing clinical trials, such as VIBRANT, which studies the Viabahn versus bare nitinol stents, will better elucidate the roles of bare nitinol stents and Viabahn covered stent grafts in treating SFA disease. The role of plaque debulking before bare metal nitinol stenting or Viabahn covered stent graft therapy for SFA occlusive disease also awaits definitive evaluation by randomized controlled trials. ■

*John Paul Runyon, MD, is Clinical Director for Peripheral Vascular Intervention at Ohio Heart and Vascular Center, the Christ Hospital in Cincinnati, Ohio. He has disclosed that he is on the FoxHollow Medical Advisory Board. Dr. Runyon may be reached at (513) 721-8881; runyonj@ohioheart.org.*

1. Jeans WD, Armstrong S, Cole SEA, et al. Fate of patients undergoing transluminal angioplasty for lower-limb ischemia. *Radiology*. 1990;177:559-564.
2. Schlager O, Dick P, Sabeti S, et al. Long-segment SFA stenting—the dark sides: in-stent restenosis, clinical deterioration and stent fractures. *J Endovasc Ther*. 2005;12:676-684.
3. Rubin BG. Plaque excision in the treatment of peripheral arterial disease. *Perspect Vasc Surg Endovascular Ther*. 2006;18:47-53.
4. Hunink MG, Wong JB, Donaldson MC, et al. Patency results of percutaneous and surgical revascularization for femoropopliteal arterial disease. *Med Decis Making*. 1994;14:71-81.
5. Fischer M, Schwabe L, Schulte KL. Value of one Hemobahn/Viabahn endoprosthesis in the treatment of long chronic lesions of the superficial femoral artery: 6 years of experience. *J Endovasc Ther*. 2006;13:281-290.
6. Bray PJ, Robson WJ, Bray AE. Percutaneous treatment of long superficial femoral artery occlusive disease: efficacy of the Hemobahn stent graft. *J Endovasc Ther*. 2003;10:619-628.
7. Hartung O, Ötör A, Dubuc M, et al. Efficacy of Hemobahn in the treatment of superficial femoral artery lesions in patients with acute or critical ischemia: a comparative study with claudicants. *Eur J Vasc Endovasc Surg*. 2005;30:300-306.
8. Saxon RR, Coffman JM, Gooding JM, et al. Endograft use in the femoral and popliteal arteries. *Tech Vasc Interv Radiol*. 2004;7:6-15.
9. Kedora J, Hohmann S, Garrett W, et al. Randomized comparison of percutaneous Viabahn stent grafts vs prosthetic femoral popliteal bypass in the treatment of superficial femoral arterial occlusive disease. *J Vasc Surg*. 2007;45:10-16.