

Using Covered Stents in the Carotid Arteries

An overview of the potential uses for covered stents in this anatomy, including a review of the literature and procedural considerations.

BY DAVID L. DAWSON, MD

Although the FDA has approved several bare-metal, self-expanding stents to treat carotid stenoses, no covered stents have been specifically evaluated or approved for carotid or cerebrovascular applications (Table 1). Nonetheless, there are a number of potentially useful applications for covered stents in the brachiocephalic, carotid, and even intracranial arteries.

As with currently accepted applications for bare-metal carotid stents, the use of covered stents in carotid arteries is reserved for patients who are at high risk for complications with open surgical management of their specific problem. Similarly, patients may be considered high risk due to anatomic factors (such as cervical wounds, infections, tracheostomy, and inaccessible lesion location) or physiologic factors (cardiac, pulmonary, or other systemic disease).

The list of potential uses for covered stents in carotid arteries is similar to covered stent applications in other vessels, including management of traumatic injury, aneurysm, pseudoaneurysm, dissection, and in-stent restenosis.

TRAUMA

Endovascular therapies can be used to manage traumatic vascular injuries in the neck. Blunt or penetrating cervical trauma or skull base fracture may injure the carotid artery, resulting in acute pseudoaneurysm, hemorrhage, or arteriovenous fistula. As with the femoral

artery in the groin, iatrogenic injury is a common cause of carotid artery injuries in the neck. Inadvertent arterial puncture or cannulation with a large-bore sheath can result in hematoma, pseudoaneurysm, or arteriovenous fistula formation. Endovascular treatment options, in addition to covered stent placement, can include vessel occlusion with detachable balloons, glue or coil embolization of false aneurysms, bare-metal stents for dissections, and other techniques.¹⁻¹⁰

The option of surgical repair may still be best for penetrating zone II neck injuries. Between the clavicular heads and the angle of the mandible, vascular structures are easily exposed, and direct repair is usually straightforward. Concomitant injuries to the aerodigestive tract can be repaired and drained, if needed. Exposure and control of proximal or distal injuries may be more complicated, and imaging studies, such as CT or contrast arteriography, are used in stable patients to evaluate for vascular injury. Endovascular repair with covered stents may offer advantages over open repair of zone I or III neck injuries because exposure for proximal and distal vascular clamping may be difficult or hazardous.

The best choice for management of carotid artery dissections from blunt trauma is controversial. Reports from large level I trauma centers support the role for early detection and anticoagulation for blunt carotid artery injuries.^{11,12} In a series of six patients with covered stents placed for internal carotid dissections (both spontaneous and posttraumatic), Assadian et al

TABLE 1. COMMERCIALY PRODUCED COVERED STENTS CURRENTLY AVAILABLE IN THE US WITH POTENTIAL OFF-LABEL APPLICATIONS MANAGING CAROTID ARTERY PATHOLOGY

| Covered Stent | Manufacturer | Approved Indications | Stent Design | Stent Material | Covering Material | Sheath Size Required (F) | Guide Catheter Required (F) | Guidewire Size (inch) | Available Diameters or Expansion Range (mm) | Available Lengths (mm) |
|----------------------|--------------------------|--|--------------|----------------------|-------------------|--------------------------|-----------------------------|-----------------------|---|------------------------|
| Fluency Plus | Bard Peripheral Vascular | Tracheobronchial | SE* | Nitinol† | ePTFE‡ | 8, 9 | | .035 | 6-10 | 40, 60, 80 |
| Jostent Graft-Master | Abbott Vascular | Coronary or saphenous graft perforation | BE§ | Stainless steel 316L | ePTFE | | 7 | .014 | 3-5 | 12, 16, 19, 26 |
| iCast | Atrium Medical | Tracheobronchial | BE | Stainless steel 316L | ePTFE | 6, 7 | | .035 | 5-12 | 16, 22, 38, 59 |
| Viabahn | Gore & Associates | Superficial femoral artery, tracheobronchial | SE | Nitinol | ePTFE | 8-12 | | .025, .035 | 5-10, 11, 13 | 25, 50, 100, 150 |
| Wallgraft | Boston Scientific | Tracheobronchial | SE | Elgiloy** | PET†† | 9-12 | | .035 | 6-10, 12, 14 | 20, 30, 50, 70 |

* SE: self-expanding

† Nitinol: nickel/titanium alloy

‡ ePTFE: expanded polytetrafluoroethylene

§ BE: balloon-expandable

** Elgiloy: nonferromagnetic alloy composed of cobalt, chromium, nickel, and molybdenum

†† PET: polyethylene terephthalate

reported no late complications out to 6 months, although one patient had a periprocedural transient ischemic attack.¹³ In their report and literature review that included 20 patients treated with covered stents for traumatic extracranial internal carotid artery pseudoaneurysms due to penetrating craniocervical injuries or skull base fractures, Maras et al reported a 15% occlusion rate during follow-up, which they considered acceptable due to the complexity of the injuries.⁵ In a larger series, 46 neurologically stable patients with blunt carotid artery injury seen at a level I trauma center over a 9-year period (characterized as dissections and traumatic pseudoaneurysms), half were treated with stents, and half were treated with anticoagulation (if not otherwise contraindicated).¹⁴ There were four complications in 23 patients undergoing carotid stent placement: three strokes and one subclavian dissection. Based on follow-up angiography in 38 patients (18 patients with stents who received antithrombotic agents, 20 patients who received antithrombotic agents alone), Cothren et al concluded that antithrombotic therapy remains the recommended therapy for most blunt carotid artery injuries because carotid stents placed for blunt trauma-induced carotid pseudoaneurysms had a 21% compli-

cation rate and an observed occlusion rate of 45%. In contrast, patients treated with antithrombotic agents alone had an occlusion rate of 5%; asymptomatic patients treated with antithrombotic agents did not have strokes.

TRUE ANEURYSMS

True aneurysms of the extracranial carotid arteries are very uncommon. The few case reports of true aneurysm treatment with covered stents suggest efficacy and safety.¹⁵⁻²⁰ Covered stents have been used to treat common carotid artery²¹ and internal carotid artery aneurysm²² associated with Behçet's disease, an uncommon vasculitis sometimes associated with aneurysm formation.

INTRACEREBRAL PATHOLOGIES

Neurointerventionists have used a variety of covered stents to treat intracranial aneurysms and arteriovenous fistulae with generally favorable results.^{7,23-32}

PSEUDOANEURYSMS

Most of the experience with covered stent use in the cervical portion of the carotid arteries has come from the treatment of nontraumatic pseudoaneurysms. Pseudo-



Figure 1. An example of a self-expanding covered stent, the Symbotec ePTFE covered nitinol stent available in Europe (Boston Scientific Corporation, Natick, MA).

aneurysms can develop as a consequence of infection, malignancy, radiation, endovascular therapy, or carotid surgery.

Presentations of carotid artery pseudoaneurysms can vary, but they often warrant immediate attention when they are a complication of a treatment of cancer or infection. A sentinel bleed in a patient with head and neck malignancies after surgical or radiation treatment of these tumors implies risk for acute carotid artery blowout, a vascular emergency. Endovascular occlusion of the carotid artery with detachable balloons is an option for management of carotid blowout, but it is a poor choice for patients with insufficient collateral to avoid ischemic stroke. Several investigators have reported successful short-term management with covered stents,³³⁻³⁷ although complications of stent occlusion, vessel erosion and stent extrusion, and septic thromboembolism with brain abscess were seen.

Similarly, covered stent placement may be used in the setting of hemorrhage from a tracheoinnominate fistula complicating tracheostomy, but infection or secondary erosion of the trachea by the stent may occur.³⁸

Patients who develop carotid artery complications

after treatment of malignancies may have open wounds, pharyngocutaneous fistulae, or similar situations that result in bacterial contamination. Pseudoaneurysms in these settings likely represent a complication of an infection of the artery or periarterial tissue. Even though use of a covered stent might be risky in these situations, urgent operation in the setting of a hostile neck or in an acutely ill patient might be worse. The risk of implant infection is high, but use of a covered stent may be considered as an acceptable temporizing maneuver, a means to prevent catastrophic bleeding long enough to stabilize a patient for later definitive surgical management.

Given the risk of infection in these potentially infected sites, empiric long-term antibiotic administration may be reasonable.^{33,35,37,39} Use of a vein-covered stent may also potentially reduce the late risk of prosthetic infection.⁴⁰ Later operation may be needed to resect, replace, or bypass the arterial segment if an implant becomes infected, although the short life expectancy of many of the patients with advanced cancer who develop a carotid blowout may mean that endovascular therapy provides a suitable solution to their acute problem. Covered stents may also be advantageous when a pseudoaneurysm is not surgically accessible with standard techniques (eg, in the petrous segment for which polytetrafluoroethylene [PTFE]-covered stent placement has been reported for managing a pseudoaneurysm that developed after recurrent middle ear infections) (Figure 1).⁴¹

Other endovascular approaches for the management of carotid pseudoaneurysm in patients with threatened carotid blowout include coil embolization or injection of acrylic glue, and direct puncture with instillation of glue has been used to obliterate continued pseudoaneurysm flow after covered stent placement.^{34,42} Published data on these approaches are anecdotal.

Pseudoaneurysm formation can also be a late complication of carotid artery stenting for a radiation-induced stenosis. Operative repair in this setting could be challenging due to postradiation fibrosis. Successful use of a covered stent for reintervention in such a case has been reported.⁴³

Reported experiences with use of covered stents for carotid pseudoaneurysms that formed as late complications after prior carotid artery surgery suggest, as might be expected, less risk of stent infection.^{39,44,45} False aneurysms in this setting may result from late disruption of a suture line, which does not necessarily involve infection (Figure 2). Reoperation may be considered, but for the high-risk patient, a covered stent may offer a nonsurgical option to prevent further growth and potential rupture of the false aneurysm. This may become the treat-

ment of choice in the physiologically compromised patient or when the anatomy precludes direct surgical access with adequate proximal and distal control.

The endovascular approach may be advantageous if surgical access to the pseudoaneurysm is difficult because of its very low or high location in the neck (Figures 3 and 4). Still, the long-term durability of covered stents in such applications is unknown. Periprocedural and late complications of stent thrombosis and thromboembolic stroke have been reported,⁴⁶ so covered stent use for management of carotid pseudoaneurysms, even in the absence of infection, should be considered to be a high-risk intervention, offered only after consideration of alternative surgical approaches.

RESTENOSIS

The use of covered stents to treat restenosis after carotid artery stenting is an option, but angioplasty or use of a second bare-metal stent remain more common strategies. Outcomes with covered stent treatment of stenosis after carotid artery stenosis for atherosclerotic disease have not been reported in the literature.

“The use of covered stents to treat restenosis after carotid artery stenting is an option, but angioplasty or use of a second bare-metal stent remain more common strategies.”

TECHNICAL CONSIDERATIONS

No commercially available covered stent is FDA-approved for carotid artery applications, but use of several different devices has been reported in the literature. Except, perhaps, when a very short stent will suffice, balloon-expandable covered stents should be used with caution in mobile segments because balloon-expandable stents may be permanently deformed by compression or kinking due to movement. Use of more flexible self-expanding stent designs has been favored.

Descriptions of “homemade” covered stents for carotid applications have included PTFE or saphenous vein segments sutured to balloon-expandable Palmaz stents or attached to nitinol stents.⁴⁷ Vein stent grafts may be less likely to become infected, but they are cumbersome to construct and challenging to deliver. With the variety of PTFE-covered, balloon-expandable, and self-expanding stents now commercially available, the homemade versions are essentially obsolete, except perhaps for use in a potentially infected site.

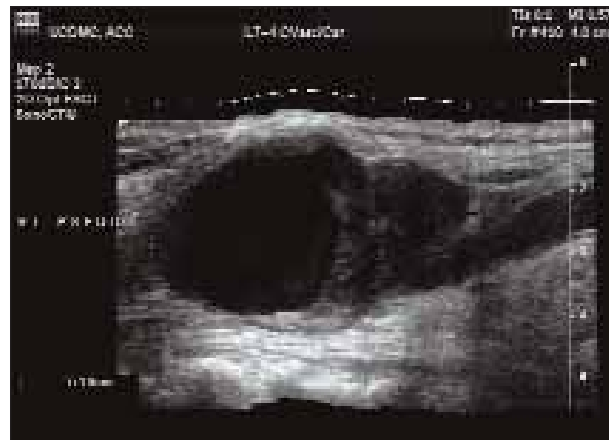


Figure 2. Duplex ultrasound evaluation of a pseudoaneurysm of the carotid artery 9 months after carotid endarterectomy with Dacron patch closure.

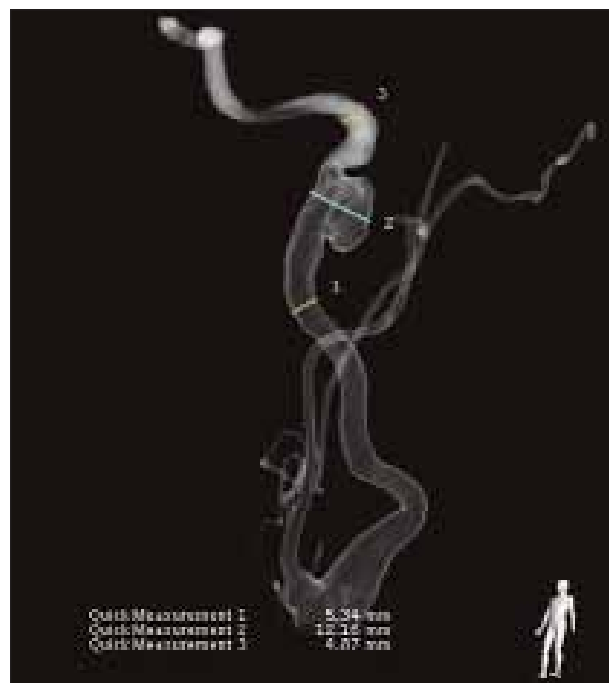
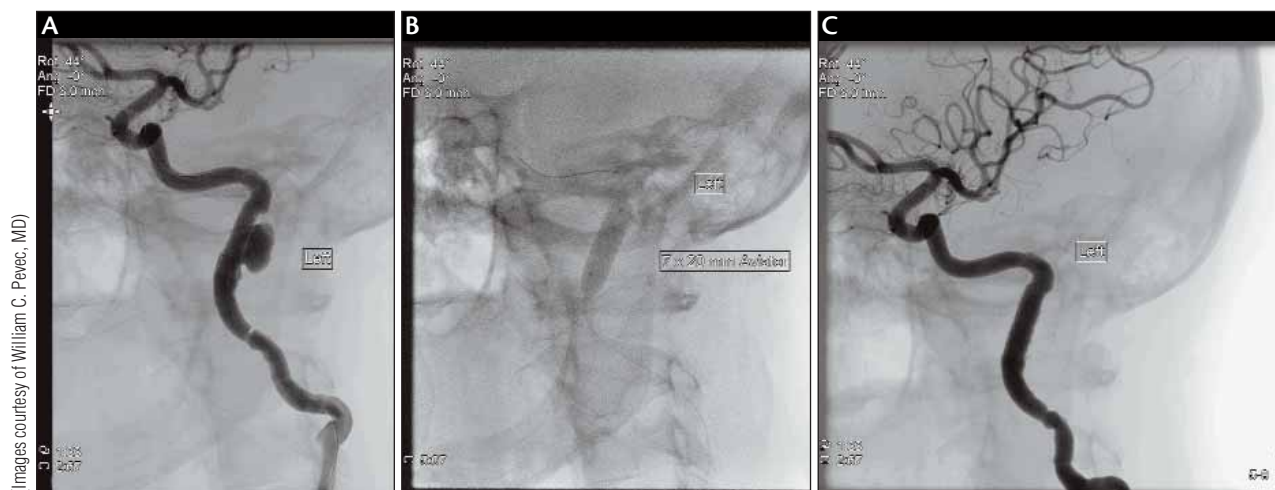


Figure 3. Three-dimensional rotational angiography volume rendered image of a posttraumatic pseudoaneurysm of the internal carotid artery at the base of the skull. The imaging modality offers means for precise measurement, facilitating procedural planning.

Devices are most frequently delivered from femoral arterial access using long sheaths. Covered stents that can be used in extracranial carotid arteries include designs compatible with delivery over .035-inch, .018-inch, and .014-inch guidewires. Distal embolic protection is not generally thought to be necessary because most carotid lesions treated with covered stents have less embolic



(Images courtesy of William C. Pevec, MD)

Figure 4. Internal carotid artery pseudoaneurysm before (A), during (B), and after (C) deployment of a balloon-expandable 6-mm x 22-mm ePTFE covered stent (iCast). The patient was a 53-year-old woman who presented with neck pain but no other neurologic symptoms 6 months after a minor fall.

potential than carotid bifurcation atherosclerotic lesions, but some reports include descriptions of embolic protection device use in this setting.¹⁹

The proximal common carotid artery may be accessed with a small surgical cutdown if aortic or iliofemoral occlusive disease or challenging arch anatomy make femoral access impractical.⁴⁸ The direct cervical approach (using either general or local anesthesia) also allows for more precise deployment and suture closure of the arterial puncture site, a potential advantage when using large sheaths. If needed, flow in the internal carotid artery can be arrested or reversed with clamping of the common and external carotid arteries.

Selection of appropriately sized covered stents is essential because successful exclusion of aneurysms or pseudoaneurysms requires complete apposition of the stent to the vessel wall proximal and distal to the lesion. Undersized stents may not seal. Use of excessively oversized self-expanding stents may lead to infolding or scalloping of the graft material, which may become a nidus for thrombus formation, leading to thrombosis or thromboembolism. Calibrated measurements from arteriography, use of rotational angiography with three-dimensional reconstructions,⁴⁹ or intravascular ultrasound (IVUS) can be used to make precise measurements of arterial diameters.⁵⁰ IVUS has not been widely used for carotid artery evaluations due to concerns about embolization risk with repeated or prolonged instrumentation of the carotid artery, but the risk is probably low when the vessel is not atherosclerotic. IVUS may be useful after stent deployment, guiding post-deployment balloon dilation to ensure vessel wall apposition by the device.

PHARMACOTHERAPY

No specific data guide the periprocedural or postprocedural drug therapy with covered stent use. Empirically, most interventionists elect long-term combined antiplatelet therapy with aspirin and clopidogrel. Observations of early stent thrombosis occurring without use of antiplatelet and antithrombotic therapies (not used because of specific contraindications) suggest that antiplatelet and antithrombotic therapies are important adjuncts.⁸ Long-term use of vitamin K antagonists (warfarin) is not generally recommended after covered stent placement.

FOLLOW-UP IMAGING

Almost no published information is available on late outcomes with the use of covered stents in the carotid arteries. Given the uncertainty about what to expect, long-term clinical and imaging follow-up should be provided. Some combination of duplex scanning, plain films, and CT angiography should be used at regular intervals to look for late complications such as kinking of the device, stenosis or kinking of the native vessel, thrombus formation, flow around the covered stent (endoleak), strut fracture,⁵¹ or device malpositioning.

CAUTIONS

Caution should be exercised in using covered stents in off-label applications. Use in a contaminated or potentially infected field risks infection of the implant, which can lead to infective arteritis, periarteritis, infectious complications from septic embolic, hematogenous spread of infection, pseudoaneurysm, or hemorrhage. Thrombosis or thromboembolism can cause stroke.

Although published case reports suggest good short- and mid-term results from the use of carotid stents in head and neck sites, there are no long-term data on their durability, especially in cervical locations subject to movement. The possibility of device compromise from strut fracture,⁵¹ compression, stenosis,^{2,52} deformation,^{53,54} kinking, or other mechanical problem should be considered. Therefore, use of covered stents for carotid artery applications should be avoided, if possible, especially in younger patients and those for whom lower-risk surgical treatment are reasonable alternatives. ■

David L. Dawson, MD, is Professor, UC Davis Vascular Center, Division of Vascular and Endovascular Surgery in Sacramento, California. He has disclosed that he is a paid consultant for Gore & Associates, receives grant/research funding from Abbott Vascular, and is a paid consultant for and receives grant/researching funding from Boston Scientific. Dr. Dawson may be reached at (916) 734-8122; david.dawson@ucdmc.ucdavis.edu.

1. Fusonie GE, Edwards JD, Reed AB. Covered stent exclusion of blunt traumatic carotid artery pseudoaneurysm: case report and review of the literature. *Ann Vasc Surg.* 2004;18:376-379.
2. Parodi JC, Schonholz C, Ferreira LM, et al. Endovascular stent-graft treatment of traumatic arterial lesions. *Ann Vasc Surg.* 1999;13:121-129.
3. Ramsay DW, McAuliffe W. Traumatic pseudoaneurysm and high flow arteriovenous fistula involving internal jugular vein and common carotid artery. Treatment with covered stent and embolization. *Australas Radiol.* 2003;47:177-180.
4. ul Haq T, Yaqoob J, Munir K, et al. Endovascular-covered stent treatment of posttraumatic cervical carotid artery pseudoaneurysms. *Australas Radiol.* 2004;48:220-223.
5. Maras D, Lioupi C, Magoufis G, et al. Covered stent-graft treatment of traumatic internal carotid artery pseudoaneurysms: a review. *Cardiovasc Intervent Radiol.* 2006;29:958-968.
6. Duncan IC, Fourie PA. Percutaneous management of concomitant post-traumatic high vertebral and caroticojugular fistulas using balloons, coils, and a covered stent. *J Endovasc Ther.* 2003;10:882-886.
7. Madan A, Mujic A, Daniels K, et al. Traumatic carotid artery-cavernous sinus fistula treated with a covered stent. Report of two cases. *J Neurosurg.* 2006;104:969-973.
8. Redekop G, Martotta T, Weill A. Treatment of traumatic aneurysms and arteriovenous fistulas of the skull base by using endovascular stents. *J Neurosurg.* 2001;95:412-419.
9. Joo JY, Ahn JY, Chung YS, et al. Therapeutic endovascular treatments for traumatic carotid artery injuries. *J Trauma.* 2005;58:1159-1166.
10. Deguchi J, Yamada M, Kobata H, et al. Covered stent treatment for traumatic cervical carotid artery aneurysms—two case reports. *Neurol Med Chir (Tokyo).* 2006;46:24-28.
11. Martin MJ, Mullenix PS, Steele SR, et al. Functional outcome after blunt and penetrating carotid artery injuries: analysis of the National Trauma Data Bank. *J Trauma.* 2005;59:860-864.
12. Cothren CC, Moore EE, Biffi WL, et al. Anticoagulation is the gold standard therapy for blunt carotid injuries to reduce stroke rate. *Arch Surg.* 2004;139:540-545; discussion 545-546.
13. Assadian A, Senekowitsch C, Rotter R, et al. Long-term results of covered stent repair of internal carotid artery dissections. *J Vasc Surg.* 2004;40:484-487.
14. Cothren CC, Moore EE, Ray CE, Jr, et al. Carotid artery stents for blunt cerebrovascular injury: risks exceed benefits. *Arch Surg.* 2005;140:480-485; discussion 485-486.
15. Chan AW, Yadav JS, Krieger D, et al. Endovascular repair of carotid artery aneurysm with Jostent covered stent: initial experience and one-year result. *Catheter Cardiovasc Interv.* 2004;63:15-20.
16. Cil BE, Ucar I, Ozsoy F, et al. Successful endovascular treatment of a left common carotid artery aneurysm following failed surgery of a right common carotid artery aneurysm. *Cardiovasc Intervent Radiol.* 2005;28:367-371.
17. Fischer B, Palkovic S, Wassmann H, et al. Endovascular management of tandem extracranial internal carotid artery aneurysms with a covered stent. *J Endovasc Ther.* 2004;11:739-741.
18. Mukherjee D, Roffi M, Bajzer C, et al. Endovascular treatment of carotid artery aneurysms with covered stents. *Circulation.* 2001;104:2995.
19. Powell RJ, Ruzic EM, Schermerhorn ML. Stent-graft treatment of a large internal carotid artery vein graft aneurysm. *J Vasc Surg.* 2003;37:1310-1313.
20. Ruebben A, Merlo M, Verri A, et al. Exclusion of an internal carotid aneurysm by a covered stent. *J Cardiovasc Surg (Torino).* 1997;38:301-303.
21. Park JH, Chung JW, Joh JH, et al. Aortic and arterial aneurysms in Behçet disease: manage-

- ment with stent-grafts—initial experience. *Radiology.* 2001;220:745-750.
22. Caballol N, Dominguez A, Vidaller A, Martinez-Yelamos S. [Endovascular treatment of carotid and pulmonary aneurysms in Behçet's disease]. *Neurologia.* 2005;20:370-373.
23. Li MH, Gao BL, Wang YL, et al. Management of pseudoaneurysms in the intracranial segment of the internal carotid artery with covered stents specially designed for use in the intracranial vasculature: technical notes. *Neuroradiology.* 2006;48:841-846.
24. Hans FJ, Moller-Hartmann W, Brunn A, et al. Treatment of wide-necked aneurysms with balloon-expandable polyurethane-covered stentgrafts: experience in an animal model. *Acta Neurochir (Wien).* 2005;147:871-876.
25. Blasco J, Macho JM, Burrell M, et al. Endovascular treatment of a giant intracranial aneurysm with a stent-graft. *J Vasc Interv Radiol.* 2004;15:1145-1149.
26. Alifke K, Straube T, Dörner L, et al. Treatment of intracranial broad-neck aneurysms with a new self-expanding stent and coil embolization. *Am J Neuroradiol.* 2004;25:584-591.
27. Naesens R, Mestdagh C, Breemersch M, et al. Direct carotid-cavernous fistula: a case report and review of the literature. *Bull Soc Belge Ophthalmol.* 2006;(299):43-54.
28. Magoufis GL, Vrachliotis TG, Stringaris KA. Covered stents to treat partial recanalization of onyx-occluded giant intracavernous carotid aneurysm. *J Endovasc Ther.* 2004;11:742-746.
29. Ceil G, Engin D, Orhan G, et al. Intractable epistaxis related to cavernous carotid artery pseudoaneurysm: treatment of a case with covered stent. *Auris Nasus Larynx.* 2004;31:275-278.
30. Vanninen RL, Manninen HI, Rinne J. Intracranial iatrogenic carotid pseudoaneurysm: endovascular treatment with a polytetrafluoroethylene-covered stent. *Cardiovasc Intervent Radiol.* 2003;26:298-301.
31. Auyeung KM, Lui WM, Chow LC, et al. Massive epistaxis related to petrous carotid artery pseudoaneurysm after radiation therapy: emergency treatment with covered stent in two cases. *Am J Neuroradiol.* 2003;24:1449-1452.
32. de Souza JM, Domingues FS, Espinosa G, et al. Cavernous carotid artery pseudoaneurysm treated by stenting in acromegalic patient. *Arq Neuropsiquiatr.* 2003;61:459-462.
33. Kim HS, Lee DH, Kim HJ, et al. Life-threatening common carotid artery blowout: rescue treatment with a newly designed self-expanding covered nitinol stent. *Br J Radiol.* 2006;79:226-231.
34. Lesley WS, Chaloupka JC, Weigle JB, et al. Preliminary experience with endovascular reconstruction for the management of carotid blowout syndrome. *Am J Neuroradiol.* 2003;24:975-981.
35. Warren FM, Cohen JL, Nesbit GM, et al. Management of carotid 'blowout' with endovascular stent grafts. *Laryngoscope.* 2002;112:428-433.
36. Hertz JA, Valentino J, Kwolek CJ, et al. Carotid blowout with infection: management with endovascular and open vascular approaches—a case report. *Vasc Endovascular Surg.* 2004;38:477-481.
37. Chang FC, Lirng JF, Tai SK, et al. Brain abscess formation: a delayed complication of carotid blowout syndrome treated by self-expandable stent-graft. *Am J Neuroradiol.* 2006;27:1543-1545.
38. Wall LP, Gasparis A, Criado E. Endovascular therapy for tracheoinnominate artery fistula: a temporizing measure. *Ann Vasc Surg.* 2005;19:99-102.
39. Terramani TT, Workman MJ, Loberman Z, et al. Adjunctive endovascular techniques in the management of postoperative carotid artery pseudoaneurysms—useful armamentarium for vascular surgeons—three case reports. *Vasc Endovascular Surg.* 2003;37:207-212.
40. Martin JB, Bednarkiewicz M, Christenson JT, et al. Endovascular repair using vein-covered stents in the carotid artery bifurcation. *Cardiovasc Surg.* 2000;8:499-502.
41. Alexander MJ, Smith TP, Tucci DL. Treatment of an iatrogenic petrous carotid artery pseudoaneurysm with a Symbiot covered stent: technical case report. *Neurosurgery.* 2002;50:658-662.
42. Roth TC, Chaloupka JC, Putman CM, et al. Percutaneous direct-puncture acrylic embolization of a pseudoaneurysm after failed carotid stenting for the treatment of acute carotid blowout. *AJNR Am J Neuroradiol.* 1998;19:912-916.
43. Bates MC, Alamehmi A. Carotid stenting for symptomatic radiation-induced arteritis complicated by recurrent aneurysm formation. *Catheter Cardiovasc Interv.* 2004;63:507-511.
44. Martin ND, Carabasi RA, Bonn J, et al. Endovascular repair of carotid artery aneurysms following carotid endarterectomy. *Ann Vasc Surg.* 2005;19:913-916.
45. Hertz JA, Minion DJ, Quick RC, et al. Endovascular exclusion of a postendarterectomy carotid pseudoaneurysm. *Ann Vasc Surg.* 2003;17:558-561.
46. McCready RA, Divilbiss JL, Bryant MA, et al. Endoluminal repair of carotid artery pseudoaneurysms: a word of caution. *J Vasc Surg.* 2004;40:1020-1023.
47. Simonato F, Righi C, Melissano G, Rolli A, Chiesa R, Scotti G. Stent-graft treatment of a common carotid artery pseudoaneurysm. *J Endovasc Ther.* 2000;7:136-140.
48. Assadian A, Senekowitsch C, Assadian O, et al. Combined open and endovascular stent grafting of internal carotid artery fibromuscular dysplasia: long term results. *Eur J Vasc Endovasc Surg.* 2005;29:345-349.
49. van den Berg JC, Overtoom TT, de Valois JC, et al. Using three-dimensional rotational angiography for sizing of covered stents. *Am J Roentgenol.* 2002;178:149-152.
50. Reid DB, Diethrich EB, Marx P, et al. Intravascular ultrasound assessment in carotid interventions. *J Endovasc Surg.* 1996;3:203-210.
51. de Vries JP, Meijer RW, van den Berg JC, et al. Stent fracture after endoluminal repair of a carotid artery pseudoaneurysm. *J Endovasc Ther.* 2005;12:612-615.
52. Schillinger M, Dick P, Wiest G, et al. Covered versus bare self-expanding stents for endovascular treatment of carotid artery stenosis: a stopped randomized trial. *J Endovasc Ther.* 2006;13:312-319.
53. Johnson SP, Fujitani RM, Leyendecker JR, et al. Stent deformation and intimal hyperplasia complicating treatment of a post-carotid endarterectomy intimal flap with a Palmaz stent. *J Vasc Surg.* 1997;25:764-768.
54. Schonholz C, Krajcar Z, Carlos Parodi J, et al. Stent-graft treatment of pseudoaneurysms and arteriovenous fistulae in the carotid artery. *Vascular.* 2006;14:123-129.