

# Complications of EVAR

Is endovascular aneurysm repair still worth the trouble?

BY ROBERT S. DIETER, MD, RVT; JEFFREY FREIHAGE, MD; PRANAB DAS, MD; LEONARDO CLAVIJO, MD; SOHAIL IKRAM, MD; KRISHNA MANNAVA, MD; JOHN P. PACANOWSKI JR, MD; ARAVINDA NANJUNDAPPA, MD, RVT; AND THEODORE ANG TAN, MD

The state of endovascular aneurysm repair (EVAR) today is impressive, given its comparatively short history.<sup>1</sup> It is rapidly growing as a preferred treatment option for many patients with aortic aneurysms given its advantages over open surgical repair. The procedural costs of EVAR, including the cost of the endograft, are similar to those of open surgical repair. The cost savings of EVAR can be seen in nonprocedural aspects, such as shorter hospital stays and a lower 30-day mortality rate.<sup>2</sup> Long-term survival is similar for both EVAR and open surgery. EVAR is associated with a higher rate of secondary interventions due to complications when compared with open surgical repair. In a recent study by Becquemin et al involving 260 patients who had undergone EVAR, 22% required secondary intervention on follow-up.<sup>3</sup> Although technological improvements have decreased the need for reintervention for up to 3 years in some studies, patients who have undergone EVAR will still require lifelong graft surveillance for complications. The complications of EVAR can be broadly classified as (1) early complications, which include procedural causes such as iliac perforation and rup-

ture (Figure 1) and those relating to graft insertion, deployment, and placement (Table 1) and (2) late or delayed complications, which include endoleaks, endotension, and those specific to the endograft,<sup>3,4</sup> as well as complications including aneurysmal rupture, stent migration, stent stenosis, and stent kinks or occlusions (Table 2).

## MEDICAL COMPLICATIONS

The appeal of EVAR as a less invasive approach to abdominal aortic aneurysm exclusion is most pronounced in patients with significant medical comorbidities. Many of these patients have significant cardiac and pulmonary disease. Most studies have suggested that EVAR, compared to open surgical repair, reduces the likelihood of major complications in patients with significant

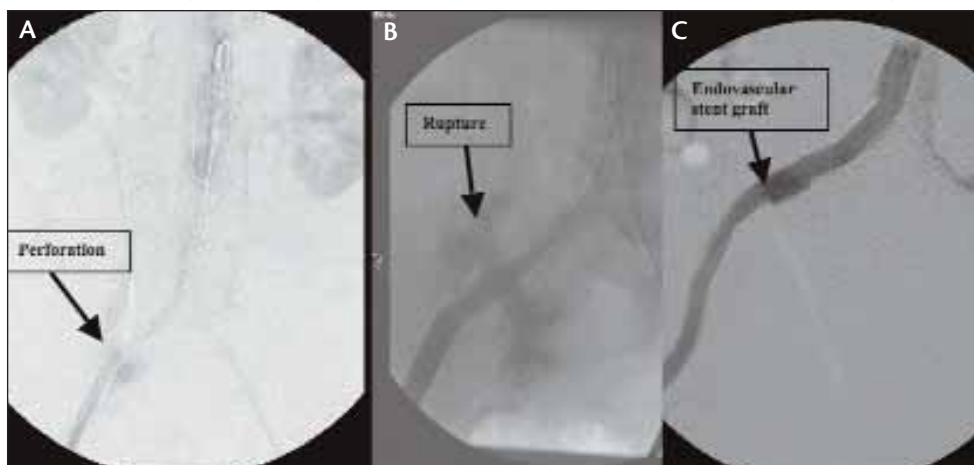


Figure 1. Perforation and rupture of the right iliac artery (A and B) and the endovascular stent grafting of the perforation in the right iliac artery (C).

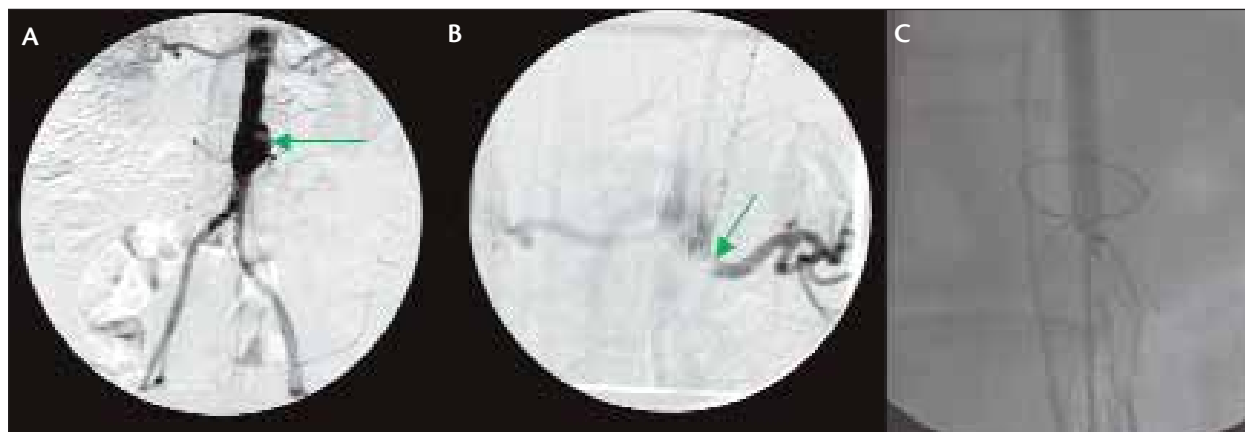


Figure 2. Baseline small abdominal aortic aneurysm with atheroembolism (A) followed by endovascular graft malposition cephalad above the renal artery (B). Snare attempt for malpositioned endograft (C).

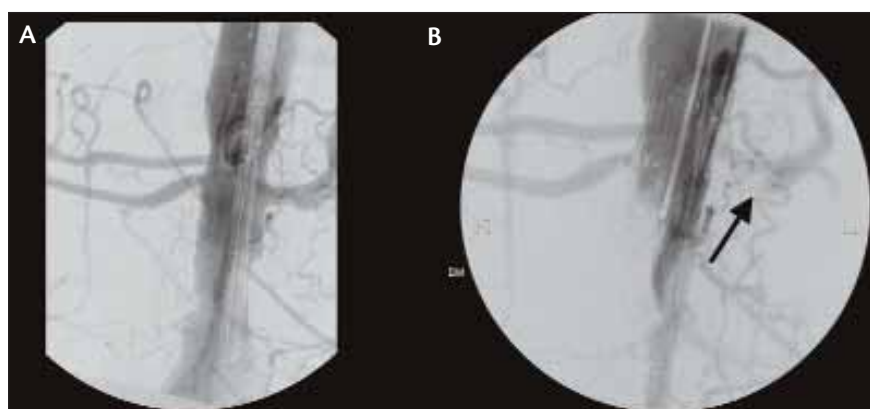


Figure 3. Predeployment (A) and postdeployment (B) with the left renal artery jailed by the endograft.

medical comorbidities.<sup>5</sup>

Therefore, it is thought that the cardiopulmonary and systemic stress associated with EVAR is lower than with open repair.

#### DEPLOYMENT COMPLICATIONS

Like all endovascular procedures, EVAR shares a common set of complications related to the actual interventional procedure and graft deployment.

Patients undergoing EVAR are at risk for renal deterioration related to several potential mechanisms.

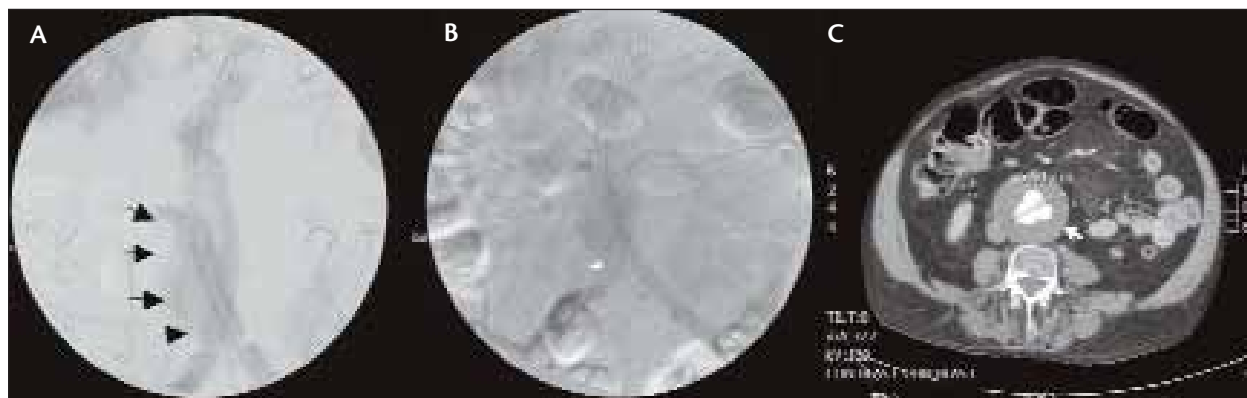
Contrast-induced nephropathy is a real risk in these patients, particularly because the volume of iodinated dye used in any given case can be highly variable. Furthermore, there is a risk of atheroemboli during deployment. The inadvertent obstruction of the renal arteries by the endograft is also a risk (Figures 2 and 3), particularly if there are accessory renal arteries that must be sacrificed. There have been rare case reports of graft migration cephalad with obstruction, which leads to acute renal failure. It is debatable whether EVAR has a higher rate of renal complications when compared to open surgical repair, and a critical review of the literature is necessary. Most importantly, judicious patient selection is key to minimizing the renal complications of EVAR.

Both mesenteric and pelvic/buttock ischemia can occur during EVAR. Although these can occur acutely, other than from embolization, this should be a fairly rare event. Careful imaging, localization, and even

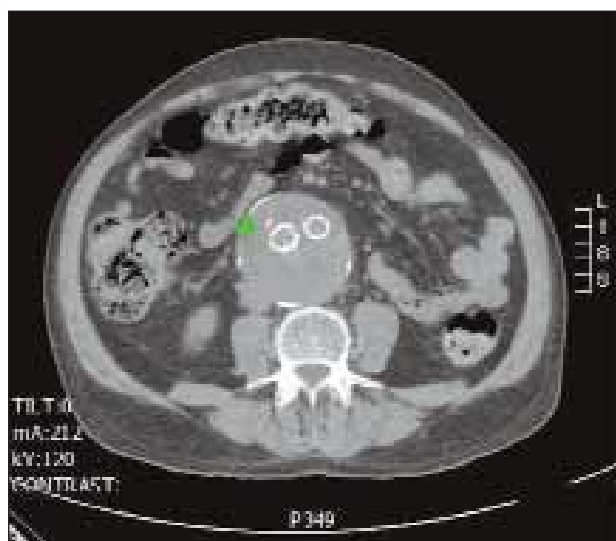
TABLE 1. ACUTE COMPLICATIONS OF EVAR<sup>3,4,5</sup>

#### ACUTE COMPLICATIONS

- Iliac perforation and rupture
- Contrast-induced nephropathy
- Mesenteric/pelvic ischemia (acute or chronic)
- Wire tip complications (stroke, myocardial infarction, dissection)
- Inability to cannulate the contralateral gate leading to conversion to aorto-uni-iliac device, iliac rupture/dissection/extraction
- Obstruction of (accessory) renal arteries
- Acute distal limb ischemia
- Infection



**Figure 4.** Type I distal endoleak from right limb of the endovascular graft. Aneurysmal sac (A). Distal endoleak from the right limb of the endovascular graft (B). Aneurysmal sac (C).



**Figure 5.** Lumbar artery contributing to a type II endoleak (green arrow).

**TABLE 2. DELAYED COMPLICATIONS OF EVAR<sup>3,4,5</sup>**

## DELAYED COMPLICATIONS

- Type I endoleak (proximal and distal)
- Type II endoleak
- Type III endoleak
- Type IV endoleak
- Limb occlusion
- Graft occlusion or stenosis
- Migration
- Distal embolization (renal, mesenteric, lower extremity, etc.)

selective/staged embolization (when necessary), can help mitigate these complications. A few examples of anomalous mesenteric arteries and inadvertent endograft malposition have been described (Figures 2 and 3). This highlights the importance of personally reviewing and identifying all major arterial branches and accurately measuring lengths and diameters during the predeployment imaging studies.

A major limitation of all endografts is the size of the deployment system required. Although there is a wide range among various manufacturers, all may potentially pose a risk to some patients. Patients with small, tortuous, and/or heavily diseased iliac arteries are at risk of iliac rupture or perforation. This complication can occur during any stage of the procedure but most commonly during the insertion or removal of the deployment systems or sheaths (Figures 2 and 3). One should have ready access to an aortic occlusion balloon as a safety measure. For nonsurgeons, this complication in particular highlights the fact that EVAR should be performed in collaboration with a surgical team.

Although there are a myriad of potential complications, one complication in particular worth discussing is that EVAR requires the use of very stiff guidewires. These are often referred to as *coat hangers*. One should always be conscious of where the wire tip is located during the procedure.

## GRAFT-RELATED COMPLICATIONS

The use of EVAR has created its own unique set of complications related to the potential for the variable persistent pressurization of the aneurysm sac via endoleak and endotension. These are usually delayed complications that are noted upon follow-up.

Recent studies show that distal type I endoleaks (Figure 4) and type II endoleaks are the most common

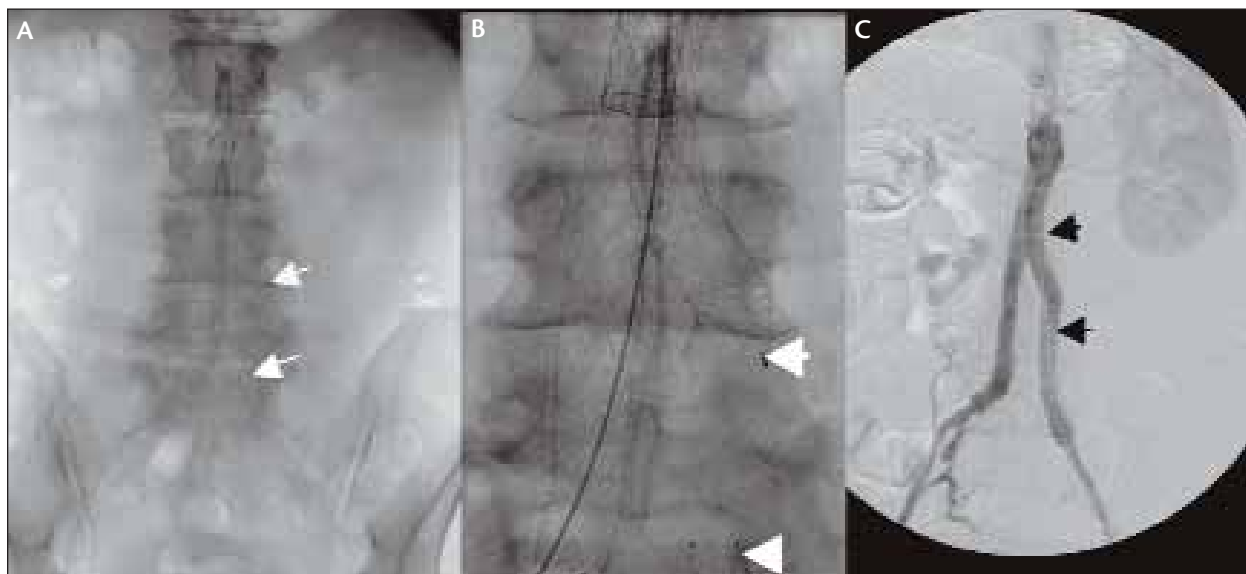


Figure 6. Endovascular graft modular separation (A and B) leading to delayed type III endoleak. Successful endovascular repair with new graft placement (C).

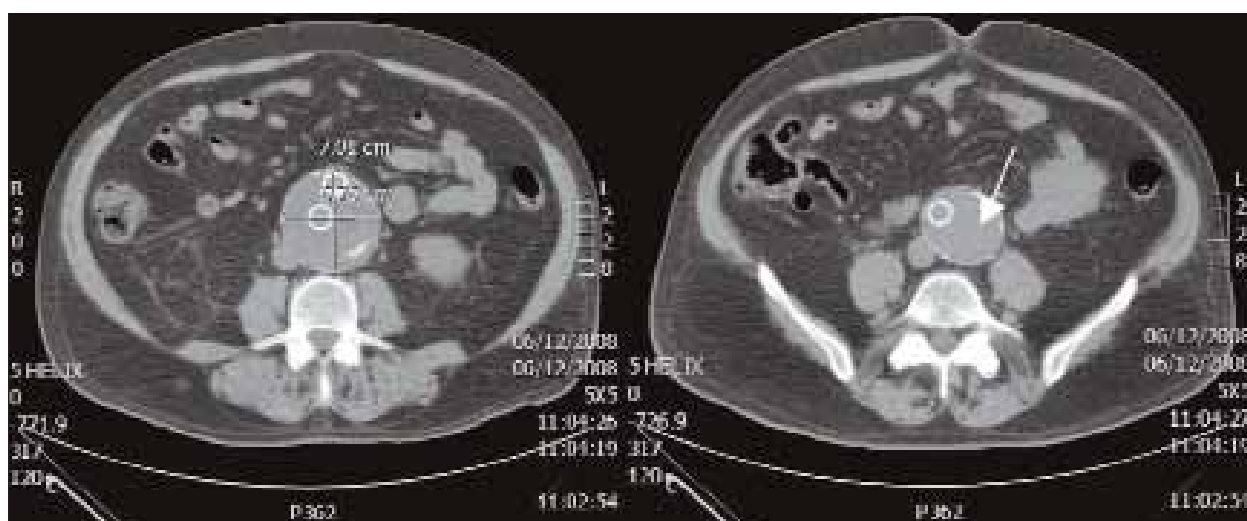


Figure 7. Abdominal computed tomography of type III endoleak due to graft separation. Note that only the right iliac limb is visible with the modular separation of the left iliac limb (white arrow).

delayed complications of EVAR.<sup>3</sup> Several factors are associated with delayed proximal or distal type I endoleaks. These are mainly due to unfavorable necks, landing zone enlargements, and design and dimension characteristics of stent grafts. They also occur more commonly in grafts that rely on the radial force for fixation rather than hooks. For this reason, oversizing the graft by approximately 20% is a common practice.

Type II endoleaks (Figure 5) occur in 10% to 20% of cases after EVAR. These are usually due to aneurysmal sac reperfusion from the lumbar and inferior mesenteric arteries.<sup>6</sup> The occurrence of a type II endoleak depends

on several factors, which include the type of graft used, the presence of mural thrombus, and the number of patent aortic branch vessels.<sup>7,8</sup>

Type III endoleaks (Figures 6 and 7) are frequently overlooked during follow-up (Figure 4). They can often be mistaken for a type II endoleak or can be missed altogether. Disconnection and distortion are usually more notable signs of type III endoleaks, and the diagnosis is usually confirmed only during intervention.

Graft porosity, the cause of type IV endoleaks, is not as common with the current generation of endografts. These can usually be noted on the completion

angiogram or in follow-up computed tomography scans.<sup>3,9</sup>

Generally, type II and type IV endoleaks do not require intervention unless there is aneurysm sac growth. On the contrary, types I and III require treatment due to the exposure of the aneurysm sac to systemic pressures.<sup>10</sup> Both of these endoleaks can result from the migration of the endograft.

Stent migration or malposition is highly significant due to the consequences of where it is positioned. It may be further complicated by endoleaks or occlusion of arteries, such as the renal (Figure 4) or subclavian arteries.<sup>10</sup>

As with any vascular procedure, there is also a risk for graft and limb thrombosis. Risk factors for limb thrombosis in EVAR include iliac diameter, tortuosity, stenosis, and runoff vessel status. Endograft limb occlusion can result in acute or chronic limb ischemia. Lower extremity ischemia after aortic reconstructions is a well-recognized result of atheroemboli and occurs in 3% to 10% of patients.<sup>3,11</sup> Pelvic ischemic complications after open infrarenal aortic reconstruction occur in 1% to 2% of patients.

## CONCLUSION

The advances that have been made in understanding the causes of EVAR failure or complications have resulted in a reduction or prolongation of a secondary interventional procedure or open surgery for these complications. This has also led to improved techniques and devices and even hybrid procedures. Today, a greater proportion of these complications can be solved by purely endovascular options than ever before.<sup>12-14</sup> EVAR still remains an excellent option for patients with abdominal aortic aneurysms and suitable anatomies. However, to minimize the complications of EVAR, preoperative planning with accurate imaging and measurements are of paramount importance. ■

*Robert S. Dieter, MD, RVT, is Assistant Professor of Medicine, Division of Cardiology, Loyola University, Chicago, Illinois. Financial interest disclosure information was not available at the time of publication.*

*Jeffrey Freihage, MD, is Cardiology Fellow, Division of Cardiology, Loyola University, Chicago, Illinois. Financial interest disclosure information was not available at the time of publication.*

*Pranab Das, MD, is Assistant Professor of Medicine, Department of Internal Medicine, Division of Cardiology, University of Tennessee Health Sciences Center, Memphis, Tennessee. Financial interest disclosure information was not available at the time of publication.*

*Leonardo Clavijo, MD, is Assistant Professor of Medicine,*

*Director of Vascular Medicine and Peripheral interventions, Division of Cardiology, University of Southern California, Los Angeles, California. Financial interest disclosure information was not available at the time of publication.*

*Sohail Ikram, MD, is Associate Professor of Medicine and Director of Coronary and Peripheral Vascular Interventions, University of Louisville, Louisville, Kentucky. Financial interest disclosure information was not available at the time of publication.*

*Krishna Mannava, MD, is Assistant Professor of Surgery, Loyola University, Chicago, Illinois. Financial interest disclosure information was not available at the time of publication.*

*John P. Pacanowski, Jr, MD, is from the Department of Vascular Surgery, University of Tennessee, Knoxville, Tennessee. Financial interest disclosure information was not available at the time of publication.*

*Aravinda Nanjundappa, MD, RVT, is Associate Professor of Medicine and Surgery, West Virginia University, Charleston West Virginia. He has disclosed that he holds no financial interest in any product or manufacturer mentioned herein. Dr. Nanjundappa may be reached at dappamd@yahoo.com.*

*Theodore Ang Tan, MD, is Surgery Observer, Charleston Area Medical Center, Charleston, West Virginia. He has disclosed that he holds no financial interest in any product or manufacturer mentioned herein. Dr. Tan may be reached at (252) 414-8231; tantheodore@gmail.com.*

1. Parodi JC, Palmaz JC, Brone HD. Transintra-luminal graft implantation for abdominal aortic aneurysms. *Ann Vasc Surg.* 1991;5:491-499.
2. Tarride JE, Blackhouse G, De Rose G, et al. Cost effectiveness analysis of elective endovascular repair compared with open surgical repair of abdominal aortic aneurysms for patients at a high surgical risk: a 1-year patient-level analysis conducted in Ontario, Canada. *J Vasc Surg.* 2008;48:779-787.
3. Becquemin JP, Allaire E, Desgranges P, et al. Delayed complications following EVAR. *Techniques in Intravascular and Interventional Radiology.* 2005;8:30-40.
4. Magennis R, Joekes E, Martin J, et al. Complications following endovascular abdominal aortic aneurysm repair. *British J Radiol.* 2002;75:700-707.
5. Prinssen M, Verhoeven EL, Buth J, et al. A randomized trial comparing conventional and endovascular repair of abdominal aortic aneurysms. *N Engl J Med.* 2004;351:1607-1618.
6. Veith FJ, Baum RA, Ohki T, et al. Nature and significance of endoleak and endotension (summary of opinions expressed at an international conference). *J Vasc Surg.* 2002;35:1029-1035.
7. Velazquez OC, Baum RA, Carpenter JP, et al. Relationship between preoperative patency of the inferior mesenteric artery and subsequent occurrence of type II endoleak in patients undergoing endovascular repair of abdominal aortic aneurysms. *J Vasc Surg.* 2000;32:777-788.
8. Warrier R, Miller R, Bond R, et al. Risk factors for type II endoleaks after endovascular repair of abdominal aortic aneurysms. *ANZ J Surg.* 2008;78:61-63.
9. Stolzmann P, Frauenfelder T, Pfammatter T, et al. Endoleaks after endovascular abdominal aortic aneurysm repair: detection with dual-energy dual-source CT. *Radiology.* 2008;249:682-691.
10. Peterson MD, Wheatley GH III, Kpodonu J, et al. Treatment of type II endoleaks associated with left subclavian artery coverage during thoracic aortic stent grafting. *J Thorac Cardiovasc Surg.* 2008;136:1193-1199.
11. Barbiero G, Baratto A, Ferro F, et al. Strategies of endoleak management following endoluminal treatment of abdominal aortic aneurysms in 95 patients: how, when, and why. *Radiol Med.* 2008;113:1029-1042.
12. Aljabri B, Obrand DI, Montreuil B, et al. Early vascular complications after endovascular repair of aortoiliac aneurysms. *Ann Vasc Surg.* 2001;15:608-614.
13. Väärämäki S, Pimenoff G, Heikkinen M, et al. Ten-year outcomes after endovascular aneurysm repair (EVAR) and magnitude of additional procedures. *Scand J Surg.* 2007;96:221-228.
14. Dubene SR, White GH, Pasenau J, et al. Endotension. A review of current views on pathophysiology and treatment. *J Cardiovasc Surg (Torino).* 2003;44:553-557.