

# Atherosclerotic Renal Artery Stenosis

When is open surgical reconstruction the best treatment option?

BY THOMAS A. ABBRUZZESE, MD, AND RICHARD P. CAMBRIA, MD

**A**therosclerotic disease is the most common etiology of hemodynamically significant renal artery stenosis (RAS), accounting for 80% of all cases. This review assumes appropriate patient selection for intervention—an arena hardly supported by level-1 evidence—and important diagnostic and clinical decision-making issues are not further considered. We limit this discussion of the role of surgical renal artery reconstruction (RAR) to atherosclerotic renovascular disease.

The evolution of percutaneous endovascular therapy for atherosclerotic renovascular disease was characterized by demonstration of the efficacy of stent revascularization.<sup>1</sup> Coupled with the decreased morbidity and mortality of percutaneous intervention, there has been a dramatic paradigm shift in the treatment of renal artery stenosis.<sup>2</sup>

Because surgical RAR involves intracavitary surgical exposure, often with aortic cross-clamp application, stent revascularization for RAS is perhaps an ideal example of percutaneous endovascular treatment offering genuine and substantial decrease in morbidity and mortality—the documented favorable durability of surgical revascularization notwithstanding.<sup>3</sup> The authors' practice parallels the likely national standard (ie, stent revascularization is utilized in the majority of cases). Yet, the attendant morbidity and mortality of surgical RAR served as a "triage" effect that limited treatment to only the most severe cases in which the benefits outweighed the risks. The results of this paradigm shift are both an increase in referrals and an expansion of the accepted indications for renal artery revascularization with a concomitant increase in the number of interventions performed.<sup>2</sup> A recent report of the incidence of renal artery revascularizations in Medicare beneficiaries revealed a progressive increase in the number of interventions performed from 7,660 in 1996 to 18,520 in 2000.<sup>4</sup>

Such a rapid increase in renal artery interventions is not necessarily beneficial to patients, and interventions for most patients are not "evidenced-based," related to a genuine dearth of level-1 evidence. Indeed, a recent meta-analysis,

sponsored by the Agency for Healthcare Research Quality, demonstrated a lack of definitive, robust evidence to support either medical therapy alone, angioplasty (with or without stenting), or surgical revascularization for the treatment of atherosclerotic RAS.<sup>5</sup> However, experienced clinicians recognize that the lack of level-1 evidence should not equal therapeutic nihilism. Atherosclerotic renovascular disease is being diagnosed in an increasing percentage of patients at the inception of dialysis,<sup>6</sup> and favorable, even dramatic results, such as rescue from dialysis dependence, have been achieved in a variety of clinical circumstances;<sup>7-10</sup> the reader is referred to summary reviews that address components of clinical decision-making in atherosclerotic RAS.<sup>11,12</sup> The currently enrolling Cardiovascular Outcomes in Renal Atherosclerotic Lesions (CORAL) trial, sponsored by the National Institutes of Health, will compare angioplasty and stenting with aggressive medical therapy and may provide much-needed data on the optimal management of RAS; however, the results will not be available until 2010.<sup>13</sup>

## COMPARING SURGICAL AND ENDOVASCULAR TREATMENT

With respect to surgical RAR, Cherr, in summarizing the benchmark Wake-Forest experience, reported a study of 500 hypertensive patients with atherosclerotic RAS who underwent surgical renal artery revascularization.<sup>7</sup> Perioperative morbidity and mortality were 16% and 4.6%, respectively. The experience revealed that 12% of patients were cured of their hypertension, 73% showed clinically relevant improvement, and 15% were unchanged. With respect to renal function, 43% exhibited improved function (defined as an increase in their estimated glomerular filtration rate  $\geq 20\%$ ), 47% demonstrated unchanged function, and 10% developed worse function. Surveillance duplex examination demonstrated restenosis in 3.9% of patients. During the follow-up period (mean, 54 months), 16.8% of patients became dialysis dependent.

At the Massachusetts General Hospital, over the period

from January 1980 to March 2001, two independent reviews were performed involving 235 patients who underwent surgical revascularization of atherosclerotic RAS specifically for renal functional salvage.<sup>8,9</sup> All patients had hemodynamically significant RAS ( $\geq 75\%$ ), and 60% underwent revascularization of either their sole functioning kidney or both kidneys.

Major morbidity was largely cardiac in origin and accounted for the majority of perioperative deaths. Overall, perioperative mortality was 6.3% (2% after 1990). During the mean follow-up period of 4.3 years (functional outcomes are only relevant with such adequate follow-up), 8% were cured of their hypertension, and 71% exhibited clinically relevant improvement. In terms of renal function, 76% of patients had either improved or stable renal function, and 24% developed worsened function (60% of whom became dialysis dependent). With respect to the durability of surgical RAR, we previously reported that the actuarial graft patency at 5 years was 91% for aortorenal bypass grafts and 85% for extra-anatomic bypass grafts.<sup>3</sup>

The only prospective, randomized study to date comparing endovascular and surgical reconstruction for atherosclerotic RAS was reported by Weibull in 1993.<sup>14</sup> Fifty-eight patients with unilateral RAS and poorly controlled hypertension were randomized to either angioplasty alone or surgical reconstruction of the renal artery. The technical success rate was 97% for surgery and 87% for angioplasty. Primary and secondary patency rates at 24 months were 96% and 97% in the surgical cohort and 75% and 90% in the angioplasty group. Blood pressure was either cured or improved in 86% of the surgical patients and 90% of the angioplasty patients (four of whom crossed over to surgical reconstruction).

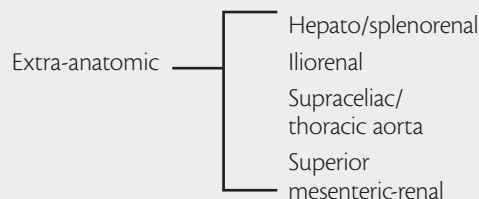
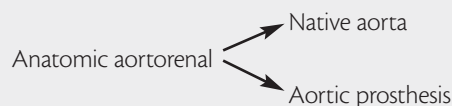In considering the outcomes of percutaneous endovascular treatment of RAS, early studies, including Weibull's report, involved angioplasty alone. Many subsequent studies have documented the advantage of angioplasty with stenting over angioplasty alone. In a meta-analysis of 14 studies involving 678 patients, Leertouwer reported both a higher technical success rate (98% vs 77%) and a lower restenosis rate (17% vs 26%) with renal artery stent placement as compared to angioplasty alone.<sup>15</sup> More recent studies of renal artery angioplasty and stenting demonstrate an overall immediate technical success rate of 98% with a morbidity of 2.7% and a mortality of 1.7%.<sup>16-20</sup> In terms of hypertension control, Tuttle reported that 2% of patients were cured, 46% demonstrated improvement, and 52% showed no response.<sup>16</sup> In the 57% of patients who had preoperative renal dysfunction, 16% improved postoperatively, 75% had no change in renal function, and 9% showed deterioration. The restenosis rate was 14%. These results were mirrored in the study reported by Rodriguez-Lopez, who studied 108 patients undergoing renal angio-

plasty and adjuvant stenting and documented a 74% primary and 85% secondary patency rate.<sup>20</sup> Blood pressure response included 11% cured, 55% improved, 27% unchanged, and 5% worsened. There was no change in renal function in this study. In a study of 300 patients who underwent 363 stent procedures in 358 arteries, Lederman documented complete cure of hypertension in 0.7%, improvement in 70%, and worsening in 27%.<sup>21</sup> In the 37% of patients who had preoperative renal dysfunction, 7.5% demonstrated improvement, 78% remained stable, and 14% deteriorated postoperatively.

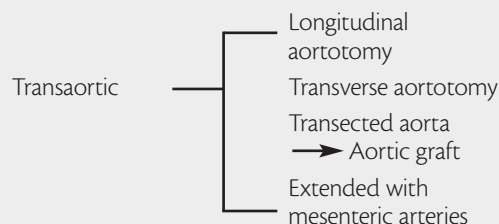
A summary of the available literature indicates that surgical revascularization provided a favorable response to hypertension, including an 11% cure of hypertension and a 72% improvement in blood pressure control. Renal function improved in 42% of patients, remained stable in an additional 47%, and worsened in 15%. Therefore, 89% of patients experienced either an improvement or stabilization of their renal function after surgical RAR. Angioplasty

**TABLE 1. OPTIONS FOR SURGICAL RENAL ARTERY RECONSTRUCTION**

#### Bypass Grafts



#### Endarterectomy



Transrenal  
Orificial within complex aneurysm

#### Miscellaneous

Re-implantation  
Patch angioplasty  
Autotransplantation

and stenting (either primary or adjuvant) provided a 3.5% cure of hypertension and a 62% improvement in blood pressure control—clearly inferior to the response to that obtained with surgical RAR. In terms of renal function, angioplasty and stenting resulted in an improvement in 8% and stabilization in 81%, with 10% exhibiting a deterioration of function. Overall, 90% of patients experienced either an improvement or stabilization of renal function, similar to surgical RAR. Surgery had a higher morbidity (16% vs 2.7%) and mortality (5% vs 1.7%), but was more durable than angioplasty and stenting with a lower restenosis rate (3.9% vs 15% to 30%).

### OPTIONS FOR SURGICAL RENAL ARTERY RECONSTRUCTION

A multitude of technical options are available in consideration of surgical RAR. As displayed in Table 1, these can be anatomically divided into anatomic versus extra-anatomic bypass grafts, endarterectomy, and/or re-implantation. Important clinical variables, such as patient age/comorbidity considerations, anatomic variables of the renovascular lesions/renal arteries themselves, and aortic anatomy/pathology, contribute to the choice of a particular surgical revascularization strategy. A significant, additional consideration is whether concomitant aortic pathology either necessitates,

or makes highly desirable, graft replacement of the aorta. Such combined aortorenal reconstructions constitute 30% to 40% of representative surgical series.<sup>3,7-10</sup>

Combined aortic and RAR is generally necessary only when the aortic pathology—on its own merits—requires treatment. Literature exists suggesting such an operation has increased morbidity and mortality when compared to either isolated aortic grafting or isolated renovascular repair.<sup>22-24</sup> We documented that the coronary risk profile of patients with combined operation was considerably more severe than of patients with isolated aortic operation; an overall 2% mortality has attended combined operation since 1990.<sup>25</sup>

In terms of durability considerations, there was a traditional bias in favor of anatomic aortorenal bypass,<sup>7</sup> although we and others have documented that extra-anatomic bypasses provide equivalent anatomic/functional results while considerably diminishing the overall surgical insult.<sup>3,26</sup> Transaortic endarterectomy (as opposed to bypass grafting) experienced a “rebirth” as a RAR technique and is particularly suited to bilateral simultaneous revascularization and/or treatment of multiple renal arteries.<sup>10,25,27</sup> This procedure does, however, require a fairly extensive aortic dissection and cross-clamp application.

### WHO MAY BENEFIT FROM OPEN SURGICAL RECONSTRUCTION?

Despite possibly greater functional results, at least with respect to hypertension control, and the documented superior durability of surgical RAR compared to stenting for RAS, most practitioners, including vascular surgeons, accept the tenet that the higher morbidity and mortality of surgical RAR favors stenting as the primary treatment modality for most patients with atherosclerotic RAS. Yet, our contention is that there is a subset of patients with atherosclerotic RAS who will derive more benefit from primary, open surgical RAR as opposed to angioplasty and stenting.

An unfortunate consequence of the paradigm shift to renal stent revascularization is that many practitioners (including some surgeons) have little appreciation of the nuances, clinical utility, and/or the results of surgical RAR. Furthermore, appropriate selection and referral of these patients is important as surgical RAR after failed stenting has been documented to at least complicate repair when compared to primary operation.<sup>28</sup> Important patient-specific and procedural considerations (ie, renovascular/aortic anatomic and procedural durability), when factored into the development of an interventional strategy, favor surgical RAR as opposed to stent revascularization as the primary treatment modality for atherosclerotic RAS.

**TABLE 2. RENOVASCULAR FACTORS THAT COMPLICATE OR PRECLUDE PERCUTANEOUS RENAL ARTERY REVASCLARIZATION**

#### Anatomic Factors

- Early branching of the main renal artery
- Dual renal arteries arising from the aorta in close proximity
- Multiple small renal arteries

#### Lesion Characteristics

- Length
  - Long, complicated lesion
- Location
  - Ostial versus middle or distal segment lesions
  - Lesion extending into a major branch
- Nature
  - Severe circumferential calcification
  - Recurrent lesions
    - Disease progression after previous intervention
    - In-stent stenosis

#### Associated Renal Artery and Aortic Pathology

- Aneurysmal degeneration of the renal artery
- Pararenal aneurysmal degeneration of the aorta
- Significant atherosclerotic disease of the pararenal aorta

## RENOVASCULAR ANATOMIC CONSIDERATIONS

Several considerations of renovascular and/or aortic anatomy/pathology represent clinical situations in which open reconstruction is preferred over percutaneous endovascular intervention. As detailed in Table 2, these include anatomic variations within the renovascular system such as early branching of the main renal artery, dual renal arteries whose origins arise in close proximity to each other, and multiple small renal arteries. In particular, the anatomic situation of early branching of the main renal artery, in which ostial stenting either threatens a major branch or necessitates stenting up to the branch point is a contraindication to percutaneous treatment, assuming the patient is otherwise a reasonable surgical candidate. Characteristics of the renal artery lesion itself, such as length, location, and nature (ie, severe concentric calcification or recurrent lesions such as disease progression after a previous intervention or in-stent stenosis) also influence a potential surgical interventional strategy.

Associated renal artery pathology, such as macroaneurysm of either the renal artery origin or the renal artery proper, renders a percutaneous approach hazardous, at best, and should prompt consideration for surgical RAR. With the continued development of low-profile, .018- and .014-inch-based systems, some of these renovascular anatomic challenges may be overcome, but the restenosis rate of 14% to 30% for percutaneous intervention, combined with the technical difficulty of secondary surgical intervention in these situations, indicates that endovascular intervention is not the appropriate initial therapy in otherwise suitable surgical candidates. Although recent studies of angioplasty and stenting report technical success rates >95%, these anatomic considerations are largely ignored in the current literature.

## AORTIC ANATOMIC CONSIDERATIONS

Because the majority of atherosclerotic renal artery stenoses are aortic “spillover” disease, extensive aortic degenerative and/or aneurysm disease is commonplace in potential candidates for renovascular intervention. In our previous experience with surgical RAR, at least one-third of RAR patients (who had independent indications for renovascular intervention) were initially referred for potential treatment of aortic disease.<sup>3,8</sup> Irrespective of significant aortic disease, aortic replacement is indicated only if independent, legitimate criteria to do so exist; to wit, it is a rare circumstance wherein graft replacement of the aorta is needed simply to originate an aortorenal bypass graft.

Although definitive data do not exist to support our contention that extensive pararenal atherosclerotic disease increases the risk of cholesterol embolization with catheter-

based therapies, it is clear that this thankfully uncommon complication is potentially devastating. Many patients with RAS will have antecedent axial imaging studies detailing such pararenal aortic disease, and consideration of surgical revascularization is appropriate therein. The position that distal protection devices will positively impact the risk of cholesterol embolization seems illogical given that aortic catheter manipulation is likely responsible for embolization, and ostial renal artery stenosis, being aortic wall plaque, is a totally different “entity” from carotid bifurcation disease.

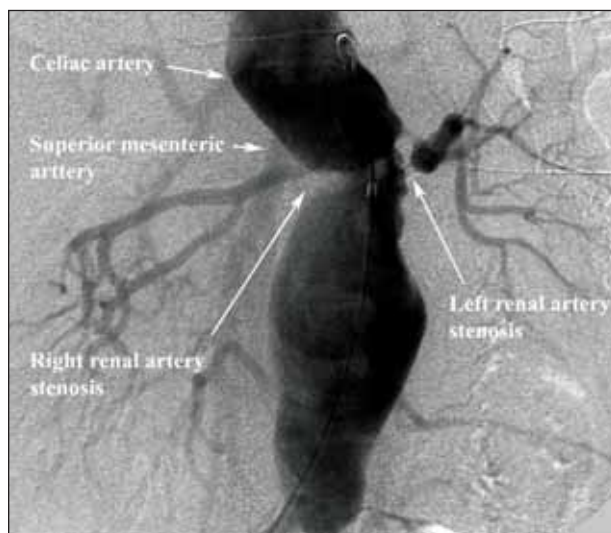
In consideration of abdominal aortic aneurysms (AAAs) wherein repair is indicated, an important discriminant in the renovascular intervention is the feasibility of stent graft repair. In 2005, 70% of infrarenal AAAs at our institution were treated with stent graft repair. In our practice, concomitant hemodynamically significant renovascular lesions in patients undergoing aortic stent graft repair for AAA are treated with stenting (irrespective of functional significance), as plaque shifts with stent graft deployment can precipitate renal artery occlusion.

When stent graft repair is not anatomically feasible (ie, open AAA repair required) concomitant renovascular lesions, wherein repair is indicated, are repaired simultaneously with one of the options detailed in Table 1. Specifically, hemodynamically significant RAS in juxtarenal or thoracoabdominal aneurysms with involvement of the visceral segment and significant aortic debris that poses an increased risk of cholesterol embolization are treated with combined RAR and aneurysm repair. An antecedent renal artery stent in such circumstances—sometimes recommended to “decrease the overall scope” of open operation—is both illogical and ill-advised. Such patients generally require surgical manipulation and/or clamping of the juxtarenal aorta, and stents can be crushed or otherwise dislodged. We have had the opportunity to remove stents in such circumstances. In addition, catheter manipulations in such a diseased aorta can precipitate disastrous cholesterol emboli syndrome.

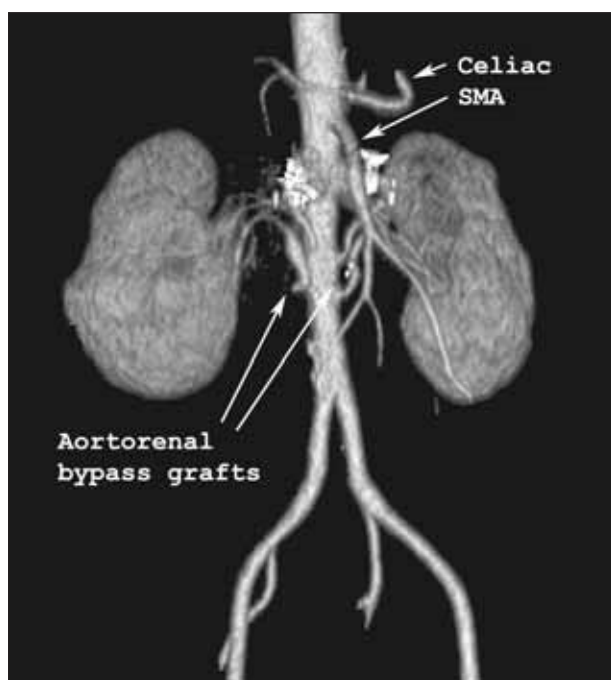
Finally, in the circumstance of juxtarenal aortic occlusion secondary to aortoiliac occlusive disease, these patients often have layering thrombus immediately adjacent to and/or partially in the renal artery ostia, making catheter manipulations unwise; combined aortic and renal artery operation is indicated in such patients.

Illustrative of the situation wherein aortic anatomy treatment drives the renovascular intervention is the case of a 66-year-old woman referred for treatment of a type 2 thoracoabdominal aortic aneurysm; her clinical presentation was malignant hypertension, renal insufficiency, and bilateral RAS. The patient’s aneurysm was discovered when she presented to her ophthalmologist with blurred vision and was noted on examination to have florid papilledema and blood pressure of 280/140.



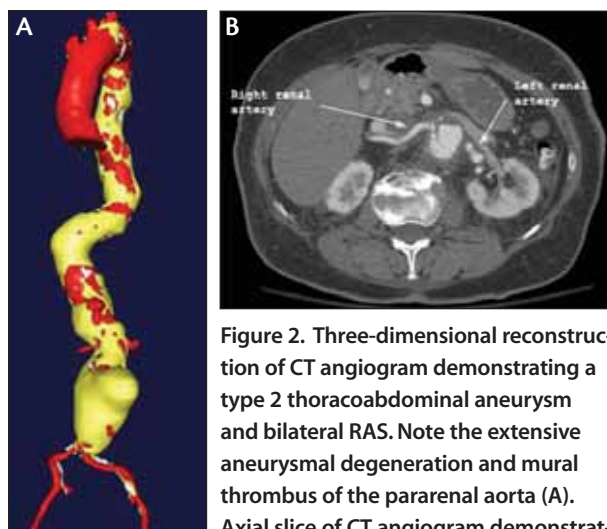


**Figure 1.** Aortogram demonstrating bilateral RAS within the midst of a thoracoabdominal aneurysm. Attempted left renal artery angioplasty was both unsuccessful and ill-conceived.



**Figure 3.** Three-dimensional reconstruction of CT angiogram depicting four patent aortorenal vein bypass grafts to duplicate bilateral renal arteries. Note the stent artifact in the origins of the four native renal arteries.

She was admitted to a local hospital where clinical work-up demonstrated renal insufficiency with a serum creatinine concentration of 2 mg/dL, bilateral RAS, and a large thoracoabdominal aneurysm. She underwent unsuccessful renal



**Figure 2.** Three-dimensional reconstruction of CT angiogram demonstrating a type 2 thoracoabdominal aneurysm and bilateral RAS. Note the extensive aneurysmal degeneration and mural thrombus of the pararenal aorta (A). Axial slice of CT angiogram demonstrating bilateral RAS in the midst of a thoracoabdominal aneurysm with significant intraluminal debris (B).

artery angioplasty, despite the renal arteries being in the midst of a diseased, aneurysmal aorta (Figure 1); she was then stabilized on an aggressive medical regimen of antihypertensive medications and was referred for definitive treatment. We performed CT angiography as part of her preoperative evaluation (Figure 2A, B), which demonstrated a 7.9-cm, type 2 thoracoabdominal aneurysm, multiple penetrating ulcers in the descending thoracic aorta, and a possible contained rupture in the infrarenal abdominal aorta. The CT angiography also demonstrated significant bilateral RAS. She subsequently underwent open repair of her thoracoabdominal aneurysm, endarterectomy of her right renal artery, and aortorenal bypass of her left renal artery.

Her postoperative course was uncomplicated. At the time of discharge, she had much improved blood pressure control on a modest medical regimen and stable renal function (creatinine concentration, 1.8 mg/dL).

## PROCEDURAL DURABILITY CONSIDERATIONS

A final consideration for primary surgical reconstruction involves the issue of the durability of renovascular repair, particularly in young, low-risk patients. As reviewed herein, the long-term durability of angioplasty and stenting is inferior to surgical RAR. From the surgeon's perspective, this is intuitively logical as such relatively large-bore, high-flow reconstructions have generally favorable long-term function. Although it is certainly true that our preference is stent revascularization in the "typical" older patient with diffuse, atherosclerotic cardiovascular disease, a subset of patients with RAS are

younger without associated CAD. A recently managed case is illustrative of this point. A 36-year-old man was referred to us for treatment of complications of renal artery angioplasty and stenting. He originally presented to an outside institution with renal insufficiency and malignant hypertension. He had a history of tobacco abuse, hyperlipidemia, and a strong family history of both coronary artery and peripheral vascular disease.

Work-up demonstrated malignant hypertension and duplicate left and right renal arteries with severe ostial stenosis of all four arteries. He underwent successful angioplasty and stenting of all four arteries with an excellent angiographic result and normalization of both his blood pressure and renal function (at age 34). Within a few months of the initial procedure, he developed in-stent stenosis of the left superior renal artery and underwent repeat angioplasty and stenting of this stenosis with an excellent result.

However, 2 years after his initial procedure, he presented with progressive onset of severe hypertension associated with renal insufficiency (creatinine concentration, 3.5 mg/dL), and angiography showed proximal, in-stent occlusions of the right and left superior renal arteries, a 70% in-stent stenosis of the right inferior renal artery, and a 90% in-stent stenosis of the left inferior renal artery. The patient was then referred for RAR and underwent uncomplicated aortorenal bypass with greater saphenous vein to all four renal arteries (Figure 3). Postoperatively, his creatinine concentration improved from 3.5 to 1.5 mg/dL with significant improvement in control of his blood pressure.

## CONCLUSION

Although we ascribe to the generally prevailing practice that stent revascularization is the preferred treatment for the vast majority of renovascular disease patients, consideration of surgical revascularization is appropriate in a variety of anatomic and clinical circumstances as reviewed herein. A brief survey of our vascular/endovascular service data indicates that during the interval of January 1, 2002 to December 31, 2006, a total of 241 stents versus just 48 surgical RARs were performed. With appropriate cardiac risk stratification and contemporary surgical care, operative mortality for abdominal aortic surgery on our service is in the 1.5% range. "Bail-out" surgery after repetitive endovascular interventions is both more technically difficult and, because most failures of surgical RAR are technical in nature, some compromise of anatomic results—compared to primary RAR—can be anticipated.<sup>28</sup> ■

*Thomas A. Abbruzzese, MD, is a Clinical and Research Fellow in the Division of Vascular and Endovascular Surgery*

*at Massachusetts General Hospital in Boston. He has disclosed that he holds no financial interest in any product or manufacturer mentioned herein. Dr. Abbruzzese may be reached at (617) 726-8701; tabbruzzese@partners.org.*

*Richard P. Cambria, MD, is Professor of Surgery at Harvard Medical School, and Chief, Division of Vascular and Endovascular Surgery at Massachusetts General Hospital in Boston. He has disclosed that he holds no financial interest in any product or manufacturer mentioned herein. Dr. Cambria may be reached at (617) 726-8701; rcambria@partners.org.*

- Blum U, Krumme B, Flugel P, et al. Treatment of ostial renal-artery stenoses with vascular endoprotheses after unsuccessful balloon angioplasty. *N Engl J Med.* 1997;336:459-465.
- Knipp BS, Dimich JB, Eliason JL, et al. Diffusion of new technology for the treatment of renovascular hypertension in the United States: surgical revascularization versus catheter-based therapy, 1988-2001. *J Vasc Surg.* 2004;40:717-723.
- Cambria RP, Brewster DC, L'Italien GJ, et al. The durability of different reconstructive techniques for atherosclerotic renal disease. *J Vasc Surg.* 1994;20:76-85.
- Murphy TP. Increase in utilization of percutaneous renal artery interventions by medicare beneficiaries, 1996-2000. *Am J Roentgenol.* 2004;183:561-568.
- Balk E, Raman G, Chung M, et al. Effectiveness of management strategies for renal artery stenosis: a systematic review. *Ann Int Med.* 2006;145:901-912.
- Guo H, Kalra PA, Gilbertson DT, et al. Atherosclerotic renovascular disease in older US patients starting dialysis, 1996 to 2001. *Circulation.* 2007;115:50-58.
- Cherr GS, Hansen KJ, Craven TE, et al. Surgical management of atherosclerotic renovascular disease. *J Vasc Surg.* 2002;35:236-245.
- Cambria RP, Brewster DC, L'Italien GJ, et al. Renal artery reconstruction for the preservation of renal function. *J Vasc Surg.* 1996;24:371-382.
- Marone LK, Clouse WD, Dorer DJ, et al. Preservation of renal function with surgical revascularization in patients with atherosclerotic renovascular disease. *J Vasc Surg.* 2004;39:322-329.
- Cambria RP, Kaufman JL, Brewster DC, et al. Surgical renal artery reconstruction without contrast arteriography: the role of clinical profiling and magnetic resonance angiography. *J Vasc Surg.* 1999;29:1012-1021.
- Cambria RP, ed. Renovascular disease: contemporary management. Perspectives in vascular surgery and endovascular therapy. 2004;16:245-313.
- Jaff MR, ed. Endovascular therapy for atherosclerotic renal artery stenosis: present and future. In: Criado FJ, ed. *Endovascular Intervention: Today and Tomorrow*, Vol. 2. Armonk, NY: Futura Publishing Company; 2001:1-144.
- Cooper CJ, Murphy TP, Matsumoto A, et al. Stent revascularization for the prevention of cardiovascular and renal events among patients with renal artery stenosis and systolic hypertension: rationale and design of the CORAL trial. *Am Heart J.* 2006;152:59-66.
- Weibull H, Bergqvist D, Bergentz SE, et al. Percutaneous transluminal renal angioplasty versus surgical reconstruction of atherosclerotic renal artery stenosis: a prospective randomized study. *J Vasc Surg.* 1993;18:841-852.
- Leertouwer TC, Gussenhoven EJ, Bosch JL, et al. Stent placement for renal artery stenosis: where do we stand? A meta-analysis. *Radiology.* 2000;216:78-85.
- Taylor KR, Chouinard RF, Webber JT, et al. Treatment of atherosclerotic ostial renal artery stenosis with the intravascular stent. *Am J Kid Dis.* 1998;32:611-622.
- Rocha-Singh KJ, Mishkel GJ, Katholi RE, et al. Clinical predictors of improved long-term blood pressure control after successful stenting of hypertensive patients with obstructive renal artery atherosclerosis. *Cath Cardiovasc Interv.* 1999;47:167-172.
- Dorros G, Jaff M, Mathiak L, et al. Four-year follow-up of Palmaz-Schatz stent revascularization as treatment for atherosclerotic renal artery stenosis. *Circulation.* 1998;98:642-647.
- White CJ, Ramee SR, Collins TJ, et al. Renal artery stent placement: utility in lesions difficult to treat with balloon angioplasty. *J Am Coll Cardiol.* 1997;30:1445-1450.
- Rodriguez-Lopez J, Werner A, Ray LI, et al. Renal artery stenosis treated with stent deployment: indications, technique, and outcome for 108 patients. *J Vasc Surg.* 1999;29:617-624.
- Lederman RJ, Mendelsohn FO, Santos R, et al. Primary renal artery stenting: characteristics and outcomes after 363 procedures. *Am Heart J.* 2001;142:314-323.
- Clair DG, Belkin M, Whittemore AD, et al. Safety and efficacy of transaortic renal endarterectomy as an adjunct to aortic surgery. *J Vasc Surg.* 1995;21:926-933.
- Taylor SM, Langan EM 3rd, Snyder BA, et al. Concomitant renal revascularization with aortic surgery: are the risks of combined procedures justified? *Am Surg.* 2000;66:768-772.
- DeRose G. Are simultaneous aortic reconstruction and renal revascularization safe and effective? *J Cardiovasc Surg.* 1991;32:648-651.
- Cambria RP, Brewster DC, L'Italien, et al. Simultaneous aortic and renal artery reconstruction: evolution of an eighteen-year experience. *J Vasc Surg.* 1995;21:916-924.
- Reilly JM, Rubin BG, Thompson RW, et al. Long-term effectiveness of extraanatomic renal artery revascularization. *Surgery.* 1994;116:784-790.
- Dougherty MJ, Hallett JW Jr, Naessens J, et al. Renal endarterectomy vs. bypass for combined aortic and renal reconstruction: is there a difference in clinical outcome? *Ann Vasc Surg.* 1995;9:87-94.
- Wong JM, Hansen KJ, Oskin TC, et al. Surgery after failed percutaneous renal artery angioplasty. *J Vasc Surg.* 1999;30:468-482.