

# CASE REPORT: SECONDARY INTERVENTION WITH THE CROSSER® RECANALIZATION CATHETER

## A closer look at recanalizing a restenotic occlusion.

BY FRANKLIN S. YAU, MD, RPVI

A 72-year-old woman with a history of type 2 diabetes, hypertension, hyperlipidemia, and peripheral vascular disease developed dry gangrene of the left great toe as well as rest pain over a 5-week period. She had a history of bilateral femoral stent placements and a 20 pack per year smoking history but quit 5 years ago. She did not have documented coronary artery disease or stroke and did not report chest pain, shortness of breath with exertion, or leg swelling. She had bilateral calf claudication at about one-half block.

Examination revealed a frail but alert woman brought in on a wheelchair. She had palpable femoral pulses on both sides but nonpalpable popliteal and pedal pulses. On the right side, she had 2-cm dry gangrene on the tip of her hallux. There was no drainage or surrounding erythema. She did have dependent rubor, which would resolve with leg elevation. Neurologic evaluation demonstrated decreased sensitivity to light touch in the feet bilaterally.

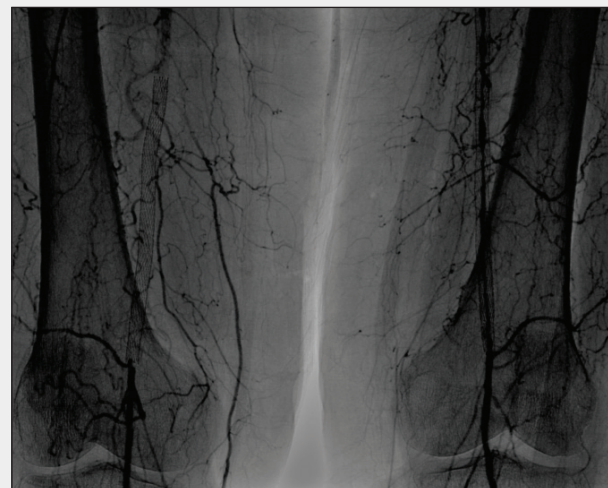Ankle-brachial index was 0.55, with toe pressure of 17. Arterial duplex ultrasound confirmed right superficial femoral artery (SFA) stent occlusion with reconstitution of the popliteal artery above the knee. White blood cell count was 8.2, and creatinine was 1.1 mg/dL.

She underwent diagnostic peripheral angiography, which demonstrated an occluded right SFA stent with reconstitution of the above-knee popliteal artery. There was two-vessel runoff through the anterior tibial and peroneal artery (Figure 1).

We positioned a crossover sheath into the right SFA and administered therapeutic intravenous heparin. Initial attempts to cross the chronic total occlusion (CTO) with a Glidewire™ (Terumo Interventional Systems) and catheter were unsuccessful due to a calcified cap. Attempts at creating a subintimal plane only advanced our catheters outside the implanted femoral stent.

Our next maneuver involved using the Crosser® Catheter S6 (Bard Peripheral Vascular, Inc.) coupled with the Usher® Support Catheter (Bard Peripheral Vascular, Inc.). We positioned the Usher® Catheter at the center of the CTO cap. The Crosser® Catheter was able to successfully penetrate the calcified cap and continued intraluminally through the distal cap. The Usher® Catheter was advanced over the Crosser® Catheter into the reconstituted popliteal artery without difficulty (Figure 2).

We exchanged out for a 0.014-inch wire and performed mechanical atherectomy using a 2.4-mm Jetstream™ device (Bayer). Intravascular ultrasound revealed that the vessel size was 5.4 mm. We predilated the occlusion with a 5-mm Vascutrak® PTA Catheter (Bard Peripheral Vascular, Inc.) in



**Figure 1. Diagnostic angiogram showing an occluded left SFA stent and extensive disease in the left SFA.**

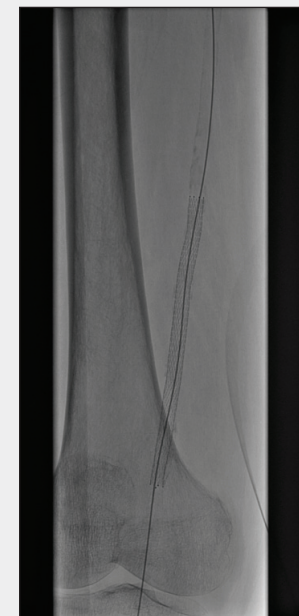
preparation for stent placement using a Lifestent® Vascular Stent (Bard Peripheral Vascular, Inc.). Completion angiography and intravascular ultrasound demonstrated no residual stenoses, dissections, occlusions, or embolizations (Figure 3).

Two-vessel runoff was preserved. Routine mechanical compression was performed, and the patient tolerated the procedure without immediate complications.

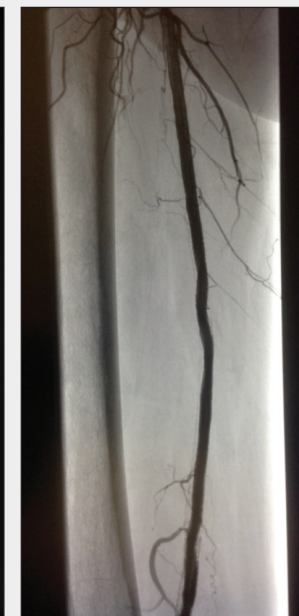### DISCUSSION

Restenosis is a common clinical scenario resulting from endovascular treatment with balloon angioplasty and intra-arterial stenting, with complications of arterial occlusion, elastic recoil, dissection, or residual stenosis. Restenosis due to endothelial injury from PTA progresses through three phases: acute vessel recoil, negative remodeling, and neointimal hyperplasia.<sup>1</sup> Although peripheral stenting can improve vessel recoil and negative remodeling, thrombus formation and neointimal hyperplasia are the primary causes of in-stent restenosis. Early reocclusions are usually the result of acute thrombosis, whereas late reocclusions are a result of neointimal hyperplasia.

Restenosis rates have been widely reported for balloon angioplasty of femoropopliteal lesions to be > 50% at 1 year, with the rate varying based on the type of lesion. One meta-analysis found that 3-year patency rates after PTA ranged from 61% in claudicants with stenosis to 30% for CLI patients with CTOs.<sup>2</sup> While stenting can mitigate vessel recoil and negative remodeling, in-stent restenosis occurs



**Figure 2. The Crosser® Catheter and Usher® Support Catheter traverse the proximal and distal CTO caps.**



**Figure 3. Completion angiogram after successful treatment with atherectomy, balloon angioplasty, and stenting.**

at a rate of 19% to 37% at 1 year.<sup>3-6</sup> Secondary interventions for nonocclusive restenosis include the use of repeat balloon angioplasty, cutting-balloon angioplasty, repeat stenting with either a bare-metal stent or covered stent, and atherectomy. Secondary interventions for CTOs can be more problematic. In our experience, restenotic occlusions tend to be quite fibrotic. In addition, the cap of the occluded lesion can sometimes be severely calcified, especially in patients with diabetes or end-stage renal disease.

In our experience, recanalization of a restenotic occlusion is usually more difficult than the treatment of a de novo TASC D lesion of an SFA that has not undergone previous intervention. Advancement of the wire and crossing catheter in the true lumen or the subintimal plane is usually difficult due to the fibrotic and sometimes calcified nature of the occlusion. Often, the wire and catheter enter the adventitial space outside the lumen and cannot be negotiated to remain inside the lumen.

In this particular patient, initial attempts at penetrating the calcified cap were unsuccessful; therefore, the Crosser® Catheter was used to treat this lesion. The Crosser® Catheter is a CTO recanalization system that uses a specialized catheter to transmit high-frequency vibra-

tions at approximately 20,000 cycles/sec at an amplitude of 20  $\mu$ m to penetrate the hard calcified cap. It works like a small jackhammer. The mechanism of action maximizes its ability to penetrate inelastic surfaces such as calcium and minimizes its impact on elastic structures such as the vessel wall. Thus, the catheter is more likely to stay in the true lumen while avoiding perforation of the vessel. The PATRIOT clinical study demonstrated that the Crosser® Recanalization Catheter was successful in traversing CTOs that were unable to be crossed with a conventional guidewire.<sup>7,8</sup> Moderate to severe calcium was noted in 75% of these patients (n = 85), and no clinical perforations related to the Crosser® Catheter were observed. In addition, 15.3% of the patients had restenotic occlusions, having previously received endovascular treatment at the target lesion site.<sup>8</sup>

In our case, an occluded stent was resistant to a conventional guidewire and catheter method to cross the lesion. In addition, guidewire manipulation frequently creates a channel outside the occluded stent, thereby making successful secondary intervention challenging. The Crosser® Recanalization Catheter offered an elegant percutaneous solution to this difficult secondary intervention vascular case. ■

*Franklin S. Yau, MD, RPVI, is a vascular surgeon with Vanguard Vascular & Vein in Dallas, Texas. Dr. Yau has disclosed that he is a consultant for Bard Peripheral Vascular, Inc. Dr. Yau may be reached at [yau@thevanguardway.com](mailto:yau@thevanguardway.com).*

*The opinions and clinical experiences presented herein are for informational purposes only. The results from this case study may not be predictive for all patients. Individual results may vary depending on a variety of patient specific attributes. The physician has been compensated by Bard Peripheral Vascular, Inc. for the time and effort in preparing the above case study for Bard's further use and distribution.*

1. Dieter RS, Laird JR. Overview of restenosis in peripheral arterial interventions. *Endovasc Today*. 2004;10:36-38.
2. Muradin, GSR, Bosch, JL, Stijnen, et al. Balloon dilatation and stent implantation for treatment of femoropopliteal arterial disease: Meta-analysis. *Radiology*. 2001;221:137-145.
3. Schillinger M, Sabeti S, Loewe C, et al. Balloon angioplasty versus implantation of nitinol stents in the superficial femoral artery. *N Engl J Med*. 2006;354:1879-1888.
4. Laird JR, Katzen BT, Scheinert D, et al. Nitinol stent implantation versus balloon angioplasty for lesions in the superficial femoral and proximal popliteal artery: twelve-month results from the RESILIENT randomized trial. *Circ Cardiovasc Interv*. 2010;3:267-276.
5. Schillinger M, Sabeti S, Dick P, et al. Sustained benefit at 2 years of primary femoropopliteal stenting compared with balloon angioplasty with optional stenting. *Circulation*. 2007;115:2745-2749.
6. Laird JR, Katzen BT, Scheinert D, et al; RESILIENT Investigators. Nitinol stent implantation vs. balloon angioplasty for lesions in the superficial femoral and proximal popliteal arteries of patients with claudication: three-year follow-up from the RESILIENT randomized trial. *J Endovasc Ther*. 2012;19:1-9.
7. PATRIOT evaluates FlowCardia's Crosser to mediate CTO recanalization. *Endovascular Today*. October 22, 2009.
8. Peripheral Approach to Recanalization in Occluded Totals™ (PATRIOT) Clinical Trial. Clinical data on file.

## SAFETY INFORMATION

Prior to use, please see the complete "Instructions for Use" for more information on Indications, Contra-indications, Warnings, Precautions, Adverse Events, and Operator's Instructions. Caution: Federal Law (USA) restricts these devices to sale by or on the order of a physician.

### CROSSER® CTO RECANALIZATION CATHETER

#### INDICATIONS FOR USE

The Crosser® Recanalization System is indicated to facilitate the intraluminal placement of conventional guidewires beyond peripheral artery chronic total occlusions via atherectomy. The Crosser® Catheter is only intended for use with the Crosser® Generator. Refer to the Crosser® Generator Manual of Operations for proper use.

#### CONTRAINDICATIONS

The device is contraindicated for use in carotid arteries.

#### WARNINGS AND PRECAUTIONS

- Never advance or withdraw the Crosser® Catheter without proper fluoroscopic guidance.
- It is not recommended to use the Crosser® Catheter over wires which have polymer-jacketed distal ends.
- When using the Crosser® Catheter 14S or 14P with the MicroSheath® XL Support Catheter Tapered, the Crosser® Catheter can be advanced approximately 15cm from the tip of the support catheter before resistance is encountered due to the taper on the Crosser® Catheter aligning with the taper on the support catheter. A taper lock-up marker (single marker on the Crosser® Catheter shaft) is located 127cm from the distal tip for the 146cm Crosser® Catheter and 87cm from the distal tip for the 106cm Crosser® Catheter. The taper lock-up marker can be used as an indicator that the tapers on the catheters are nearing alignment; advance the Crosser® Catheter slowly. Do not continue to advance the Crosser® Catheter if resistance is encountered.
- When using the Crosser® Catheter in tortuous anatomy, the use of a support catheter is recommended to prevent kinking or prolapse of the Crosser® Catheter tip. Kinking or prolapse of the tip could cause catheter breakage and/or malfunction.

### SIDEKICK® AND USHER® SUPPORT CATHETERS

#### INDICATIONS FOR USE

The Sidekick® and Usher® Support Catheters are single lumen catheters intended to create a pathway for other devices in the peripheral vasculature.

#### CONTRAINDICATIONS

The Sidekick® and Usher® Catheters are contraindicated for use with cutting/scoring balloons, pediatrics, neonatal and neurovascular patients.

#### WARNINGS AND PRECAUTIONS

- When the catheter is exposed to the vascular system, it should be manipulated while under high-quality fluoroscopic observation. Movement of the product without fluoroscopic guidance may result in damage to the product or vasculature or cause vessel perforation.
- Manipulating or torquing a product against resistance may cause damage to the product or vasculature or cause vessel perforation. Never advance, withdraw or torque a catheter which meets resistance.
- Verify compatibility of the product's inner and outer diameters and lengths with other devices before use.

- Refer to package label for tip shape for the Sidekick® and Usher® Catheters. Do not attempt to manipulate or re-shape the tip configurations.

### VASCUTRAK® PTA DILATATION CATHETER

#### INDICATIONS FOR USE

The Vascutrak® PTA Dilatation Catheter is intended to dilate stenoses in the iliac, femoral, ilio-femoral, popliteal, infra-popliteal, and renal arteries and for the treatment of obstructive lesions of native or synthetic arteriovenous dialysis fistulae. This device is also recommended for post dilatation of balloon expandable stents, self-expanding stents, and stent grafts in the peripheral vasculature.

#### CONTRAINDICATIONS

The Vascutrak® PTA Catheter is contraindicated where there is the inability to cross the target lesion with a guidewire and for use in the coronary or neuro vasculature

### DORADO® PTA DILATATION CATHETER

#### INDICATIONS FOR USE

Dorado® Balloon Dilatation Catheters are recommended for Percutaneous Transluminal Angioplasty (PTA) of the renal, iliac, femoral, popliteal, tibial, peroneal, and subclavian arteries and for the treatment of obstructive lesions of native or synthetic arteriovenous dialysis fistulae. This device is also recommended for post-dilatation of balloon expandable and self expanding stents in the peripheral vasculature. This catheter is not for use in the coronary arteries.

#### CONTRAINDICATIONS

None known

### LIFESTENT® VASCULAR STENT SYSTEM

#### INDICATIONS FOR USE

The LifeStent® Vascular Stent System is intended to improve luminal diameter in the treatment of symptomatic de-novo or restenotic lesions up to 240mm in length in the native superficial femoral artery (SFA) and proximal popliteal artery with reference vessel diameters ranging from 4.0-6.5mm.

#### CONTRAINDICATIONS

The LifeStent® Vascular Stent System is contraindicated for use in:

- Patients with a known hypersensitivity to nitinol (nickel, titanium), and tantalum.
- Patients who cannot receive recommended anti-platelet and/or anti-coagulation therapy.
- Patients who are judged to have a lesion that prevents complete inflation of an angioplasty balloon or proper placement of the stent or stent delivery system.

#### ADVERSE EVENTS

As with most percutaneous interventions, potential adverse effects include: Bleeding which may require transfusion or surgical intervention, Hematoma, Perforation, Dissection, Guidewire entrapment and/or fracture, Hypertension / Hypotension, Infection or fever, Allergic reaction, Pseudoaneurysm or fistula Aneurysm, Acute reclosure, Thrombosis, Ischemic events, Distal embolization, Excessive contrast load resulting in renal insufficiency or failure, Excessive exposure to radiation, Stroke/CVA, Restenosis, Repeat catheterization / angioplasty, Peripheral artery bypass, Amputation, Death or other bleeding complications at access site.