

# Endovascular TODAY

December 2014

## DAART

Directional Atherectomy

Anti-Restenotic Therapy

Why Directional  
Atherectomy Matters With  
Anti-Restenotic Therapies

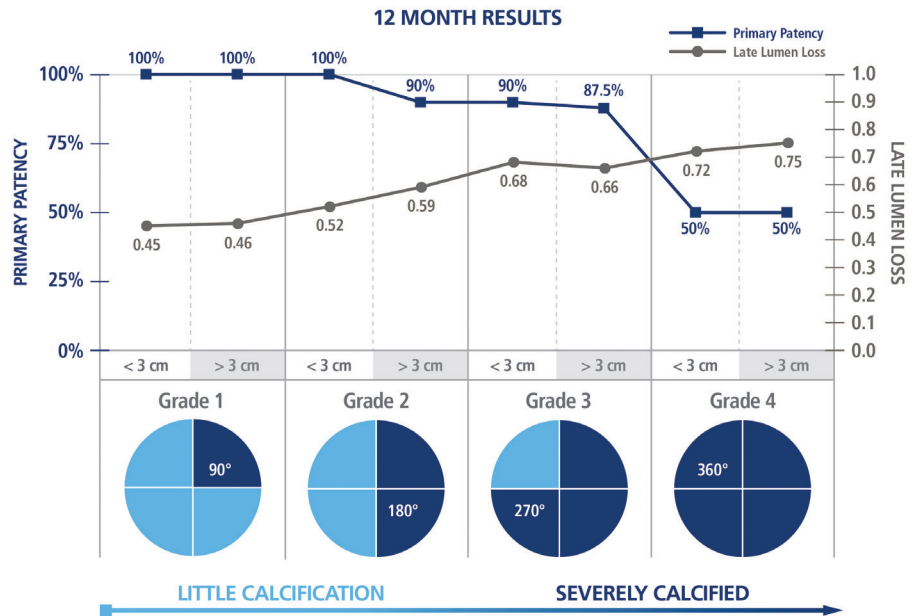


# Introduction

Within the past decade, there have been many technological advancements in the endovascular treatment of peripheral arterial disease (PAD) that have led to improvements in earlier interventional treatments. These less invasive procedures aim to preserve future treatment options and ultimately result in better patient outcomes. Even with these advancements, there still exists a number of patient and lesion types that pose treatment challenges, particularly the presence of calcified lesions as well as longer and more advanced lesions with high plaque burden.

Calcium is a prevalent real-world treatment challenge that is widely seen across many chronic conditions, such as diabetes and renal disease. It is a recognized predictor of lower procedural success and reduced long-term outcomes. One of the issues in treating calcium is its resistant nature. When dilated with a standard angioplasty balloon, a calcified lesion causes balloon overstretching in non-diseased tissue with subsequent vascular dissections, perforations, and recoil. This can lead to unintended bailout stenting that can limit both acute procedural and long-term success.<sup>1</sup>

Current drug-coated balloon (DCB) results are promising; however, undilatable calcium was an exclusion criterion in many of the DCB studies. DCBs do not address the physical limitations of dilating resistant plaque. More importantly, the presence of calcium acts as a mechanical barrier that may prevent an adequate concentration



**Figure 1. Twelve-month results demonstrating greater late lumen loss and lower patency with increased calcification.**

of drug and homogenous drug uptake from absorbing into the vessel wall. Fanelli et al evaluated a subset of 60 patients with lower extremity calcified lesions from the DEBELLUM study. The degree of calcification was determined by circumferential distribution of calcium via CT angiography and intravascular ultrasound, and length of calcified plaque was measured with digital subtraction angiography. All patients were treated with DCBs. This study demonstrated greater late lumen loss and lower 12-month patency in patients with increased calcification (Figure 1).<sup>2</sup>

Increased lesion length has also been identified as an independent predictor of restenosis in PAD treatment.<sup>3</sup> Incidence of resteno-

sis rates increase in longer lesions across all modalities. This has been demonstrated in multiple studies across all types of lower extremity interventions, including angioplasty balloons, stenting, atherectomy, and DCBs.

Treatment of both calcified lesions and long lesions continues to present a clinical challenge for the practicing interventionalist. A treatment option known as DAART (Directional Atherectomy plus Anti-Restenotic Therapy [DCB]) was recently studied in two separate clinical trials—DEFINITIVE AR and Cioppa et al. In this procedure, plaque is first removed using directional atherectomy, followed by drug delivery using a paclitaxel-coated balloon. ■

# Clinical Perspectives on DAART

*Endovascular Today recently gathered feedback from several endovascular experts in the United States to discuss current advancements in the treatment of peripheral arterial disease as well as findings from clinical trials conducted on the use of directional atherectomy used adjunctively prior to DCBs. Their observations and recommendations were based upon relevant clinical evidence and their own practice experience.*



**Samir Germanwala, DO**

Director, Endovascular and Peripheral Interventions  
Heart and Vascular Institute of Longview  
Longview Regional Medical Center  
Longview, Texas



**Eric C. Scott, MD**

Director, Outpatient Endovascular Center  
The Iowa Clinic  
West Des Moines, Iowa  
Adjunct Clinical Assistant Professor of Surgery  
University of Iowa, College of Medicine



**Mehdi Shishehbor, DO, MPH**

Director, Endovascular Services  
Cleveland Clinic  
Cleveland, Ohio

## **Q** How will you use DCBs now that they are available?

**Dr. Shishehbor:** I will use them judiciously for short lesions, stenotic lesions, and for the SFA/popliteal artery where a stent has been placed. I do not plan on using them in instances of heavy calcification, if there is already a dissection, or if there is a need for subintimal recanalization and the use of a re-entry device. Basically, any situation in which I think either a stent is required or that the drug-coated technology will not be able to address the calcification.

**Dr. Scott:** I'll begin using these balloons in the same manner in which they were studied: TASC A, B, and C de novo lesions. I must admit, however, that my real interest in anti-restenosis therapy is for use in the more difficult cases we all face on a routine basis: TASC D lesions, lesions with early restenosis, and cases that require multimodality therapy (stenting or atherectomy). My

hope is that we can evaluate the effectiveness of DCBs in these scenarios within clinical trials.

## **Q** Early data from the DEBELLUM study indicate that circumferential calcium may be a barrier to drug uptake. Do you think that calcified plaque represents a barrier to optimal drug delivery and absorption?

**Dr. Germanwala:** Yes, I believe that circumferential calcium may be a barrier to drug uptake. This continues to represent a significant challenge to us and is still a barrier to optimal drug delivery and absorption into the adjacent tissues.

**Dr. Scott:** Dense, circumferential calcification of the intima and media is perhaps the greatest barrier to effectiveness in any of our endovascular treatment options. Angioplasty alone is often insufficient to establish a satisfactory flow lumen. Adding drug to the balloon does not change this. Subsequent stent placement does not guarantee a satisfactory lumen either. In these instances, I preferentially begin treatment with atherectomy. Why? Because atherectomy can provide luminal gain in heavily calcified arteries in a way that angioplasty and stenting simply cannot. Whether atherectomy prior to DCB in heavily calcified lesions sets the stage for more effective drug penetration will have to be studied further.

**Dr. Shishehbor:** I agree that calcification is a major barrier, not only from the standpoint of drug delivery but also from the standpoint that DCBs do not address acute issues with angioplasty, which include dissection, recoil, and perforation. A DCB is a balloon with a drug directed to address issues related to restenosis in the mid- to long-term time frame. There is nothing special about DCBs with regard to the acute issues that we deal with when we do angioplasty at the time of intervention. Thus, I do not think DCBs will perform well in the setting of heavy calcification because those are usually the vessels that

don't do well with angioplasty acutely and require stenting. Those vessels typically do better when we perform some form of atherectomy. I think potentially, if we can deal with the calcification with atherectomy, and then offer DCB technology, that may be a useful approach. I appreciate the randomized data from the DEFINITIVE AR trial looking at this issue where directional atherectomy did achieve much larger luminal gain in moderate calcification.

**Q What are your thoughts regarding DAART (directional atherectomy plus DCB)? In which clinical applications do you think DAART may be best utilized, and do you think DAART will change your approach to using atherectomy devices?**

**Dr. Scott:** The recent publication of DEFINITIVE LE, demonstrating 78% primary patency in approximately 600 patients with claudication, really helped define where we are in terms of the effectiveness of directional atherectomy. Let's not forget, most physicians using atherectomy today are doing so as a competitive approach to primary stenting, so if we're going to evaluate the effectiveness of putting paclitaxel on stents, the atherectomy proponents of the world desperately want to know if DCB after atherectomy improves atherectomy results as well.

In my own practice, I think DAART will be beneficial in lesions that prove difficult to completely debulk, and in patients who have had an early recurrence of stenosis after previous atherectomy.

**Dr. Germanwala:** Restenosis remains a nemesis despite the different treatments in the femoropopliteal arteries. As we saw in the DEBELLUM trial, circumferential calcified plaque burden negatively impacts the effectiveness of DCBs. Reducing the plaque burden prior to the delivery of the DCB is believed to allow better drug permeability and treatment for restenosis. In turn, this would improve upon target limb revascularization, late lumen loss, ankle-brachial index, and freedom from amputation. Intuitively, we believe that using directional atherectomy followed by a DCB would have a much-improved 1-year patency and provide better inhibition of restenosis. In the DEFINITIVE AR trial, directional atherectomy with a DCB demonstrated better technical success and residual plaque burden than a DCB alone. I would use directional atherectomy adjunctively with a DCB. It has a higher procedural success rate, and so far, the patient questionnaires and clinical signs are in favor of it. DAART will not change my approach on the atherectomy side because I believe the DEFINITIVE LE data and continue to promote the use of atherectomy without permanent vessel-changing modalities such as stenting. The use of DCB with atherectomy is novel and exciting, and I am eager to add it to my arsenal.

"Atherectomy can provide luminal gain in heavily calcified arteries in a way that angioplasty and stenting simply cannot."

– Dr. Scott

**Dr. Shishebor:** I think the randomized data from DEFINITIVE AR are encouraging. We obviously need larger studies here in the United States; however, the concept is very appealing. One of the issues, as always, is cost. How are we going to deal with the situation of crossing these lesions and paying for atherectomy, DCB, and then if you have a dissection, the need for a stent? A very interesting finding from DEFINITIVE AR was the much lower dissection and bailout stenting rates in the DAART arm compared to DCB alone. This alone may justify the cost associated with atherectomy by using less stents. Furthermore, luminal gain was much higher and translated into higher patency rates with directional atherectomy followed by DCB therapy. This, if replicated, also justifies the upfront cost associated with atherectomy. Lastly, in the setting of CLI, the additional acute luminal gain may allow enough time to heal ulcers and provide a higher volume of blood flow compared to a DCB alone.

**Q DCB data presented to date are mostly drawn from shorter, sub-10-cm lesions. Studies out of Germany in longer lesions show a decrease in patency into the mid-70% range in 15- to 20-cm lesions. Do you think long, diffuse disease will be an opportunity for DAART to improve upon these numbers?**

**Dr. Germanwala:** Long SFA lesions have a very high restenosis rate (approximately 48% at 1 year). The five major DCB trials had an average lesion length of 6 to 7 cm. The DCB result of a real world registry for TASC C and D lesions has shown promising results. Of course, the longer the lesion, the higher the probability that restenosis will occur.

Yes, of course, I think DAART will be instrumental in the treatment of TASC C and D lesions. As previously mentioned, DAART will dramatically improve our outcomes; we are seeing better outcomes with directional atherectomy, and the addition of DCB will only further the improvement.

**Dr. Scott:** We all want to know just how complementary DCBs will be to directional atherectomy. We know from both angioplasty and stenting trials that patency diminishes with increasing lesion length, and this will be



true for DCBs as well. I suspect that to achieve significant improvements in short- and long-term patency in lesions from short to long, we will have to find ways to use complementary technologies; DAART offers this possibility.

**Dr. Shishehbor:** It is really hard to say, to be perfectly honest. I found performing atherectomy on very long lesions (> 20 cm) to be a little bit of a challenge. However, more recent data have come out from DEFINITIVE AR and other studies showing the safety and efficacy of atherectomy in longer lesions.

**Q** After seeing the DEFINITIVE AR data, what do you think are the key takeaways, and how would you apply the study findings into your practice?

**Dr. Scott:** I think there are two key findings in this randomized, controlled pilot study of DCB alone versus DAART.

The first is that directional atherectomy seems to improve the technical success of these procedures. In the study, DAART achieved  $\leq 30\%$  stenosis in 90% of lesions, while the DCB-alone arm (without directional atherectomy) achieved  $\leq 30\%$  stenosis in only 64% of lesions. Flow-limiting dissections were also more frequent in the DCB-alone arm (19% vs 2%).

The second important finding is that there was a clear trend toward improved angiographic primary patency at 1 year in lesions longer than 10 cm and in calcified lesions. This is the kind of data we had hoped to see. Today, we can achieve technical success in the vast majority of our cases, but restenosis remains our greatest challenge, particularly in long and/or heavily calcified lesions. We desperately need therapies targeted at restenosis, and DCB appears to be able to deliver. With the recent availability of DCBs in the United States, I've begun using a DAART strategy in patients with restenotic lesions and in patients at high risk for restenosis.

**Dr. Germanwala:** First off, I want to say this is a great step in the right direction for clinical support of the DAART concept. This is an emerging treatment technique for determining optimal future treatment options to help patients suffering from PAD.

It is important to note that this is a hypothesis-generating study. Although there are limitations including the sample size, and the fact that the DCB utilized is no longer marketed, I am still very encouraged by the pilot trial (DEFINITIVE AR) and am eager to see similar positive results in continuing trials. DAART is a therapy that I am proud to offer my patients, particularly those with restenosis and higher TLR rates.

“Directional atherectomy with DCB will dramatically improve our outcomes; we are seeing better outcomes with directional atherectomy, and the addition of DCB will only further the improvement.”

– Dr. Germanwala

I have been using DAART therapy in some of my complex cases, and patients have achieved a high technical success, as shown in the DEFINITIVE AR trial. Obviously, long-term patency and outcomes are so important. It would be great to have more long-term data to support the adjunctive use of directional atherectomy with antirestenotic therapy. One day, it would be great to see a head-to-head trial including three arms comparing directional atherectomy versus DAART versus DCB to ensure we are all choosing the appropriate long-term treatment options for our patients.

**Q** Does it matter what type of atherectomy device you use with a DCB if your goal is to achieve < 30% residual stenosis as reported in DEFINITIVE AR?

**Dr. Scott:** We learned in DEFINITIVE AR that primary patency in the DAART arm was 25% higher at 1 year if thorough directional atherectomy was performed prior to DCB use. By “thorough,” I mean that lesions were treated by directional atherectomy to a stenosis of  $\leq 30\%$ . If after directional atherectomy there remained a stenosis of > 30%, patency at 1 year was nearly identical to DCB alone! So, this is an early indication that directional atherectomy to measurably remove atheroma is important. It directly translated to improved patency.

It's important to remember that our various peripheral therapies are, in the end, just tools. There are various methods of performing an atherectomy (directional, orbital, laser) and even more variations in how physicians use these devices. DEFINITIVE AR provides a meaningful benchmark, however, for atherectomy users. The message is simple: Maximal primary patency following DAART requires achieving good luminal gain, a residual stenosis of  $\leq 30\%$  prior to proceeding with a DCB. DCBs cannot make up the difference when atherectomy does a poor job of debulking a lesion.

**Dr. Germanwala:** Yes, the data obviously show that “not all atherectomy devices are created equal,” and because evidence-based medicine is the key to selecting the right treatment options for patients, having a device such as the TurboHawk™ device supported by a large trial

and high patency outcomes solidifies this as my choice for directional atherectomy. This is an optimal cutter that can treat a wide variety of lesions, including those with calcified plaque. The acute luminal gain achieved with this device as a “stand-alone” therapy is still higher than any other atherectomy devices available, as referenced in DEFINITIVE LE.

**Q Please comment on the findings in DEFINITIVE AR regarding the challenges of calcium. When it comes to atherectomy, is there a class effect, or does it matter which atherectomy device is used to debulk prior to DCB insertion?**

**Dr. Scott:** The data from DEFINITIVE AR on the value of thorough debulking of the lesion challenge us all. For directional atherectomy users, it challenges us to use the device with directed passes until a  $\leq 30\%$  stenosis remains. This can take a considerable amount of time and effort in long, heavily calcified lesions and is not always achievable. Orbital atherectomy devices can sometimes more efficiently tackle such lesions but are constrained by their orbit in terms of luminal gain and rarely achieve a  $\leq 30\%$  stenosis on their own. Laser atherectomy is similarly constrained and is further challenged by heavily calcified lesions.

It’s also important not to forget what open vascular surgery has demonstrated in regard to the value of atheroma removal. Whether in the carotid artery, the infrarenal aorta, or the common femoral artery, some

“I think the data from DEFINITIVE LE and DEFINITIVE AR (DAART) have been promising. The rates of dissection were low, and the device did well in these studies; with more than 900 (combined) patients overall.”

– Dr. Shishehbor

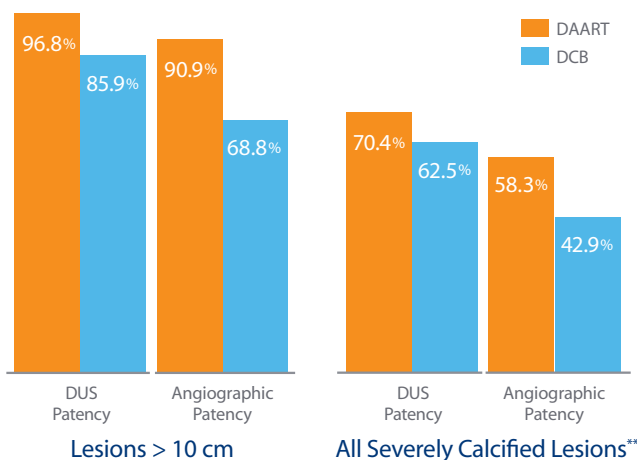
of the highest long-term patency rates reported for any vascular procedure are achieved when complete removal of the atheroma is performed. Surgical endarterectomy has already confirmed the value of luminal gain; the same is likely true for percutaneous mechanical atherectomy, whether followed by plain balloon angioplasty or DCB.

**Dr. Germanwala:** The DEFINITIVE AR trial showed that severely calcified lesions did better with DAART versus DCB therapy. Calcium continues to remain a nemesis in the acute success and also leads to higher target lesion revascularization rates.

The DEBELLUM trial showed that calcified plaque might limit the drug effect. The 1-year patency rates quickly fell from 90% to 50% when treating a vessel with calcified plaque on multiple quadrants. This suggests directional atherectomy may be the best treatment

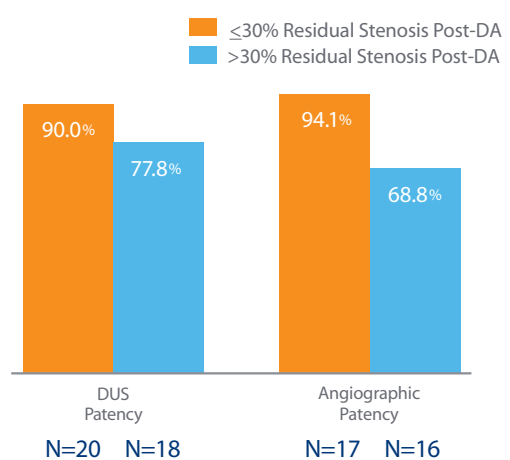
Long and Severely Calcified Lesions

DEFINITIVE AR suggests added patency benefit of using DA in long lesions and severely calcified lesions.



$\leq 30\%$  Residual Stenosis

DEFINITIVE AR suggests improved patency when a higher volume of plaque is removed with DA prior to DCB.



\*\*Per Core Lab assessment, “All severe CA++” group includes all patients treated with DAART or DCB therapy, including randomized and nonrandomized patients with severe calcium.

**Figure 2. Twelve-month patency outcomes in patients who received directional atherectomy followed by a DCB versus patients who received DCB only.**

option because it not only has the versatility to debulk varying lesion morphologies, but also has the ability to remove hardened plaque, thus resulting in a combination of higher acute luminal gain and the ability to prepare the vessel for optimal drug uptake of the DCB.

Because increased luminal gain and reduced late lumen loss are the two key factors that offer the best patency rates for long-term treatment success in patients with PAD, directional atherectomy will continue to be at the forefront of my treatment strategy as newer DCBs are released and further data become available.

### **Q** Do you see an opportunity for DAART to decrease the need for bailout stenting and flow-limiting dissections associated with DCBs?

**Dr. Scott:** Absolutely. One of the key benefits of directional atherectomy is that it creates luminal gain by removal of atheroma instead of relying on balloon angioplasty, which is prone to unpredictable dissection or suboptimal luminal gain. In the Zilver PTX trial, this resulted in a bailout stent rate in the angioplasty arm of approximately 50%. Contrast this to results of the DEFINITIVE LE study in which the bailout stent rate in 800 patients treated with directional atherectomy was only 3%. Directional atherectomy followed by treatment with DCB should have a bailout stent rate of < 5% as well. The DAART approach to lesions in no-stent zones could become the most effective and safest approach to these challenging lesions.

**Dr. Germanwala:** In most DCB trials, the bailout stent rate was between 0% and 24%, and with the atherectomy trials, most bailout stent rates were 1% to 7%. It was postulated that the bailout stent rate would be somewhere between these two ranges. It is clear, however, that atherectomy prior to the balloon-induced barotrauma decreases the significant flow-limiting dissections. Vascular stenting has a role in the treatment of PAD but is fraught with many long-term complications.

Across the continuum of PAD care, I believe it is imperative to treat the native artery as long as possible with therapy that doesn't irreversibly change the vessel morphology. Therefore, directional atherectomy plus DCB will be superior to stents, stent grafts, and surgical revascularization for maintenance of vessel morphology, allowing for more treatment options without leaving anything behind.

**Dr. Shishehbor:** That's a tough question. I think the data from DEFINITIVE LE and DEFINITIVE AR (DAART) have been promising. The rates of dissection were low, and the device did well in these studies with more than

900 (combined) patients overall. It is useful to perform directional atherectomy first, followed by DCB. Although data from DEFINITIVE AR appear to support this concept, we do need larger studies to reproduce these findings. Overall, the rate of dissections (2% vs 19%) in the DAART arm was much lower, and there was no bailout stenting, albeit the sample size was small. These findings should encourage a larger-sized clinical trial in the United States with focus on the economic benefit in conjunction with clinical efficacy and safety.

### CONCLUSION

Despite the recent introduction of drug-coated balloons in the United States, treatment of severe calcium and long lesions remains challenging for interventionalists. The DAART procedure, a strategy utilizing directional atherectomy adjunctively with a paclitaxel DCB, may be the treatment solution in these challenging real-world clinical (patient) scenarios.

This strategy was utilized successfully in the Cioppa et al study where a 1-year patency rate of 90% (measured via intravascular ultrasound) was achieved in a small cohort of 30 patients.<sup>1</sup> The larger, prospective, randomized DEFINITIVE AR study appears to have reproduced these results with 1-year patency rates in longer lesions (> 10 cm) of 96.8% by duplex ultrasound and 90.9% by angiography. Patency rates in severely calcified lesions also appear to have improved with DAART versus DCB alone.

Furthermore, the volume of lumen gain achieved by debulking and removing the plaque using directional atherectomy prior to DCB insertion/inflation appears to be an important first step to be able to increase overall patency rates. Initial debulking of the vessel to  $\leq$  30% stenosis with directional atherectomy followed by DCB use led to more than 90% patency rate versus 68% with a DCB alone (angiographic patency). With higher volumes of plaque removal, patency improved (Figure 2).

These two recent studies suggest an added benefit for DAART in long and calcified lesions, which were not observed in the DCB cohorts. Further investigation in even larger, prospective, statistically powered randomized trials is warranted. The DEFINITIVE AR study is now following patients for an additional 12 months to assess durability of the results out to 24 months. ■

1. Cioppa A, Stabile E, Popusoi, G, et al. Combined treatment of heavy calcified femoro-popliteal lesions using directional atherectomy and a paclitaxel coated balloon: one-year single centre clinical results. *Cardiovasc Revasc Med.* 2012;13:219-223.

2. Fanelli F, Cannavale A, Gazzetti M, et al. Calcium burden assessment and impact on drug-eluting balloons in peripheral arterial disease. *Cardiovasc Intervent Radiol.* 2014;37:898-907.

3. Fanelli F, Cannavale A, Boatta E, et al. Lower limb multilevel treatment with drug-eluting balloons: 6-month results from the DEBELLUM randomized trial. *J Endovasc Ther.* 2012;19:571-580.

Covidien's directional atherectomy devices (HawkOne™, TurboHawk™ and SilverHawk™) are intended for use in atherectomy of the peripheral vasculature. Covidien's directional atherectomy devices are contraindicated for in-stent restenosis of the peripheral vascular, and for coronary, carotid, iliac or renal vasculature.

The physicians interviewed are paid consultants of Covidien LP and received compensation for this article.

COVIDIEN, COVIDIEN with logo and Covidien logo are U.S. and internationally registered trademarks of Covidien AG. HawkOne, TurboHawk and SilverHawk are trademarks of a Covidien company. © 2014 Covidien. DA1831122014A