Supplement to

Sponsored by Boston Scientific Corporation

Endovascular TODAY EUROPE

Volume 4, No. 6

REVELUTIONIZING DRUG-ELUTING TECHNOLOGIES

How drug-eluting therapies are shaping a new era of endovascular interventions.

Gary Ansel, MD

Yann Gouëffic, MD

Juan Granada, MD



William Gray, MD

Michael Jaff, MD

Konstantinos Katsanos, MD

Michael Lichtenberg, MD

Antonio Micari, MD

Stefan Müller-Hülsbeck, MD

Dierk Scheinert, MD

Renu Virmani, MD

Thomas Zeller, MD

Boston Scientific
Advancing science for life™

3 **Complexity of SFA Disease Is Driving the Need for Dual Therapy**
A discussion of potential differential indications for drug-eluting devices.
By Prof. Thomas Zeller, MD

5 **The Future of Antiproliferative Therapies for Endovascular Interventions**
Translational findings from the Ranger Paclitaxel-Coated Balloon data.
By Renu Virmani, MD, FACC

7 **The Science Behind Local Drug-Delivery Technologies: The Benefit of Sustained Paclitaxel Release in the SFA**
Sustained drug release is key to maintaining biological effect.
By Juan F. Granada, MD, FACC

9 **Patterns of Restenosis: What Are the Data Telling Us?**
With Michael R. Jaff, DO

11 **Ranger Paclitaxel-Coated PTA Balloon Catheter Clinical Update**
Recent early data from two studies demonstrate the promise of the Ranger DCB.

13 **Sustained Drug Release Optimizes Long-Term Outcomes**
Is the drug-eluting vascular stent a game-changer?
By Prof. Stefan Müller-Hülsbeck, MD, EBIR, FCIRSE, FICA

15 **Are DCBs a Durable Solution?**
A discussion of DCB durability and superiority in the context of 2-year data.
By Gary M. Ansel, MD

17 **The Future of Drug-Eluting Therapies: What Will the Treatment Algorithm Look Like?**
By William A. Gray, MD

21 **Global Perspectives on Drug-Eluting Technologies**
With Prof. Thomas Zeller, MD; Antonio Micari, MD, PhD; Konstantinos Katsanos, MSc, MD, PhD, EBIR; and Yann Gouëffic, MD, PhD

Sponsored by Boston Scientific Corporation

Complexity of SFA Disease Is Driving the Need for Dual Therapy

A discussion of potential differential indications for drug-eluting devices.

BY PROF. THOMAS ZELLER, MD

The global prevalence of peripheral artery occlusive disease (PAOD), defined as an ankle-brachial index < 0.9, was estimated to affect 202 million people worldwide in 2010. Between 2000 and 2008, the incidence of PAOD increased by 28.7% in countries with low and moderate incomes and by 13.1% in those countries with high incomes.[1] This worldwide epidemic increase of PAOD demands effective treatment solutions with regard to durability and costs. The prevalence of endovascular treatment in superficial femoral artery (SFA) therapy in Germany is increasing steadily. In an analysis of all in-hospital patients with a diagnosis of PAOD based on the nationwide German diagnosis-related group system comparing the years 2005 and 2009, there was a 46% increase in endovascular treatment. In contrast, open surgical revascularization procedures are decreasing.[2]

In the claudicant patient population, which represents the majority of symptomatic patients with PAOD, the femoropopliteal artery is the most frequently diseased. This long vessel segment has been considered a "bad conduit" for years due to the unique mechanical challenges to which the vessel segment is exposed.[3] Moreover, extensive vessel wall calcification requires either plaque preparation or the use of dedicated scaffolds. After disappointing experiences with first-generation nitinol bare-metal stents (BMSs), new stent designs and drug-eluting technologies are intended to improve outcomes following femoropopliteal artery treatment. With reported 1-year primary patency peaking at around 80%, long-term patency after use of BMSs still leaves room for improvement. Likewise, target lesion revascularization (TLR) rates for BMSs show room for improvement, with 1-year rates averaging approximately 13% in recent clinical trials.[4-6]

DRUG-COATED BALLOONS VERSUS DRUG-ELUTING STENTS

As with coronary interventions 15 years ago, drug-eluting techniques are now considered the most appropriate endovascular treatment modalities for femoropopliteal artery disease. The current approach to prevent restenosis, and thereby reduce reintervention rates, includes applying an anti-restenotic agent such as paclitaxel to the vessel wall by means of a drug-coated balloon (DCB) or drug-eluting stent (DES). Paclitaxel, which arrests the cell cycle in the G2/M phase, interrupts arterial smooth muscle cell proliferation and migration, as well as extracellular matrix formation.[7] In particular, DCBs

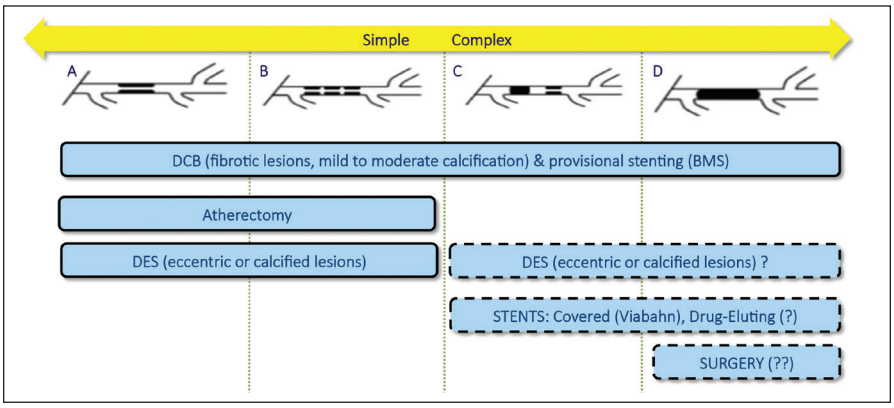

Figure 1. Potential treatment algorithm for femoropopliteal lesions based on published literature data (solid line frame represents level 1 evidence, spotted line frame represents level 2 or 3 evidence). Adapted from J Am Coll Cardiol, Vol 59, Tosaka A, Soga Y, Iida O, et al, Classification and clinical impact of restenosis after femoropopliteal stenting, pg 16-23, Copyright 2012, with permission from Elsevier.

provide an attractive method to locally deliver paclitaxel into the artery wall without the need of a chronically implanted delivery system. Even if those devices are indicated, they can be delivered focally (ie, spot stenting). Following the first positive pilot studies, two large pivotal trials have confirmed the superiority of DCBs over plain old balloon angioplasty in the treatment of TASC II A and B femoropopliteal lesions.[8,9] Even for more complex femoropopliteal lesions (eg, long lesions and in-stent restenosis), single-center studies, global registries, and small randomized studies have shown promising midterm technical and clinical results.

For DESs, follow-up data up to 5 years for the first commercially available polymer-free device (Zilver PTX, Cook Medical) are now published, with excellent clinical outcomes regarding freedom from TLR and improved walking capacity.[10] One limitation of DCBs and polymer-free DESs is that subsequent steps of the restenotic cascade might not be covered by paclitaxel beyond several weeks or months after an angioplasty or stenting procedure. Preclinical studies suggest that paclitaxel is present in the artery wall for only a few weeks at most after exposure to a balloon or stent with a polymer-free drug coating.[11] The Eluvia Drug-Eluting Vascular Stent System (Boston Scientific Corporation) was designed to elute paclitaxel over time. The Eluvia stent incorporates paclitaxel in a biocompatible fluoropolymer coating to provide sustained and controlled drug release. Just recently, the MAJESTIC single-arm study demonstrated promising 2-year technical and clinical outcomes with a freedom from TLR rate of 92.5%.[12]

Patients presenting with femoropopliteal disease have a relevant limitation of life expectancy when the indication for revascularization is made. Thus, the decision regarding which technology should be used for treatment is driven by independently controlled studies' durability data. DCBs and DESs seem to be almost equally effective in TASC II A and B lesions and superior to plain old balloon angioplasty and/or BMS placement.[8-10] Therefore, the choice between both devices could be driven by the likelihood of provisional stenting. Eccentric and calcified lesions might represent a better indication for DESs, whereas fibrotic and concentric lesions (not necessarily excluding chronic total occlusions) might be better suited for DCBs, following the approach of avoiding unnecessary implants. Experience is still limited with regard to TASC II C and D lesions for both drug-eluting technologies.[13] In such lesions, the full lesion coverage with DESs seems to be attractive due to the excellent initial lesion appearance after stenting. However, longer-term follow-up technical and clinical data beyond 1 year for this approach is lacking. Single-arm studies for DCB angioplasty with spot stenting on indication have shown promising 1-year outcomes.[14,15] As a result, the decision between DESs and DCBs in this complex lesion subset is mostly driven by operator preference.

CONCLUSION

In summary, drug-eluting devices offer an attractive, minimally invasive treatment option for femoropopliteal lesions of all complexities—replacing bypass surgery as the first-line strategy even in TASC II D lesions. Head-to-head trials are mandatory to compare the safety and durability of interventional revascularization based on drug-eluting devices with bypass surgery. ■

1. Fowkes FG, Rudan D, Rudan I, et al. Comparison of global estimates of prevalence and risk factors for peripheral artery disease in 2000 and 2010: a systematic review and analysis. Lancet. 2013;382:1329-1340.
2. Malyar N, Furstenberg T, Wellmann J, et al. Recent trends in morbidity and in-hospital outcomes of in-patients with peripheral arterial disease: a nationwide population-based analysis. Eur Heart J. 2013;34:2706-2714.
3. Iida O, Soga Y, Hirano K, et al. Long-term outcomes and risk stratification of patency following nitinol stenting in the femoropopliteal segment: retrospective multicenter analysis. J Endovasc Ther. 2011;18:753-761.
4. Schillinger M, Sabeti S, Loewe C, et al. Balloon angioplasty versus implantation of nitinol stents in the superficial femoral artery. N Engl J Med. 2006;354:1879-1888.
5. Laird JR, Katzen BT, Scheinert D, et al. Nitinol stent implantation vs. balloon angioplasty for lesions in the superficial femoral and proximal popliteal arteries of patients with claudication: three-year follow-up from the RESILIENT randomized trial. J Endovasc Ther. 2012;19:1-9.
6. Matsumura JS, Yamanouchi D, Goldstein JA, et al. The United States study for evaluating endovascular treatments of lesions in the superficial femoral artery and proximal popliteal by using the protege everflex nitinol stent system II (DURABILITY II). J Vasc Surg. 2013;58:73-83 e1.
7. Wiskirchen J, Schober W, Schart N, et al. The effects of paclitaxel on the three phases of restenosis: smooth muscle cell proliferation, migration, and matrix formation: an in vitro study. Invest Radiol. 2004;39:565-571.
8. Rosenfield K, Jaff MR, White CJ, et al. Trial of a paclitaxel-coated balloon for femoropopliteal artery disease. N Engl J Med. 2015;373:145-153.
9. Laird JR, Schneider PA, Tepe G, et al. Durability of treatment effect using a drug-coated balloon for femoropopliteal lesions: 24-month results of IN.PACT SFA. J Am Coll Cardiol. 2015;66:2329-2338.
10. Dake MD, Ansel GM, Jaff MR, et al. Durable clinical effectiveness with paclitaxel-eluting stents in the femoropopliteal artery: 5-year results of the Zilver PTX randomized trial. Circulation. 2016;133:1472-1483.
11. Yazdani SK, Pacheco E, Nakano M, et al. Vascular, downstream, and pharmacokinetic responses to treatment with a low dose drug-coated balloon in a swine femoral artery model. Catheter Cardiovasc Interv. 2014;83:132-140.
12. Müller-Hülsbeck S. Two-year MAJESTIC results. Presented at: Cardiovascular and Interventional Radiology Society of Europe (CIRSE); September 20, 2016; Barcelona, Spain.
13. Zeller T, Rastan A, Macharzina R, et al. Drug eluting balloons vs. drug eluting stents in long femoropopliteal lesions – a retrospective propensity score analysis. J Endovasc Ther. 2014;21:359-368.
14. Scheinert D. Drug-coated balloon treatment for patients with intermittent claudication: new insights from the IN.PACT Global Study long lesion (≥ 15 cm) imaging cohort. Presented at: EuroPCR; May 19, 2015; Paris, France.
15. Micari A. The drug-eluting balloon superficial femoral artery-long study: the DEB SFA-LONG study. Presented at: EuroPCR; May 19, 2015; Paris, France.

Prof. Thomas Zeller, MD
Clinic for Cardiology and Angiology II
University Heart Center Freiburg–Bad Krozingen
Bad Krozingen, Germany
+49 7633 4022431
thomas.zeller@universitaets-herzzentrum.de
Disclosures: Receives honoraria from Abbott Vascular, Angioslide, Bard Peripheral Vascular, Veryan, Biotronik, Boston Scientific Corporation, Cook Medical, Cordis Corporation, Gore & Associates, Medtronic, Spectranetics Corporation, Straub Medical, TriReme, VIVA Physicians, GLG, Philips; consultant for Abbott Vascular, Bard Peripheral Vascular, Boston Scientific Corporation, Cook Medical, Gore & Associates, Medtronic, Spectranetics Corporation; research, clinical trial, or drug study funds received from 480 Biomedical, Bard Peripheral Vascular, Veryan, Biotronik, Cook Medical, Cordis Corporation, Covidien, Gore & Associates, Abbott Vascular, Medtronic, Spectranetics Corporation, Terumo Interventional Systems, TriReme, Philips.

Sponsored by Boston Scientific Corporation

The Future of Antiproliferative Therapies for Endovascular Interventions

Translational findings from the Ranger Paclitaxel-Coated Balloon data.

BY RENU VIRMANI, MD, FACC

Significant advancements have been made in the field of drug-eluting therapies for peripheral applications. Unlike the coronary vasculature, where atherosclerotic calcification is more predominately encountered, more aggressive (medial) calcification is often observed in the peripheral arteries, elevating the need for further technological advancements to treat this aggressive disease.

DESIGN CONSIDERATIONS FOR DRUG-ELUTING THERAPIES

The biological process of restenosis occurs well beyond the first 90 to 180 days in humans (Figure 1), whereas in juvenile animals it is observed at 30 days in normal arteries. Therefore, it is important to have long-term release of the drug. The longer the drug is released, the more durable the results will be. The argument over required drug dose has been ongoing for the past several years. Many experts in the medical community believe that higher loading doses of a drug lead to increasingly superior outcomes. Personally, I am not of that opinion. The ideal design considerations should maximize neointimal inhibition by maintaining therapeutic tissue levels over a

Next-generation DCBs, such as the Ranger Paclitaxel-Coated Balloon, are demonstrating a balance of high levels of neointimal inhibition beyond 90 days comparable to higher-dosed technologies, while also providing fewer physiologically significant histological findings in the downstream vessel beds.

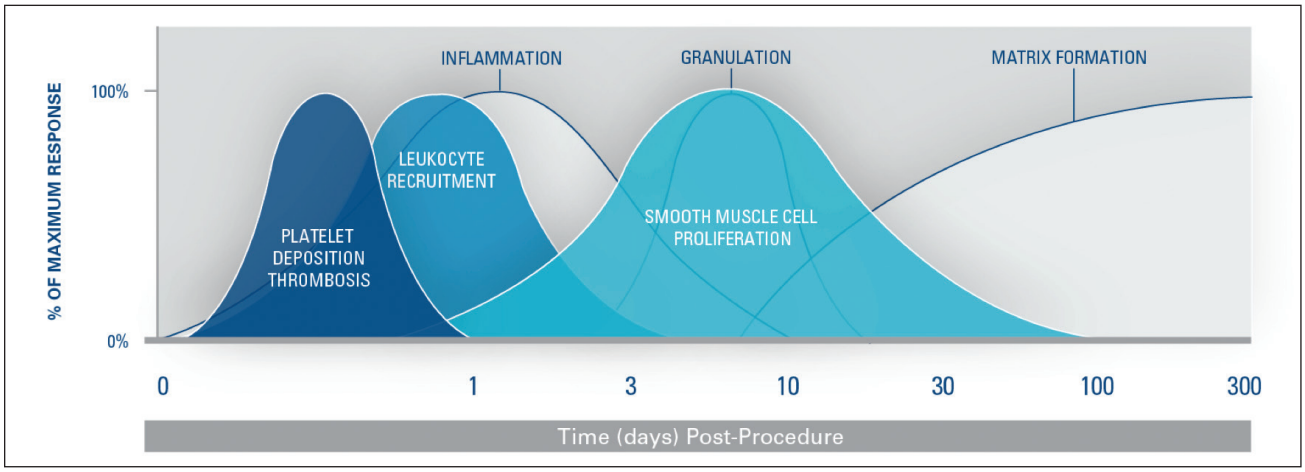

Figure 1. The biology of restenosis.

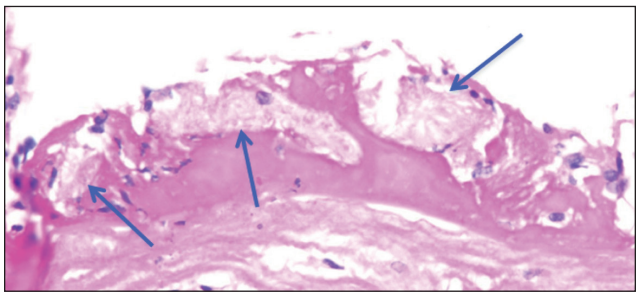

Figure 2. Crystalline material continues to be present in the arterial wall at 90 days.

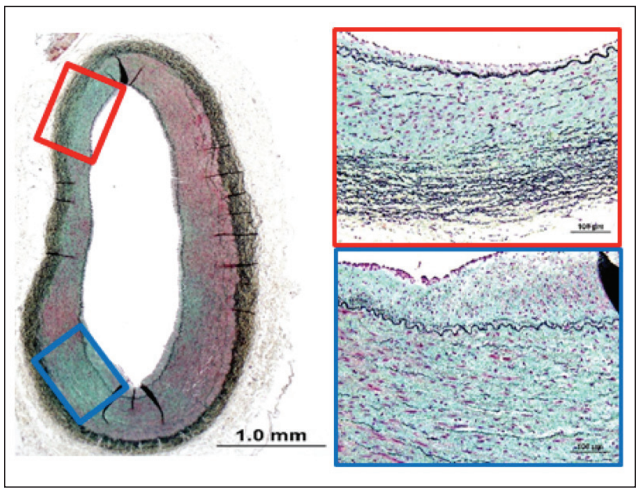

Figure 3. Biologic effects of paclitaxel are associated with loss of smooth muscle cells with replacement by proteoglycans as have been confirmed in multiple sections at 90 days in porcine femoral arteries with minimal neointimal thickening.

long time, while ensuring adequate healing and minimizing particulate loss downstream.

TRANSLATIONAL FINDINGS

Ranger Pharmacokinetics 90-Day Data From the CVPath Institute

Research has shown that next-generation drug-coated balloons (DCBs), such as the Ranger Paclitaxel-Coated Balloon (Boston Scientific Corporation), are demonstrating a balance of high levels of neointimal inhibition beyond 90 days (Figure 2) comparable to higher-dosed technologies, while also providing fewer physiologically significant histological findings in the downstream vessel beds.

We have seen a range of effects in porcine arteries, especially in the superficial femoral artery. We have looked for biologic effects at 7, 30, and 90 days. In the femoral artery, we see loss of smooth muscle cells, which range from involving half the vessel wall to transmural—the whole vessel wall shows us changes and, to a large extent, even circumferentially.

We have also observed sustained effects thus far up to 90 days. It seems that the Ranger DCB is effective in its mission to reduce smooth muscle cells in the arterial wall with replacement by proteoglycans and collagen matrix (Figure 3). ■

Renu Virmani, MD, FACC
President
CVPath Institute, Inc.
Gaithersburg, Maryland
rvirmani@cvpath.org
Disclosures: Institutional research support from Abbott Vascular, Biosensors International, Biotronik, Boston Scientific Corporation, Bard Peripheral Vascular, Medtronic, Microport Medical, OrbusNeich Medical, Sino Medical Sciences Technology, Terumo Interventional Systems, 480 Biomedical, and Gore & Associates; has speaking engagements with Merck; receives honoraria from Abbott Vascular, Boston Scientific Corporation, Bard Peripheral Vascular, Medtronic, Microport Medical, OrbusNeich Medical, Terumo Interventional Systems, and 480 Biomedical; and consultant for Abbott Vascular, Medtronic, 480 Biomedical, and Gore & Associates.

Sponsored by Boston Scientific Corporation

The Science Behind Local Drug-Delivery Technologies: The Benefit of Sustained Paclitaxel Release in the SFA

Sustained drug release is key to maintaining biological effect.

BY JUAN F. GRANADA, MD, FACC

The biological composition of peripheral atherosclerotic lesions is more complex than in the coronary territory. In peripheral atherosclerotic lesions, the disease burden is higher and the presence of total occlusions and calcium is more prevalent. Consequently, clinical studies consistently demonstrate that after percutaneous intervention of peripheral lesions, the restenotic process is not only more aggressive but also peaks later compared to coronary lesions.[1] In a retrospective analysis looking at nearly 600 patients who had undergone successful endovascular therapy for superficial femoral artery (SFA) lesions, Iida et al determined that restenosis peaked at approximately 12 months.[1] This is different from the coronary territory, where restenosis tends to peak at approximately 6 to 9 months. In developing a new technology for peripheral vascular applications, a durable biological effect can only be achieved if sustainable therapeutic levels of drug are maintained during this critical period.

THE ELUVIA STENT MECHANISM OF ACTION

The Eluvia Drug-Eluting Stent (Boston Scientific Corporation) utilizes a polymer drug combination designed to sustain arterial tissue concentration of paclitaxel at a therapeutic dose for beyond 1 year. Polymer-based local drug delivery is a well-established technological approach that has been thoroughly tested in the clinical setting over the last 20 years. The advantage of a polymer-based approach is that the amount of drug delivered to any given area can be accurately controlled over time. Eluvia's pharmacokinetic profile is unique in that a controlled burst of drug is initially released followed by a sustained release of a lower dose of drug that is maintained within therapeutic levels over the first 12 months after implantation (Figure 1). Another notable difference compared to other paclitaxel-based delivery systems is that Eluvia's elution profile is designed for the drug to never exceed the levels of potential vascular toxicity.

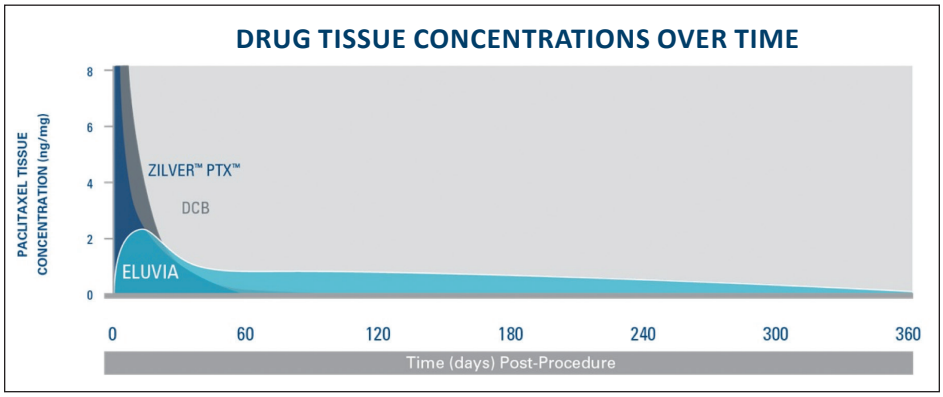

Figure 1. Scheme depicting the pharmacokinetic profile of Eluvia versus Zilver PTX (Cook Medical) paclitaxel release over 12 months based on preclinical pharmacokinetic analysis. Data for Eluvia on file at Boston Scientific Corporation. Data for Zilver PTX available from Dake MD, Van Alstine WG, Zhou Q, Ragheb AO. Polymer-free paclitaxel-coated Zilver PTX stents—evaluation of pharmacokinetics and comparative safety in porcine arteries. J Vasc Interv Radiol. 2011;22:603-610.

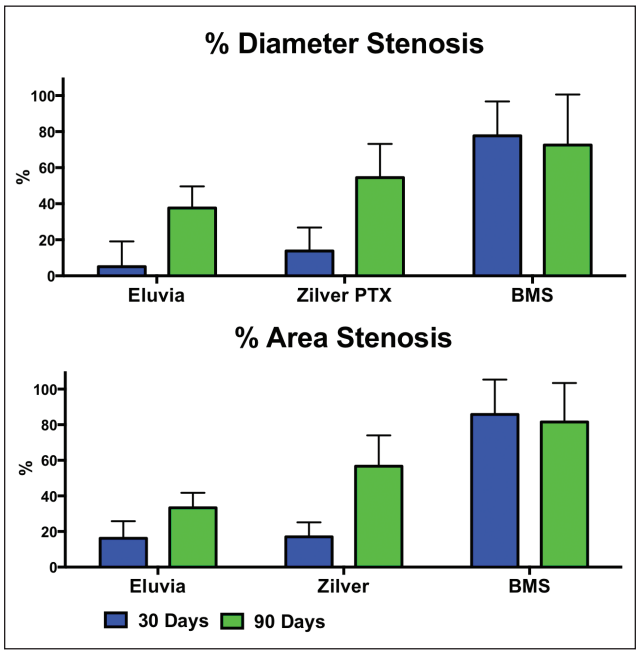

Figure 2. Percent diameter stenosis (angiography, top) and percent area of stenosis (OCT, bottom) change from 30 to 90 days after stent implantation.

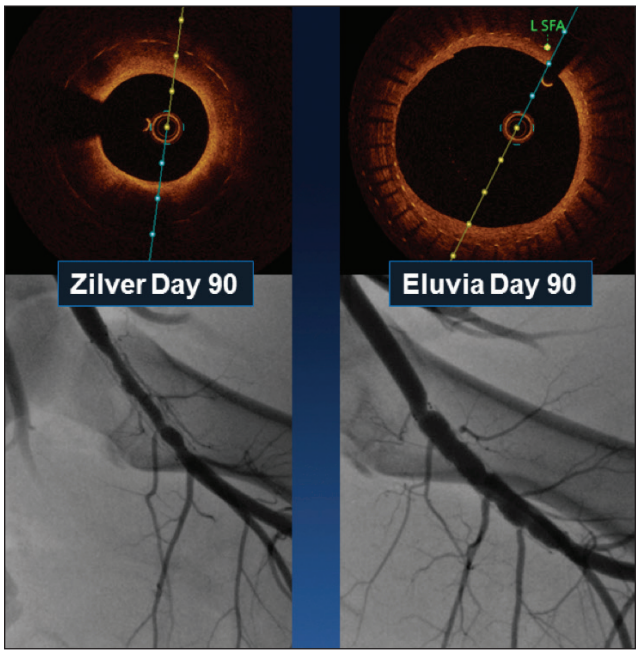

Figure 3. Representative angiographic and OCT images at 90 days in both drug-eluting stent groups.

TRANSLATIONAL FINDINGS

The effect of Eluvia's sustained drug release on neointimal formation was recently evaluated in a head-to-head experimental study using a porcine model of peripheral atherosclerosis. For this study, we utilized a unique strain of swine with familial hypercholesterolemia (known as FH-swine). This strain of swine exhibits high levels of low-density lipoprotein (LDL) and develops spontaneous atherosclerosis due to a naturally occurring LDL-receptor deficiency. This model allowed us to study the natural evolution of restenosis in an accelerated disease model, which more closely reflects what is actually happening in the clinical arena. The model has also allowed us to study and compare the effects of several antirestenotic therapies in restenosis prevention after vascular intervention. In this study, three test groups were included: a polymer-based paclitaxel-eluting arm (Eluvia), a polymer-free paclitaxel-eluting arm (Zilver PTX), and a bare-metal stent control arm. This allowed us to study the impact of two different paclitaxel-eluting methods in restenosis prevention and vascular healing (Figure 2).

Multimodality imaging including optical coherence tomography (OCT) and quantitative vascular angiography was performed at 30 and 90 days. Histological evaluation was performed and compared to the imaging findings. At 30 days, both Eluvia and Zilver PTX showed similar behavior in terms of stenosis reduction compared to the bare-metal stent group. The mean percent area stenosis by OCT was comparable between both groups (approximately 16%–17% in both groups). However, at 90 days, important differences in neointimal proliferation were seen between both devices. Although the degree of intrastent stenosis remained stable in the Eluvia arm between 30 and 90 days (approximately 10% reduction in lumen area; Figure 3), the Zilver PTX arm seemed to experience higher levels of neointimal proliferation with a lumen area reduction of approximately 47%. Neointimal proliferation rates measured in vivo (OCT) and ex vivo (histology) correlated and confirmed these differences seen in both devices.

CONCLUSION

In summary, in an experimental model of atherosclerosis, the polymer-based sustained release of paclitaxel provided lower levels of neointimal proliferation compared to a polymer-free stent-based control. ■

1. Iida O, Uematsu M, Soga Y, et al. Timing of the restenosis following nitinol stenting in the superficial femoral artery and the factors associated with early and late restenoses. Catheter Cardiovasc Interv. 2011;78:611-617.

Juan F. Granada, MD, FACC
Executive Director and Chief Innovation Officer
Cardiovascular Research Foundation
Skirball Center for Innovation
Orangeburg, New York
(845) 580-3084
Disclosures: The Skirball Center for Innovation has worked with most vascular drug-eluting device manufacturers.

Sponsored by Boston Scientific Corporation

Patterns of Restenosis: What Are the Data Telling Us?

WITH MICHAEL R. JAFF, DO

In your experience managing a major core laboratory and based on the latest clinical data, have you observed any differences in the pattern of restenosis between drug-coated balloons (DCBs), drug-eluting stents (DESs), bare-metal stents (BMSs), and standard percutaneous balloon angioplasty? Do the data suggest a reason for these differences?

Restenosis continues to remain the limitation of broader adoption of endovascular therapies for peripheral artery disease, and although technologies and skill of operators have both advanced, there remain opportunities for improvement in patency. Many experts believe that different patterns of restenosis are easier to revascularize and therefore may offer advantages over the life of the patient. Although I cannot provide any definitive answer today, there are clearly differences in patterns of restenosis across different endovascular strategies that may offer advantages in the near future. If so, these "patterns" may result in fewer revascularizations, lower complication rates, and potentially lower costs.

What is the typical timeframe in which lesions develop restenosis in the superficial femoral artery (SFA)? How does this vary between the different treatment options?

Across all treatments, endovascular or surgical, the first 12 months are critical. Maintaining patency through 12 months is not only appealing to physicians, but patients clearly choose to have interventions for disabling claudication for a durable outcome. We classically see restenosis within 12 months, and then the restenosis rates tend to level off. The most modern example of that is the impressive publication of 5-year data in the Zilver PTX (Cook Medical) randomized trial. Once patients made it out to 12 months following randomization and treatment, the progressive restenosis rates were very small. Presented data from the MAJESTIC trial also suggest that reintervention rates were quite low out to 2 years. Undoubtedly, the longer we can prevent restenosis, the lower the risk of requiring reintervention.

What do the latest data suggest about the durability of the different SFA treatment options?

It is actually fascinating to watch the evolution of primary patency as technology improves. We have seen improved primary patency as we have moved from uncoated percutaneous transluminal angioplasty to BMSs, DESs, and DCBs. It will be very interesting to see what happens with third- and fourth-generation technologies within these categories of endovascular intervention. For example, the second generation of DESs, although with limited data, appears to demonstrate impressive improvements in reintervention rates, and are, in fact, better than any other category of intervention to date.

What do the latest data tell us about the potential benefit of scaffolding to reduce the progression of restenosis?

As BMSs have evolved since the initial technology hit the market many years ago, we have seen a reduction in restenosis rates and associated fractures. For example, the SUPERB trial demonstrated impressive primary patency rates at 12 months with no identifiable fractures at the same time period. More recently, MAJESTIC data to 2 years have demonstrated no fractures.

How do you believe the SFA treatment algorithm will change in the next 3 to 5 years? What will drive those changes?

I imagine that the algorithm will continue to evolve. As technology has advanced, adoption of novel therapies have

mirrored the technology expansion. However, the strongest push to technology adoption will be the results of randomized clinical trials. The caliber of trial design has clearly met expectations from stakeholders, including physicians, regulators, payers, and most importantly, our ability to provide our patients with the most scientifically sound therapies.

Data from several clinical trials suggest that DCBs may not maintain patency as effectively as DESs or even BMSs after 2 or 3 years. How do you believe the treatment algorithm for SFA lesions will change if the clinical data confirm that DCBs are not able to deliver long-term patency as effectively as other treatment options?

The jury is out on this statement, and I would not rush to judgment. However, if longer-term durability with DCBs is limited compared to other technologies, I suspect that physicians will choose the "sweet spot" of relatively short, noncalcified lesions for treatment with DCBs.

Provisional stenting is used in up to 40% of DCB cases in longer lesions. How should the high provisional stenting rate when using DCBs in "real world" lesions affect the decision to use DCBs?

The pivotal trials of DCBs available on the United States market today kept the lesion length and complexity relatively straightforward. As with any other new technology in peripheral artery disease interventions, once the devices have approval, physicians tend to extend the applicability of the technology to tougher, more demanding lesions. This has been the case with the "real world" SFA and popliteal artery lesions seen in postapproval registries. I suspect that physicians will continue to work to improve procedural outcomes with DCBs in longer lesions, trying to minimize bailout stents. ■

Michael R. Jaff, DO
Paul and Phyllis Fireman Chair in Vascular Medicine
Harvard Medical School
Chair, Fireman Vascular Center
Medical Director, VasCore
Vascular Ultrasound Core Laboratory
Massachusetts General Hospital
Boston, Massachusetts
mjaff@partners.org
Disclosures: Noncompensated advisor to Boston Scientific Corporation, Abbott Vascular, Medtronic, and Cordis Corporation; equity investment in PQ Bypass; board member of VIVA Physicians, a 501(c)(3) not-for-profit education and research organization.

Sponsored by Boston Scientific Corporation

Ranger Paclitaxel-Coated PTA Balloon Catheter Clinical Update

Recent early data from two studies demonstrate the promise of the Ranger DCB.

RANGER-SFA TRIAL

Six-month results from the RANGER-SFA trial were presented by Prof. Dierk Scheinert, MD, at CIRSE 2016, the annual meeting of the Cardiovascular and Interventional Radiology Society of Europe, in Barcelona, Spain. Prof. Scheinert serves as Principal Investigator of the RANGER-SFA trial.

The first-in-human RANGER-SFA trial is a multicenter, randomized controlled trial evaluating the Ranger paclitaxel-coated percutaneous transluminal angioplasty balloon catheter (Boston Scientific Corporation) for the treatment of lesions in the superficial femoral artery (SFA) and popliteal artery. The trial seeks to prove that the Ranger drug-coated balloon (DCB) is superior to uncoated balloons at 6 months postprocedure in these lesions, as assessed by late lumen loss (LLL).

Methods

The investigators enrolled 105 patients with femoropopliteal artery lesions at 10 sites in Germany, France, and Austria. Patients were randomized 2:1 to treatment with the Ranger DCB (n = 71) or to the control therapy (n = 34). Follow-up will be conducted through 3 years.

Interim Results

In the Ranger DCB group (n = 71), 63 patients were available at 6-month follow-up (two patients withdrew and six patients missed their visits). In the control group, 6-month follow-up was completed for 25 of 34 patients (one patient died, two withdrew from the study, and six missed follow-up visits).

Patient and lesion characteristics were similar between the Ranger DCB and control groups. Technical and procedural success rates were also similar between the two groups.

At CIRSE, Prof. Scheinert reported that the study met its primary efficacy endpoint of in-segment LLL of the treated segment as observed by angiography at 6 months postprocedure, with significantly less LLL found for the Ranger DCB group as compared with the control group (Figure 1).

I was delighted to report the Ranger first-in-human results on behalf of the investigators. The impressive angiographic results are confirmation of the device's design goals and underpin ongoing studies of performance, including a real-world registry and, uniquely, a head-to-head DCB trial.

– Prof. Dierk Scheinert, MD
Principal Investigator
RANGER-SFA Trial

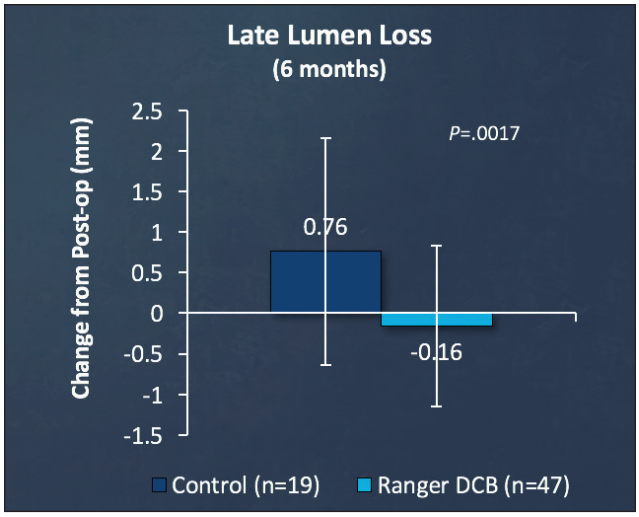

Figure 1. The primary endpoint was met with significantly less LLL for the Ranger DCB than for the control.

For the control group (n = 19) and the Ranger DCB group (n = 47), respectively, the minimum lumen diameters were: preoperative, 0.88 versus 0.79 mm (P = .92); postoperative, 3.3 versus 3.5 mm (P = .58); and at 6 months, 2.5 versus 3.5 mm (P = .0083), with postoperative to 6-month LLL of +0.76 versus -0.16 mm (P = .0017).

The secondary safety endpoint of cumulative target lesion revascularization (TLR) rate through 6 months was 12% for the control group versus 5.6% for the Ranger DCB group (P = .47). Prof. Scheinert noted that the Ranger DCB group achieved one of the highest reported rates (94.4%) of freedom from clinically driven TLR at 6 months; investigators are awaiting full 12-month follow-up data.

The rates of adverse events and serious adverse events were similar in the two groups, with no target limb amputations and one death in the control group at 6 months. There were no reported unanticipated serious adverse device effects. Additionally, in the Ranger DCB group, 81% of patients presented with no or mild symptoms (Rutherford class 0–1) at 6-month follow-up, and distributions for both control and Ranger DCB groups showed improvement, with a shift to lower Rutherford categories and no significant difference between groups.

In both groups, there was significant improvement in ankle-brachial index (ABI) and hemodynamic success at 6 months (P < .05). The mean rate of hemodynamic success (positive ABI change ≥ 0.1) was 76% for the Ranger DCB and 56% for the control (P = .1214). There were no significant differences between groups in terms of walking function or quality of life.

The investigators concluded that patients treated with the Ranger DCB demonstrated significantly less LLL at 6 months versus patients in the control group. Additionally, at 6 months, TLR rates trended toward separation between the Ranger DCB and control groups. Patients treated with the Ranger DCB demonstrated significant improvements in symptoms and hemodynamic success at 6 months.

RANGER ALL-COMERS REGISTRY

Interim results from the multicenter Ranger All-Comers Registry evaluating the Ranger DCB for the treatment of femoropopliteal atherosclerotic lesions were presented at the CIRSE 2016 conference. Michael Lichtenberg, MD, FESC, is the Principal Investigator for the registry.

Methods

The registry has enrolled 180 patients in Germany and Switzerland. Key inclusion criteria are patients with peripheral artery occlusive disease of the SFA—PIII and Rutherford class 2 to 5.

The primary efficacy endpoint is primary patency at 12 and 24 months, defined as freedom from ≥ 50% restenosis as indicated by duplex ultrasound peak systolic velocity ratio ≥ 2.4 in the target lesion with no reintervention. The primary safety endpoint is major adverse events, defined as a composite of device- or procedure-related mortality and major target limb amputation at 6 months.

The Ranger SFA Registry provided significant validation of the efficacy and safety of the Ranger DCB for patients with long femoropopliteal artery lesions.

– Michael Lichtenberg, MD, FESC
Principal Investigator
Ranger SFA Registry

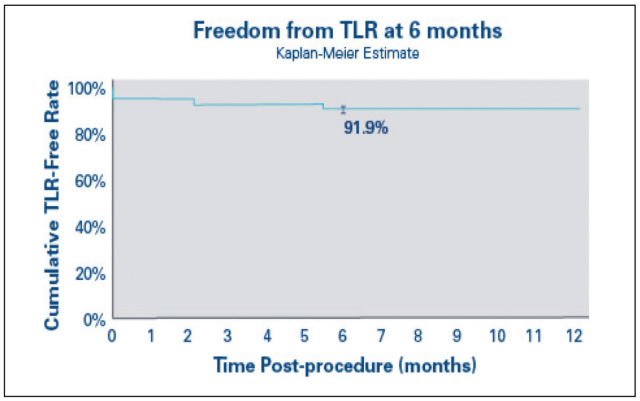

Figure 2. At 6 months, the rate of freedom from TLR was 91.9%.

Interim Results

Interim findings were presented on 149 patients and 210 lesions treated with the Ranger DCB. Mean age of the patients is 70 years, 63% are male, and baseline mean ABI is 0.6 (range, 0.01–1.43). Procedural outcomes included 73% technical success for DCB only (no flow-limiting dissection) and 100% success for DCB plus adjunctive therapy (stenting). Residual angiographic stenosis was 12%.

With 105 treated patients available at 6-month follow-up, 91% of treated limbs improved by one or more Rutherford categories and 80% improved by two or more Rutherford categories. There was statistically significant ABI improvement in treated limbs from 0.583 at baseline to 0.879 at 6 months (P < .01). At 6 months after treatment with the Ranger DCB, primary patency was 91.1% (Kaplan-Meier estimate) and freedom from TLR was 91.9% (Figure 2). ■

Sponsored by Boston Scientific Corporation

Sustained Drug Release Optimizes Long-Term Outcomes

Is the drug-eluting vascular stent a game-changer?

BY PROF. STEFAN MÜLLER-HÜLSBECK, MD, EBIR, FCIRSE, FICA

New stent designs and drug-eluting technologies are intended to improve outcomes following femoropopliteal artery treatment for peripheral artery disease. Long-term patency following bare-metal stenting (BMS) is encouraging but remains unsatisfactory, with reported 1-year primary patency peaking at approximately 80%.[1-5] Likewise, target lesion revascularization (TLR) rates for BMS also show room for improvement, with 1-year rates averaging approximately 13% in recent clinical trials.[2-5]

THE MAJESTIC TRIAL

MAJESTIC is a prospective, single-arm, multicenter clinical trial enrolling 57 patients across multiple sites in Europe, Australia, and New Zealand. Eligible patients had chronic lower limb ischemia and de novo or restenotic lesions in the native superficial femoral artery (SFA) and/or proximal popliteal artery (PPA). The primary endpoint was defined as 9-month primary patency assessed by duplex ultrasound as adjudicated by an independent core laboratory compared against a literature-derived performance goal. Major adverse events (MAEs) included all-cause death through 1 month, target limb major amputation, and TLR.

The Eluvia Drug-Eluting Vascular Stent System (Boston Scientific Corporation) is a self-expanding nitinol stent with a dual-layer coating and active layer consisting of the fluorocopolymer (polyvinylidene fluoride-co-hexafluoropropylene) and antiproliferative agent paclitaxel. The MAJESTIC study population for treating femoropopliteal artery lesions included a relatively challenging set of lesions:

- 77% extended into the distal SFA
- 9% extended into the PPA
- 65% were severely calcified
- 46% had total occlusions
- 7.1-cm average lesion length

At 12 months, primary patency was 96.1% (49/51) and the MAE rate was 3.8% (2/53); both MAEs were TLRs. A 7.5% TLR rate was achieved at 2 years with no stent fractures. There were only two new TLRs between 1 and 2 years. These results represent the highest primary patency rates reported at 1 year and the lowest TLR rates at 2 years between comparable studies in the treatment of femoropopliteal lesions.[6,7] In MAJESTIC, a reduction in primary patency between 6 and 12 months was not observed, a period of time during which patency has been seen to drop in other SFA trials (Figure 1).[6,8-11]

The Eluvia Drug-Eluting Stent system was designed to elute paclitaxel over time to match the restenotic process

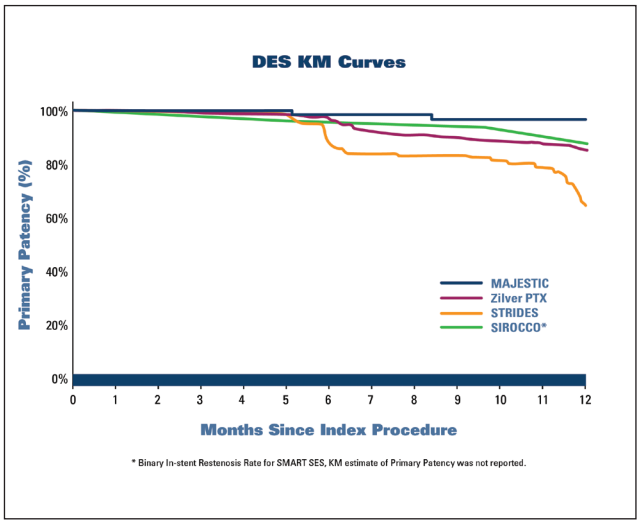

Figure 1. The decline in patency observed between 6 and 12 months in other trials testing similar technologies was not observed in MAJESTIC, which maintained a very flat curve throughout the first year, suggesting that sustained drug release may have a positive impact in this critical period when restenosis usually develops.

The MAJESTIC results represent the highest primary patency rates reported at 1 year and the lowest TLR rates at 2 years between comparable studies in the treatment of femoropopliteal lesions.

in the SFA. Prolonged paclitaxel elution is made possible by the PVDF-HFP (poly-vinylidene fluoride-hexafluoropropylene, a biocompatible fluoropolymer[12]) coating, which provides sustained and controlled drug release and does not inhibit endothelialization or promote thrombus formation in preclinical models.[13,14] Several studies have suggested that restenosis following nitinol stenting in the SFA typically occurs within 12 months.[15] This pattern was not observed in MAJESTIC, suggesting that sustained drug release may have a positive impact in this critical period when restenosis usually develops. No new TLR events occurred from 9 through 12 months, and the TLR rate remained low through 24 months.

CONCLUSION

The MAJESTIC clinical study showed that patients whose femoropopliteal arteries were treated with the Eluvia stent sustained a high patency with clinical improvement, low MAE rate, and an extraordinarily low TLR rate at 2 years. These results will have a significant impact on the future treatment of SFA lesions: if a stent is warranted, a dual-layer drug-eluting stent with prolonged paclitaxel elution seems to be the ideal solution from the current perspective. ■

1. Schillinger M, Sabeti S, Loewe C, et al. Balloon angioplasty versus implantation of nitinol stents in the superficial femoral artery. N Engl J Med. 2006;354:1879-1888.
2. Krankenberg H, Schluter M, Steinkamp HJ, et al. Nitinol stent implantation versus percutaneous transluminal angioplasty in superficial femoral artery lesions up to 10 cm in length: the femoral artery stenting trial (FAST). Circulation. 2007;116:285-292.
3. Laird JR, Katzen BT, Scheinert D, et al. Nitinol stent implantation vs. balloon angioplasty for lesions in the superficial femoral and proximal popliteal arteries of patients with claudication: three-year follow-up from the RESILIENT randomized trial. J Endovasc Ther. 2012;19:1-9.
4. Bosiers M, Torsello G, Gissler HM, et al. Nitinol stent implantation in long superficial femoral artery lesions: 12-month results of the DURABILITY I study. J Endovasc Ther. 2009;16:261-269.
5. Matsumura JS, Yamanouchi D, Goldstein JA, et al. The United States study for evaluating endovascular treatments of lesions in the superficial femoral artery and proximal popliteal by using the Protege Everflex nitinol stent system II (DURABILITY II). J Vasc Surg. 2013;58:73-83 e71.
6. Dake MD, Ansel GM, Jaff MR, et al. Paclitaxel-eluting stents show superiority to balloon angioplasty and bare metal stents in femoropopliteal disease: twelve-month Zilver PTX randomized study results. Circ Cardiovasc Interv. 2011;4:495-504.
7. Dake MD, Ansel GM, Jaff MR, et al. Sustained safety and effectiveness of paclitaxel-eluting stents for femoropopliteal lesions: 2-year follow-up from the Zilver PTX randomized and single-arm clinical studies. J Am Coll Cardiol. 2013;61:2417-2427.
8. Duda SH, Bosiers M, Lammer J, et al. Drug-eluting and bare nitinol stents for the treatment of atherosclerotic lesions in the superficial femoral artery: long-term results from the SIROCCO trial. J Endovasc Ther. 2006;13:701-710.
9. Lammer J, Bosiers M, Zeller T, et al. First clinical trial of nitinol self-expanding everolimus-eluting stent implantation for peripheral arterial occlusive disease. J Vasc Surg. 2011;54:394-401.
10. Dake MD, Scheinert D, Tepe G, et al. Nitinol stents with polymer-free paclitaxel coating for lesions in the superficial femoral and popliteal arteries above the knee: twelve-month safety and effectiveness results from the Zilver PTX single-arm clinical study. J Endovasc Ther. 2011;18:613-623.
11. Iida O, Takahara M, Soga Y, et al. One-year results of the ZEPHYR (Zilver PTX for the femoral artery and proximal popliteal artery) registry: predictors of restenosis. JACC Cardiovasc Interv. 2015;8:1105-1112.
12. Stone GW, Teirstein PS, Meredith IT, et al. A prospective, randomized evaluation of a novel everolimus-eluting coronary stent: the PLATINUM (a prospective, randomized, multicenter trial to assess an everolimus-eluting coronary stent system [Promus Element] for the treatment of up to two de novo coronary artery lesions) trial. J Am Coll Cardiol. 2011;57:1700-1708.
13. Wilson GJ, Huibregtse BA, Stejskal EA, et al. Vascular response to a third generation everolimus-eluting stent. EuroIntervention. 2010;6:512-519.
14. Iida O, Uematsu M, Soga Y, et al. Timing of the restenosis following nitinol stenting in the superficial femoral artery and the factors associated with early and late restenoses. Catheter Cardiovasc Interv. 2011;78:611-617.
15. Chin-Quee SL, Hsu SH, Nguyen-Ehrenreich KL, et al. Endothelial cell recovery, acute thrombogenicity, and monocyte adhesion and activation on fluorinated copolymer and phosphorylcholine polymer stent coatings. Biomaterials. 2010;31:648-657.

Prof. Stefan Müller-Hülsbeck, MD, EBIR, FCIRSE, FICA
Professor of Radiology
Head of the Department of Diagnostic and Interventional Radiology/Neuroradiology
Diako Hospital
Flensburg, Germany
muehue@diako.de
Disclosures: Consultant for Boston Scientific Corporation and has received consulting fees, speaker honorarium, and support for accommodation and traveling when presenting Boston Scientific Corporation–related data.

Sponsored by Boston Scientific Corporation

Are DCBs a Durable Solution?

A discussion of DCB durability and superiority in the context of 2-year data.

BY GARY M. ANSEL, MD

When CE Mark approval was first given to drug-eluting stents (DESs) followed by drug-coated balloons (DCBs), the nonsurgical treatment of occlusive disease in the femoropopliteal arterial bed started to come of age. The ability to reduce repeat interventions in some patient populations, even without the need for a metal scaffold, is particularly attractive in the femoropopliteal region, where the risk of restenosis is especially high due to the presence of high mechanical forces.

SUPERIORITY OF DCBs OVER PERCUTANEOUS TRANSLUMINAL ANGIOPLASTY

Paclitaxel without any polymeric coating was first approved on a self-expanding nitinol stent platform (Zilver PTX, Cook Medical) in late 2009. Level 1 randomized controlled trial data demonstrated an improvement in patency and target lesion revascularization (TLR) compared to both percutaneous transluminal angioplasty (PTA) and bare-metal stents at 12-months, and these outcomes have continued to 5 years of follow-up.[1,2] However, the use of a stent in the lower extremity, regardless of the presence of an antiproliferative agent, remains somewhat controversial due to early platforms being associated with stent fractures. Fortunately, data from later generations of stents have seen dramatic reductions—although not the elimination—of fractures. Real-world data recently published on the use of DESs in Japan demonstrated a less complex pattern of stent restenosis, as well as its subsequent retreatment. The first two attempts at using nonpaclitaxel polymer-based stents in the SIROCCO and STRIDES trials did not produce positive results.[3,4] There has always been a question of the quality of the polymers used on the stents in these trials, as well as the decision not to use paclitaxel. The recently published 2-year results from the MAJESTIC trial showed a freedom from TLR rate of 92.5% utilizing the polymer-based Eluvia Drug-Eluting Vascular Stent System (Boston Scientific Corporation), and they appear to be to very promising.[5] Certainly if longer-term results hold up in a randomized trial the way Zilver PTX's did, the argument for stent utilization will become even stronger.

Two large United States–based pivotal trials have demonstrated superiority of DCBs over PTA in claudicants, and several ongoing registries are showing excellent TLR rates in longer lesions and in-stent restenosis.[6-8] The IN.PACT SFA randomized controlled trial evaluated the In.Pact Admiral DCB (Medtronic) versus PTA; 2-year data demonstrated significant efficacy with stable primary patency of 78.9% in the DCB group versus 50.1% for PTA ($P < .001$) and a TLR rate of 9.1% versus 28.3% for the PTA group ($P < .001$).[9] The randomized LEVANT trial evaluated the Lutonix DCB (Bard Peripheral Vascular) versus PTA in femoropopliteal lesions and showed a 12-month primary patency rate of 65.2% for DCB versus 52.6% for PTA ($P = .02$).[10]

QUALIFYING DCB SUCCESS

Not all patient subsets may experience the same benefit. More recently, the reality that DCBs may not be universally successful and the durability may wane after 2 to 3 years has started to be reported. As we look back at the DCB trials that have demonstrated excellent 2-year patency data, we must remember that these trials excluded patients with significant calcification and in whom predilatation was not successful. A recent publication by Fanelli et al reported that DCBs were less effective at 1 year in patients with a higher degree of calcium. The study found that significant calcification led to lower ankle-brachial index at follow-up, lower primary patency, higher TLR, and less prevention of late lumen loss.[11] Real-world use of DCBs has also started to show mixed results. Although data from IN.PACT Global have been excellent overall, even up to 2 years, over 40% of the longer lesions required stenting. Recent single-center retrospective results from Dierk Scheinert, MD, and his group in Leipzig have led us to pause. In this very complex group of long lesions (24-cm mean length, 65% occluded), and with over 37% treated for in-stent restenosis, stent implantation was performed in 23.3% of the lesions.

Not all patient subsets may experience the same benefit. More recently, the reality that DCBs may not be universally successful and the durability may wane after 2 to 3 years has started to be reported.

Kaplan-Meier estimates of primary patency were 79.2% and 53.7% for all lesions at 1 and 2 years, respectively, whereas freedom from TLR was 85.4% and 68.6%. Primary patency for in-stent restenosis treatment was 76.6% and 48.6%, and freedom from TLR was 83% and 58.7% at 1 and 2 years, respectively.[12] This group published another study with propensity-matched data for complex femoropopliteal disease treated with DCBs, standard, and interwoven nitinol stents, which demonstrated equivalent, continued patency reduction from 1 to 3 years with DCBs compared to tubular nitinol stents.[13]

DCBs IN CRITICAL LIMB ISCHEMIA

As the femoropopliteal treatment options continue to mature, the next data set needed is safety in the critical limb Ischemia (CLI) population. DCBs for CLI have only been studied with core lab documentation in the tibial population. Interestingly, a large, multinational, randomized trial (IN.PACT DEEP) performed outside the United States failed to demonstrate improved patency and limb salvage.[14] In fact, there was a nonstatistically significant trend in major amputations seen in the DCB group. Although there has been no reported increase in amputations in the currently reported device approval studies, these are based on claudicants and not patients with CLI, and these trials also would only report on major amputations, not toe amputations. Certainly the amount of antimitotic agent going downstream will be higher when multiple, longer DCBs with larger diameters are utilized. This effect would be expected to be less with DESs and completely eliminated with polymer-based DESs. A study with the appropriate controls is needed to develop more insight.

CONCLUSION

Ultimately, the use of DESs and DCBs in the femoropopliteal region are improving outcomes in the femoropopliteal bed and appear to be the most optimal first treatment for patients with claudication. In the device approval populations, the 5-year DES results are impressive, as are the 2-year DCB results. However, in more complex lesions we need to develop further data sets that help us optimize which patient populations will be best treated with DESs or DCBs, both short and long term. ■

1. Dake M. The Zilver PTX randomized trial of paclitaxel-eluting stents for femoropopliteal disease: 5-year results. Presented at: Vascular Interventional Advances (VIVA) 2014; November 2014; Las Vegas, Nevada.
2. Dake MD, Ansel GM, Jaff MR, et al. Durable clinical effectiveness with paclitaxel-eluting stents in the femoropopliteal artery: 5-year results of the Zilver PTX randomized trial. Circulation. 2016;133:1472-1483.
3. Duda SH, Bosiers M, Lammer J, et al. Drug-eluting and bare nitinol stents for the treatment of atherosclerotic lesions in the superficial femoral artery: long-term results from the SIROCCO trial. J Endovasc Ther. 2006;13:701-710.
4. Lammer J, Bosiers M, Zeller T, et al. First clinical trial of nitinol self-expanding everolimus-eluting stent implantation for peripheral arterial occlusive disease. J Vasc Surg. 2011;54:394–401.
5. Müller-Hülsbeck S. Two-year MAJESTIC results. Presented at: Cardiovascular and Interventional Radiology Society of Europe (CIRSE); September 20, 2016; Barcelona, Spain.
6. Scheinert D, for the LEVANT 2 Investigators. Lutonix global real world SFA registry-interim results & first look at LEVANT 2, 24 month results. Presented at: Transcatheter Cardiovascular Therapeutics (TCT); October 2015; San Francisco, California.
7. Scheinert D. 12-month results for 157 patients enrolled in the IN.PACT Global study's long lesion imaging cohort. Presented at: EuroPCR; May 2015; Paris, France.
8. Schroeder H, Meyer DR, Lux B, et al. Two-year results of a low-dose drug-coated balloon for revascularization of the femoropopliteal artery: outcomes from the ILLUMENATE first-in-human study. Catheter Cardiovasc Interv. 2015;86:278–286.
9. Laird JR, Schneider PA, Tepe G, et al. Sustained durability of treatment effect using a drug-coated balloon for femoropopliteal lesions: 24-month results of IN.PACT SFA. J Am Coll Cardiol. 2015 Dec 1;66:2329-2338.
10. Rosenfield K, Jaff MR, White CJ, et al. Trial of a paclitaxel-coated balloon for femoropopliteal artery disease. N Engl J Med. 2015;373:145-153.
11. Fanelli F, Cannavale A, Gazzetti M, et al. Calcium burden assessment and impact on drug-eluting balloons in peripheral arterial disease. Cardiovasc Intervent Radiol. 2014;37:898–8907.
12. Schmidt A, Piorkowski M, Görner H. Drug-coated balloons for complex femoropopliteal lesions 2-year results of a real-world registry. JACC Cardiovasc Interv. 2016;9:715-724.
13. Steiner S, Schmidt A, Bausback Y, et al. Midterm patency after femoropopliteal interventions: a comparison of standard and interwoven nitinol stents and drug-coated balloons in a single-center, propensity score-matched analysis. J Endovasc Ther. 2016;23:347-355.
14. Zeller T, Baumgartner I, Scheinert D, et al. Drug-eluting balloon versus standard balloon angioplasty for infrapopliteal arterial revascularization in critical limb ischemia: 12-month results from the IN.PACT DEEP randomized trial. J Am Coll Cardiol. 2014;64:1568-1576.

Gary M. Ansel, MD
System Medical Chief for Vascular Medicine, OhioHealth
OhioHealth Riverside Methodist Hospital
Associate Medical Director, OhioHealth Research Institute
Columbus, Ohio
Assistant Clinical Professor of Medicine
Department of Medicine
University of Toledo Medical Center
Toledo, Ohio
gary.ansel@ohiohealth.com
Disclosures: Medical advisory board member and consultant for Boston Scientific Corporation, Medtronic, Bard Peripheral Vascular, Gore & Associates, Cook Medical, Abbott Vascular, and Cardinal Health.

Sponsored by Boston Scientific Corporation

The Future of Drug-Eluting Therapies: What Will the Treatment Algorithm Look Like?

BY WILLIAM A. GRAY, MD



Prior to the advent of drug-eluting therapies in the superficial femoral artery (SFA), specifically drug-eluting stents (DESs) and drug-coated balloons (DCBs), there really existed no agreed-upon algorithm to direct revascularization in this vascular territory. All devices (balloons, stents, covered stents, atherectomy, etc) had their niches, their advocates, and their detractors, and it was reasonable from a data perspective to use any or all of them depending on the circumstance, lesion-specific qualities, and operator preference. Moreover, there are a variety of operators—vascular surgeons, interventional radiologists, and interventional cardiologists—whose specialties may each have their own preferred approaches and opinions on relevant endpoints.

Enter the DES and DCB therapies and their ability to deliver antiproliferative drug to the vessel wall; head-to-head data have demonstrated a clear advantage over standard percutaneous transluminal angioplasty (PTA). Further, in the case of the Zilver PTX DES (Cook Medical), data against bare-metal stents (BMSs) also demonstrate superiority. In many interventional labs, these two device categories have begun to provide the possibility of a final common pathway; that is, regardless of the tools used to achieve and secure acute procedural patency, DESs and DCBs are the finishing therapy used to assure the maximum potential for long-term patency.

FACTORS GOING INTO PROCEDURAL DECISION MAKING

In this construct, then, how does the operator choose between DES and DCB? There are several important aspects related to this decision; specifically, many of the following factors (and others not listed) will be variably weighted by each operator, and it is unlikely that any two operators are exactly alike in their ultimate assessments. The following are considerations for the intervention, lesion, patient, or clinical/economic environment, and it is important to remember that these issues can be used in combination and are not mutually exclusive from one another:

- Acute/procedural tolerance for a non–stent-like angiographic result
- Amount of the lab time per intervention
- Degree of aversion to implanting metal prosthesis (stent)
- Lesion complexity
  - Degree of calcification
  - Presence of chronic total occlusion
  - Lesion(s) at flexion points
  - Prior intervention: in-stent restenosis (ISR) versus prior PTA restenosis
  - Lesion length
- Familiarity/comfort/preference/patience with atherectomy devices
- Long-term patency data
- Claudication versus critical limb ischemia
- Reimbursement pressures related to:
  - Office-based lab (OBL): no transitional pass-through payment for DCB and solid reimbursement for stent and/or atherectomy
  - Risk sharing for 1- to 2-year outcomes

Let's walk through a few of these considerations to better understand how they might affect choice of interventional tools, which operators they are most relevant for, and how they might be combined to come up with a treatment plan.

ACUTE/PROCEDURAL TOLERANCE FOR A NON–STENT-LIKE ANGIOGRAPHIC RESULT

This particular factor applies specifically to the operator's willingness to nuance the result of their intervention after PTA (with or without other adjunctive devices) in conjunction with the use of a DCB. This generally boils down to not only the operator's comfort with an imperfect result

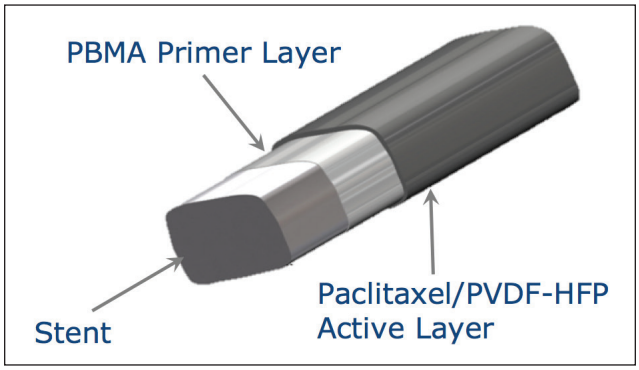

Figure 1. The Eluvia DES surface polymer construction.

that may not look like a traditionally successful outcome, but also their willingness and availability (office patients waiting, etc) to spend a bit more time in lesion assessment postintervention. It also may relate to the willingness and ability of the operator to use adjunctive therapy (specialty balloon, atherectomy, etc) ahead of the PTA, which is likely to improve the post-PTA result and give a more stent-like result but will take more time to set up (eg, filter deployment) and perform, especially in the case of atherectomy. Obviously this consideration also relates, in most cases, directly to the complexity of the lesion because this will affect the choice of tools and outcome of intervention.

DEGREE OF AVERSION TO IMPLANTING METAL PROSTHESIS (STENT)

Some operators will prefer to implant a stent—it is both expedient and gives a certainty of result that largely eliminates the need to spend time and effort to further assess/treat the lesion as well as the associated small risk of early failure.

Other operators have the complete opposite thinking and will prefer to avoid implanting a stent whenever possible primarily due to the difficulty of managing/treating in-stent restenosis (ISR). Should it occur, the likelihood of recurrent ISR after first ISR treatment is approximately 70% at 6 months; although this has been shown to be improved after laser debulking,[1] it still remains approximately 50% at 6 months. These operators may be more willing to work toward a nonstent solution up front in the initial procedure so their use of adjunctive devices and DCBs is likely to be much greater.

To be fair, there are simply times when the lesion and its response to initial interventional maneuvers will dictate the course of required therapy. Witness the IN.PACT Global registry long-lesion cohort, which reported > 40% stent usage in combination with DCB for lesions > 21 cm in length—note that the patency of the long-lesion length group did not suffer too badly but may have been positively impacted due to the use of a scaffold. Or the data from Fanelli et al's initial analysis demonstrating the untoward effect that increasing degrees of calcium have on long-term patency after DCB treatment.[2] This is countered, fortunately, both with some preclinical data from Tellez et al[3] demonstrating no decrement in drug uptake in vessels first treated with rotational atherectomy in hypercholesterolemic swine, as well as clinical data from the pilot DEFINITIVE AR study suggesting a trend toward better long-term patency with adjunctive directional atherectomy.[4] Lastly, the early uncontrolled but prospective data for DCB treatment of ISR (IN.PACT Global study) appears to be encouraging, thus limiting some of the prior concerns with the phenomenon of ISR.

PROPOSED ALGORITHM FOR THE APPLICATION OF ANTIPROLIFERATIVE THERAPY CHOICES IN THE SFA

In our lab, the decision to use either a DES or DCB is predicated on the presenting lesion appearance, as well as its response to the first therapeutic maneuver. As an extreme example, in a long chronic total occlusion with significant calcium, it is unlikely that a simple PTA/DCB combination will be successful, in which case atherectomy—if appropriate to the crossing path of the wire—would be used first. If not possible to debulk, then PTA and DES would be chosen. For most other lesions with less severe presenting anatomic features, most would have a predilation or debulking and then an assessment of the lesion appearance and estimation of the need for scaffolding. If favorable as a stand-alone preparatory result, then a DCB would be employed to finish the procedure, always with the back-up of a BMS should the need arise after the DCB.

NEW DES DATA ON THE HORIZON

Heretofore, there had been only one SFA DES—with good long-term data—available for use in the United States, the Zilver PTX. But a novel DES has been intro-

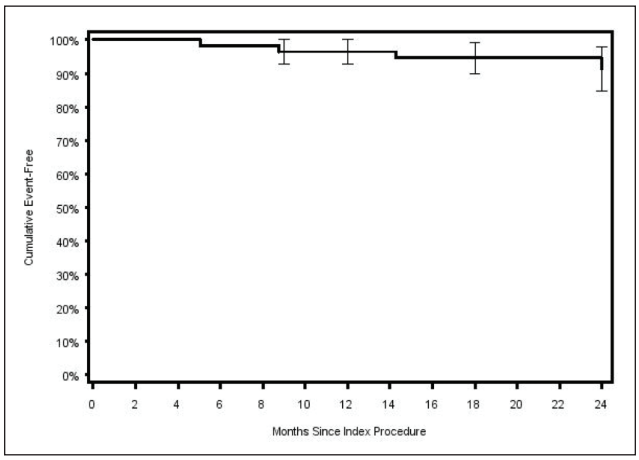

Figure 2. MAJESTIC trial freedom from target lesion revascularization through 24 months.

Boston Scientific
Advancing science for life™

REVELUTIONARY RESEARCH

Boston Scientific is the only company investing in a complete portfolio of drug-eluting therapies

Two Technologies
The Eluvia™ Drug-Eluting Vascular Stent System and the Ranger™ Paclitaxel-Coated PTA Balloon Catheter

20 Global DE Trials
Designed to advance the field of endovascular therapies

3 500 Patients
Enrolled in global clinical trials

Expanding Indications
Trials dedicated to advancing research in areas such as below-the-knee and AV fistula

92.5%

Elevating the Field
The Eluvia Drug-Eluting Stent reported the highest 2-year Freedom from TLR rate in the MAJESTIC trial

CAUTION: The law restricts these devices to sale by or on the order of a physician. Indications, , warnings and instructions for use can be found in the product labeling supplied with each device. Information for the use only in countries with applicable health authority product registrations. This material is not for use or distribution in France. **CAUTION:** Investigational Device in the US. Limited by Federal (or US) law to investigational use only. Not available for sale in the US.

Eluvia and Ranger are registered or unregistered trademarks of Boston Scientific Corporation or its affiliates. © 2016 Boston Scientific Corporation or its affiliates. All rights reserved. PI-415203-AA AUG2016

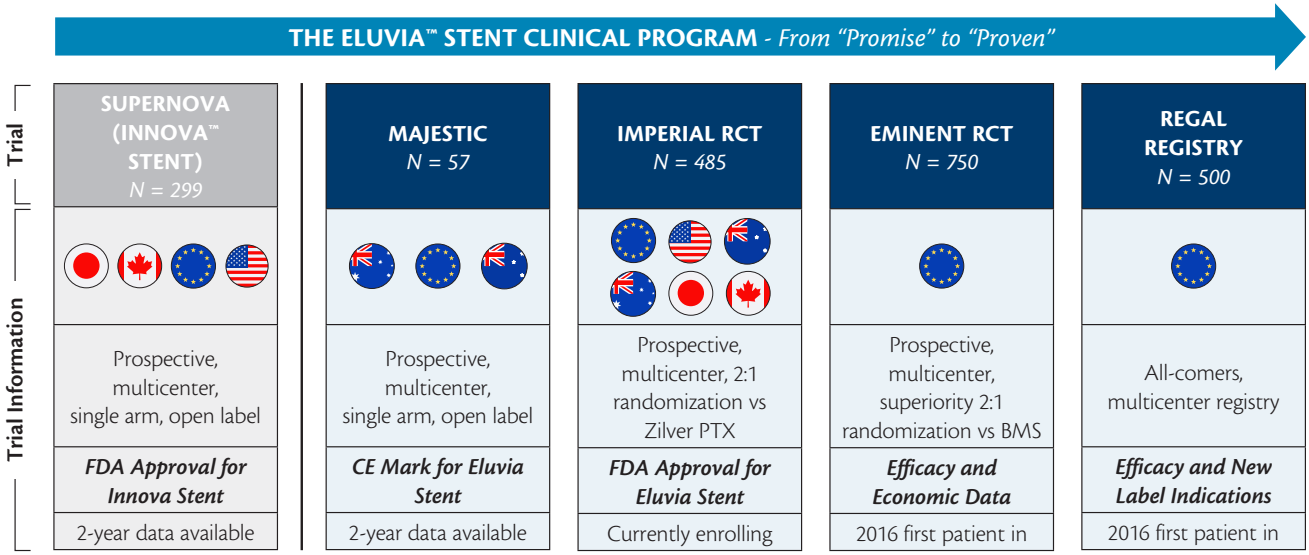

Figure 3. The Eluvia clinical trials are expected to study nearly 1,800 patients across more than 100 centers worldwide.

duced by Boston Scientific, the Eluvia platform, which has performed admirably in its first human experience, the MAJESTIC trial (57 patients). This DES has a polymer coating designed to allow a sustained elution of the paclitaxel from its surface beyond 1 year in keeping with the temporal biology of SFA restenosis (Figure 1), rather than in the early burst pattern seen in the Zilver PTX device that has no polymeric coating. The MAJESTIC study demonstrated remarkable 1-year outcomes with Eluvia, with a primary patency of 96.1%. At the 2016 CIRSE meeting, the 2-year data were reported, showing an equally remarkable and unprecedented freedom from target lesion revascularization of 92.5%, with 91% of patients reporting little or no claudication symptoms or limitations (Figure 2).

Even more exciting is the current head-to-head IMPERIAL trial, the first of its kind for antiproliferative SFA therapies, comparing the Zilver PTX and Eluvia platforms in a randomized fashion. This trial will better inform the DES choices for operators in the SFA and will begin to replace the usual, but only semiquantitative, post-hoc unbalanced comparisons between trials of different devices not directly tested against each other. The trial is more than halfway completed enrollment and is enrolling quickly. Results should be available in 2018.

Additional clinical data in a less select, real-world population of patients will be obtained from two further studies in Europe (Figure 3). The 750-subject EMINENT trial is currently enrolling in Europe, randomizing Eluvia to BMS in a 2:1 ratio. EMINENT will also provide important economic data that will inform decision making on device selection and the clinical returns for the patient at the payer level as well. The second trial currently underway is the REGAL Registry, which will enroll 500 nonrandomized patients, also in a broad anatomic and clinical group of patients in order to further extend the indications for this promising technology. ■

1. Dippel EJ, Makam P, Kovach R, et al; EXCITE ISR Investigators. Randomized controlled study of excimer laser atherectomy for treatment of femoropopliteal in-stent restenosis: initial results from the EXCITE ISR trial (EXCImer Laser Randomized Controlled Study for Treatment of FemoropopliTEal In-Stent Restenosis. JACC Cardiovasc Interv. 2015;8:92-101.

2. Fanelli F, Cannavale A, Gazzetti M, et al. Calcium burden assessment and impact on drug-eluting balloons in peripheral arterial disease. Cardiovasc Intervent Radiol. 2014;37:898-907.

3. Tellez A, Dattilo R, Mustapha JA, et al. Biological effect of orbital atherectomy and adjunctive paclitaxel-coated balloon therapy on vascular healing and drug retention: early experimental insights into the familial hypercholesterolaemic swine model of femoral artery stenosis. EuroIntervention. 2014;10:1002-1008.

4. Zeller T. DEFINITIVE AR: a pilot study of antirestenosis treatment. Presented at Vascular InterVentional Advances (VIVA); November 4-7, 2014; Las Vegas, NV.

William A. Gray, MD
System Chief of Cardiovascular Services
Main Line Health
President
Lankenau Heart Institute
Wynnewood, Pennsylvania
grayw@mlhs.org
Disclosures: Consultant for Boston Scientific Corporation.

Sponsored by Boston Scientific Corporation

Global Perspectives on Drug-Eluting Technologies

Prof. Thomas Zeller, MD
Department of Angiology
Universitaets-Herzzentrum
Freiburg-Bad Krozingen
Bad Krozingen, Germany
thomas.zeller@universitaets-herzzentrum.de

Disclosures: Receives honoraria from Abbott Vascular, Angioslide, Bard Peripheral Vascular, Veryan, Biotronik, Boston Scientific Corporation, Cook Medical, Cordis Corporation, Gore & Associates, Medtronic, Spectranetics Corporation, Straub Medical, TriReme, VIVA Physicians, GLG, Philips; consultant for Abbott Vascular, Bard Peripheral Vascular, Boston Scientific Corporation, Cook Medical, Gore & Associates, Medtronic, Spectranetics Corporation; research, clinical trial, or drug study funds received from 480 Biomedical, Bard Peripheral Vascular, Veryan, Biotronik, Cook Medical, Cordis Corporation, Covidien, Gore & Associates, Abbott Vascular, Medtronic, Spectranetics Corporation, Terumo Interventional Systems, TriReme, Philips.

What factors specific to your region have contributed to the adoption of drug-eluting therapies in the peripheral arteries?

Two factors contributed to the adoption of drug-eluting therapies in Germany. First of all, there were convincing trial data demonstrating the superiority of drug-eluting technologies over what was considered the current standard of care (plain old balloon angioplasty [POBA] with provisional stenting). These data were derived from the Zilver PTX (Cook Medical) trial series for drug-eluting stents (DESs) and multiple drug-coated balloon (DCB) studies for different devices.[1-4] The second and ultimately more important driver for adoption of new therapies was reimbursement. Unfortunately in Germany, drug-eluting device-specific reimbursement was established only for DCBs as an add-on payment on top of the Operationen- und Prozedurenschlüssel code-driven diagnosis-related payment for an in-hospital interventional treatment. To establish a dedicated DES reimbursement in the future, additional DES trials in the superficial femoral artery (SFA) are mandatory for proving a beneficial class effect of DES in this particular vessel territory.

Do you expect we will see adoption of drug-eluting technologies continue to increase over time? What evolution do you anticipate to occur with reimbursement for drug-eluting technologies considering the positive outcomes in drug-eluting clinical trials?

With additional companies entering the DCB market, the percentage of DCB users will increase in Germany as long as the reimbursement system will cover the additional device costs in the future. A second aspect of DCB adoption is its efficacy below the knee (BTK). To date, we have only positive outcome data for DCB use above the knee. No independently controlled study has yet shown any efficacy of DCBs in BTK interventions. The BTK market is at least as important as the femoral market, because for long BTK lesions, no comparable treatment options regarding longer-term durability exist in this particular vessel territory. For short lesions (defined as < 10 cm), coronary DES platforms have shown excellent BTK patency data and therefore have become the first-line treatment choice in most institutions. The YUKON BTK study was able to show a significantly reduced overall amputation rate 2 years after DES treatment when compared to bare-metal stenting.[5] However, for longer lesions, POBA is still considered the gold standard with all the device-specific limitations. As such, the interventional community is eagerly waiting for the first positive randomized controlled trial proving superiority of DCBs over POBA in tibial interventions.

In terms of DES use in femoropopliteal lesions, the MAJESTIC study continues to show outstanding clinical results at 2 years with a 92.5% freedom from target lesion revascularization (TLR) rate and 91% of patients had no or minimal claudication.[6] In addition, larger comparative trials are mandatory to evaluate the performance of the Eluvia DES (Boston Scientific Corporation) in longer lesions and compared to last-generation bare-metal stents and DCBs. Should these upcoming studies confirm the initial positive experience with this particular DES, payers should be willing to cover additional device costs due to the potential long-term cost savings.

1. Dake MD, Ansel GM, Jaff MR, et al. Durable clinical effectiveness with paclitaxel-eluting stents in the femoropopliteal artery: 5-year results of the Zilver PTX randomized trial. Circulation. 2016;133:1472–1483.
2. Laird JR, Schneider P, Tepe G, et al. Sustained durability of treatment effect using a drug-coated balloon for femoropopliteal lesions: twenty-four month results of the IN.PACT SFA randomized trial. JACC. 2015;66:2329–2338.
3. Tepe G, Schnorr B, Albrecht T, et al. Five-year follow-up data of the thunder trial: angioplasty of femoro-popliteal arteries with drug coated balloons. JACC Cardiovasc Interv. 2015;8:102–108.
4. Rosenfield K, Jaff MR, White CJ, et al. Trial of paclitaxel-coated balloon for femoropopliteal artery disease. NEJM. 2015;373:145–153.
5. Rastan A, Brechtel K, Krankenberg H, et al. Sirolimus-eluting stents for treatment of infrapopliteal arteries reduce clinical event rate compared to bare-metal stents: long-term results from a randomized trial. JACC 2012;60:587–591.
6. Müller-Hülsbeck S. Two-year MAJESTIC results. Presented at: Cardiovascular and Interventional Radiology Society of Europe (CIRSE); September 20, 2016; Barcelona, Spain.

Antonio Micari, MD, PhD
Interventional Cardiologist
Maria Cecilia Hospital,
GVM Care and Research
Cotignola, Ravenna, Italy
micariantonio@gmail.com

Disclosures: Consultant for Medtronic, Bard Peripheral Vascular, and Terumo Corporation.

What factors specific to your region have contributed to the adoption of drug-eluting therapies in the peripheral arteries?

Peripheral artery angioplasty is often a technically challenging procedure, but it is successful in most cases; however, mid- and long-term efficacy in terms of vessel patency remain a problem. In either the SFA or in tibial arteries, we know that the restenosis rate of POBA is not acceptable. TLR occurs in about 30% of SFA cases and in 45% of BTK angioplasties. This clearly depicts the existence of an unmet need to be solved by drug-eluting technologies. DCBs and DESs have shown very satisfactory results, both in randomized controlled trials and global registries, at least in TASC A and B lesions. Further studies are ongoing for TASC C and D lesions with longer follow-up. Several companies have invested in robust DCB clinical programs, and data generated by evidence-based medicine are definitely more convincing than just marketing initiatives.

When asked whether DCBs or DESs are better, my answer is that they are complementary. If new-generation DESs confirm the preliminary results, which have been striking, I believe we will use DES as the first option in some subsets of lesions (eg, one-stent lesion, calcified, ostial).

BTK interventional therapy is an area of intense interest right now. How do you believe drug-eluting technologies will advance the treatment of BTK disease in the next 3 to 5 years?

BTK disease and critical limb ischemia (CLI) are challenging and complicated clinical settings that are considered controversial battlefields. Initial results of DCBs in BTK arteries have been very confusing. After an analysis of the results from the IN.PACT DEEP trial, Medtronic recalled their In.Pact Amphirion DCB from the market. However, many investigator-driven registries in high-volume, highly experienced centers had opposite results. I believe that many factors influenced the failure, and I think that second-generation DCBs with better-designed trials will provide us with a definitive answer. I expect to see restenosis and TLR reduction with DCBs. Coronary DESs and bioresorbable vascular scaffolds have shown very good results, but they are limited to a very selective population of proximal and focal disease, which is quite unusual in CLI.

Konstantinos Katsanos, MSc, MD, PhD, EBIR
Guy's and St. Thomas Hospitals
NHS Foundation Trust
London, United Kingdom
katsanos@med.upatras.gr

Disclosures: Lecture honoraria received from Medtronic and Boston Scientific Corporation, and research support received from Abbott Vascular.

What factors specific to your region have contributed to the adoption of drug-eluting therapies in the peripheral arteries?

Vessel restenosis and recurrent limb ischemia remain the main limitations of POBA and bare-nitinol stents in the femoropopliteal and infrapopliteal arteries. Patients suffering from CLI are at risk of imminent limb loss if not urgently revascularized, whereas those suffering from intermittent claudication may alternatively benefit from programs of independent or supervised exercise therapy as a stand-alone treatment or in combination with early angioplasty in order to augment long-term walking capacity. Hence, prevention of amputations and improvement of limb functional outcomes have been the main driving forces behind adoption of DESs and DCBs in the peripheral arteries in the United Kingdom.

Physicians in the UK and many other European countries are increasingly being incentivized to avoid interventions when possible. Do you believe this is the right health care model for the future? Given the better long-term outcomes demonstrated by drug-eluting technologies, how do you believe these technologies will impact this model?

Paclitaxel-eluting stents and paclitaxel-coated balloons have been consistently shown to inhibit neointimal hyperplasia, improve long-term anatomical outcomes, and thereby reduce the need for repeat limb revascularization procedures.[1,2] In addition, infrapopliteal DESs have been shown to significantly reduce amputations and accelerate wound healing in patients with CLI.[3,4] Furthermore, a recent health economic analysis has highlighted the very favorable cost utility of drug technologies in the femoropopliteal segment. Projected incremental cost-effectiveness ratios were found to be on the order of a few thousand British pounds per quality of life-year

gained and well below the acceptability threshold of the UK National Institute for Health and Care Excellence.[5]

Given that repeat procedures and limb amputations are not only detrimental to quality of life and patient longevity but also pose a significant financial burden for the overall health care budget, peripheral drug technologies are expected to gradually change the landscape of peripheral endovascular treatments by producing more durable results, while saving costs for the UK National Health System. Traditional ineffective treatment pathways would need to be indirectly disinvested, while adoption of innovative drug technologies should be directly incentivized in order to improve patient care and improve clinical outcomes and quality of life. I believe that it is prime time for DCB and DES technologies to help transform the outdated historical standard of POBA and bailout metal stents for a more effective and efficient utilization of health care resources.

1. Katsanos K, Spiliopoulos S, Karunanithy N, et al. Bayesian network meta-analysis of nitinol stents, covered stents, drug-eluting stents, and drug-coated balloons in the femoropopliteal artery. J Vasc Surg. 2014;59:1123-1133 e8.
2. Katsanos K, Spiliopoulos S, Paraskevopoulos I, et al. Systematic review and meta-analysis of randomized controlled trials of paclitaxel-coated balloon angioplasty in the femoropopliteal arteries: role of paclitaxel dose and bioavailability. J Endovasc Ther. 2016;23:356-370.
3. Spreen MI, Martens JM, Hansen BE, et al. Percutaneous transluminal angioplasty and drug-eluting stents for infrapopliteal lesions in critical limb ischemia (PADI) trial. Circ Cardiovasc Interv. 2016;9:e002376.
4. Katsanos K, Spiliopoulos S, Diamantopoulos A, et al. Wound healing outcomes and health-related quality-of-life changes in the ACHILLES trial: 1-year results from a prospective randomized controlled trial of infrapopliteal balloon angioplasty versus sirolimus-eluting stenting in patients with ischemic peripheral arterial disease. JACC Cardiovasc Interv. 2016;9:259-267.
5. Katsanos K, Geisler BP, Garner AM, et al. Economic analysis of endovascular drug-eluting treatments for femoropopliteal artery disease in the UK. BMJ Open. 2016;6:e011245.

Yann Gouëffic, MD, PhD
Professor and Chief
Department of Vascular Surgery
University Hospital of Nantes
Nantes, France
yann.goueffic@chu-nantes.fr

Disclosures: Consultant for Boston Scientific Corporation, Cook Medical, Hexacath, Medtronic, Perouse, and Spectranetics Corporation.

What factors specific to your region have contributed to the adoption of drug-eluting therapies in the peripheral arteries?

In France, the adoption of drug-eluting therapies is currently low. For example, DESs represent < 3% of the total implanted stents for peripheral disease. Different reasons could explain the reluctance to develop the use of drug-eluting therapies in France. Cardiologists have been long been exposed to the physiopathology of restenosis and understand the need to prevent or to treat restenosis. Despite French vascular surgeons' involvement in endovascular procedures for peripheral artery disease since the late 1990s, a deficit of education regarding restenosis physiopathology still exists. This could explain the low adoption of drug-eluting therapies.

Secondly, the French market is characterized by a reimbursement system where only implantable devices are reimbursed. Implantable devices, such as stents, are reimbursed separately from the diagnosis-related groups (DRGs). On the contrary, DCBs are not considered as implantable, and thus are not reimbursed, which decreases the level of DCB adoption in routine practice.

Finally, it is noteworthy that few data are available to help the physician choose the right devices to treat the right lesions. Indeed, femoropopliteal trials have shown the superiority of drug-eluting therapies over balloon angioplasty, but so far no recent study has focused on comparisons such as drug-eluting therapies versus bare-metal stents or DESs versus DCBs. Furthermore, for BTK treatment, the clinical advantages of drug-eluting therapies over POBA have yet to be demonstrated.

How do the dynamics of your local health care system and economic environment impact the use of drug-eluting technologies? How do you anticipate it changing in the next 3 to 5 years?

Last month, the French health care system announced promising changes for peripheral vascular interventionists. Until recently, Zilver PTX was the only DES that was reimbursed by the French health care system. Now, a second DES (Eluvia) is being reimbursed. Thanks to a last-generation platform (Innova, Boston Scientific Corporation) and a polymer-based sustained drug release, Eluvia offers new options for physicians who want to improve femoropopliteal endovascular treatment outcomes with regard to decreasing in-stent restenosis and reintervention in their routine practice. The EMINENT and IMPERIAL trials, currently in process, should provide additional data over the next few years.

In December 2015, the French health care system modified its policy to allow the reimbursement of innovative and nonimplantable devices. Consequently, DCBs could potentially benefit from this new policy. Discussions are now underway to determine the reimbursement price. Given the anticipated duration of this process, DCBs could be reimbursed in France in 2017.

Currently, stents are not included in the DRGs and therefore benefit from a separate reimbursement. There are rumors that this could change in the next few years and that stents could be included in the DRGs, which would certainly make stents less profitable. There is no doubt that including drug-eluting technologies in the DRGs could alter their use according their reimbursement price. This is why high-level evidence-based medicine is mandatory to establish device choice not only on economic parameters, but also in a patient's best interest. ■

Boston Scientific
Advancing science for life™

REVELUTIONIZE
YOUR PRACTICE

Leveraging more than a decade of market leadership, Boston Scientific is the only company investing in a complete portfolio of drug eluting technologies designed to treat simple and complex SFA lesions.

The evolution of a revolutionary treatment

2000
First clinical results on paclitaxel-eluting stents

More than **six million** patient implants worldwide

More than **34,000** patients studied in clinical trials

Ranger™
Paclitaxel-Coated PTA Balloon Catheter

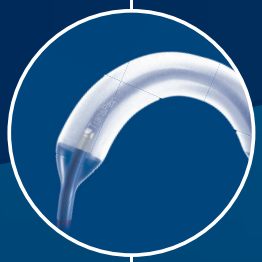

2014
Ranger DCB launched in the EU

Eluvia™
Drug-Eluting Vascular Stent System

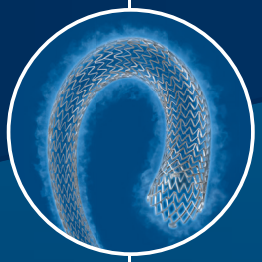

2016
Eluvia stent system introduced

CAUTION: The law restricts these devices to sale by or on the order of a physician. Indications, warnings and instructions for use can be found in the product labeling supplied with each device. Information for the use only in countries with applicable health authority product registrations. This material is not for use or distribution in France. Eluvia is a registered or unregistered trademark of Boston Scientific Corporation or its affiliates. All other trademarks are property of their respective owners. Ranger Paclitaxel-Coated PTA Balloon Catheter is owned by Hemoteq AG. Eluvia and Ranger are not available for sale in the US.
©2016 Boston Scientific Corporation or its affiliates. PI-429108-AA OCT2016 DINPER4689EA

DINPER4689EA