

# Partial Right Atrial Inflow Occlusion for TEVAR

A novel technique for inducing controlled hypotension to facilitate endograft deployment during thoracic endovascular aortic repair.

BY W. ANTHONY LEE, MD

**A**ortic impulse [ $P \text{ (mm Hg)} \times A \text{ (m}^2) \times \Delta t \text{ (s)}$ ] is directly proportional to the mean blood pressure ( $P$ ), the cross-sectional area of the aorta ( $A$ ), and the duration of systole ( $\Delta t$ ), and generally varies inversely with the distance from the aortic valve. High aortic impulses can cause significant pulsatile motion of the arch and inadvertent movement of endovascular devices during deployment. Therefore, precise deployment of endografts and performance of other adjunctive ballooning and/or stenting near the arch or the proximal descending thoracic aorta may occasionally require induction of transient hypotension. In this article, a novel technique is described for rapid induction of systemic hypotension in a reproducible and reversible manner by reducing the ventricular preload and cardiac output without the use of any vasoactive pharmacologic agents.

## TECHNIQUE

The common femoral vein is accessed using a standard Seldinger technique. If open exposure is used to introduce the endovascular delivery system, the adjacent femoral vein can be easily exposed through the same incision. A small 5-0 polypropylene purse-string suture is placed in the femoral vein, and transvenous access is obtained under direct vision. When the ipsilateral vein is thrombosed or inaccessible, the contralateral femoral vein may be percutaneously accessed. A guidewire is advanced from the inferior vena cava (IVC) into the superior vena cava (SVC) or one of the brachiocephalic veins, and a 12-F introducer sheath is inserted (Figure 1A).

A compliant occlusion balloon (eg, Reliant stent graft balloon catheter [Medtronic, Inc., Minneapolis, MN]) is introduced through the 12-F venous sheath and advanced to the right atrium, which is just cephalad to the medial diaphragmatic shadow seen on an anteroposterior fluoroscopic projection (Figure 1B). The balloon is manually inflated through a stopcock with a 30-mL syringe filled with a 25% contrast-saline mixture to achieve a balloon diameter of 25 to 30 mm (15–25 mL), and the stopcock is closed. Correct atrial positioning may be confirmed with a small injection of contrast (Figure 1C) through the guidewire port of the balloon catheter or simply by a globular appearance (Figures 1D and 1E) of the balloon without any oblong deformity that would typically be seen if it were inflated in the IVC.

The inflated balloon catheter is now retracted until the operator feels a firm resistance at the atriocaval junction resulting in occlusion of IVC inflow to the right atrium. An assistant applies constant traction to the balloon catheter during the entire time that hypotension is desired. Excessive force should be avoided to prevent inadvertent IVC avulsion from the right atrium. The patient's blood pressure is continuously monitored through a peripheral arterial catheter. After initiation of inflow occlusion, systemic blood pressure should begin to decline rapidly, and target hypotension (typically, systolic 50–60 mm Hg) should be achieved in 60 to 90 seconds. If the blood pressure decreases beyond what is desired, the retraction on the balloon catheter is simply relaxed to allow transient return of atrial inflow (Figure 2).

Any devices (eg, endografts, balloons, or stents) that will be used should be positioned before atrial inflow occlusion so that the intervention can be performed immediately upon achieving target blood pressure, and any unnecessary period of hypotension is avoided.

After completing the aortic intervention, the retraction on the atrial balloon is immediately relaxed and pushed up slightly to lift it off the atriocaval junction while simultaneously being deflated. Blood pressure will immediately begin to rise with restoration of normotension within 1 to 2 minutes. At the conclusion of the thoracic endovascular procedure, the balloon, guidewire, and sheath are removed, and the previously placed purse-string suture is used to close the venotomy. In cases of percutaneous access, 15 minutes of manual compression after complete reversal of anticoagulation (activated clotting time < 150 seconds) with protamine sulfate is usually sufficient for hemostasis.

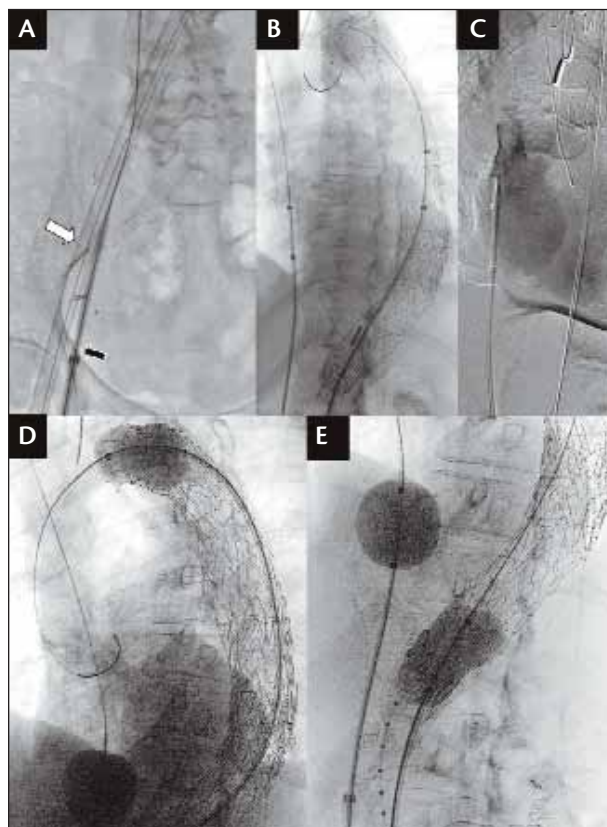
### CLINICAL EXPERIENCE

Between September 2007 and August 2009, the technique of partial right atrial inflow occlusion was applied in 22 cases of thoracic endovascular aortic repair. There were no deaths or complications related to the technique. All of the femoral venous access sites were able to be managed with either direct suture repair of the vein through the primary arterial access site or by manual compression. In all cases, controlled hypotension was able to be induced in 60 to 90 seconds from the time the atrial balloon was inflated and retracted and rapidly reversed within 60 to 120 seconds.

### DISCUSSION

During thoracic endovascular repair, short periods of controlled hypotension are occasionally required to safely and accurately deploy the endograft and perform other types of adjunctive procedures, such as balloon molding and stenting. These adjunctive procedures are obligatory with certain devices (eg, TAG thoracic endoprosthesis [W. L. Gore & Associates, Flagstaff, AZ]) and discretionary with others.

Modulation of systemic pressures is typically achieved pharmacologically using intravenous agents, such as sodium nitroprusside, nitroglycerin, or esmolol for hypotension, and phenylephrine, dopamine, or epinephrine for hypertension. All of these agents have a relatively rapid onset of action and a short half-life in the range of 2 to 5 minutes. However, the dose response of these agents can be highly variable and, in practice, the dose is titrated by either small boluses or graded infusions until the desired effect is achieved. Overshooting the target blood pressure either during induction of hypotension



**Figure 1. Partial right atrial inflow occlusion technique.** Endograft introducer sheath (white arrow) is in the femoral artery, and a 12-F sheath (black arrow) is in the femoral vein (A). Atrial balloon is positioned just cephalad to the diaphragmatic border, and an aortic molding balloon is being advanced through the previously deployed endograft (B). Angiogram through the wire port of the balloon catheter to confirm correct atrial position (C). Balloon molding of the proximal and distal endograft atrial inflow occlusion (D and E).

or during its reversal is common, resulting in a “roller coaster” effect. This may be partially compensated by slowing the rate of infusion of the vasoactive agent, which has the disadvantage of prolonging the length of time it takes to achieve hypotension and, conversely, restoration of normotension upon completion of the intervention. The duration of hypotension may also increase the risk of complications such as stroke and spinal cord ischemia. Furthermore, these vasoactive agents may have deleterious secondary effects in the setting of ischemic heart disease, reactive airway disease, and renal insufficiency.

Other methods of inducing hypotension have also been used in practice. One method involves rapid ven-

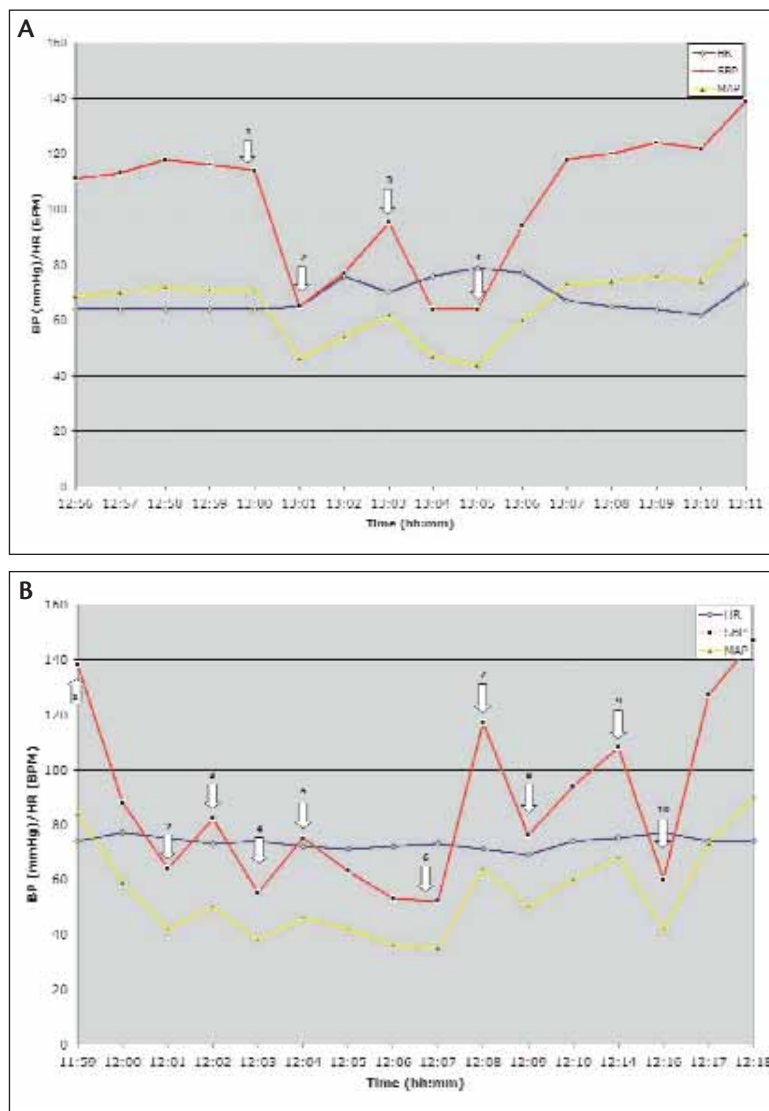
tricular pacing using transvenous pacing wires.<sup>1</sup> Although this technique is reliable and rapid, it is disadvantageous because of the unfamiliarity of most operators with cardiac pacing, the risk of failure of return to normal rhythm, and the increased oxygen demand of a tachycardic myocardium during a period of relative decreased coronary perfusion. It also involves devices that are not part of the typical endovascular armamentarium. The second method is the use of adenosine bolus to induce transient asystole.<sup>2,3</sup> Although effective in most instances, some patients only reach bradycardia instead of asystole, the onset of action and dose response are variable, and duration of asystole is fairly short (a mean of 5 seconds), which may not allow sufficient time to perform the intervention.

The technique of partial inflow occlusion has been previously described by other authors as an effective means to achieve controlled hypotension without the problems encountered with conventional pharmacologic methods.<sup>4,5</sup> By manipulating cardiac preload alone and without reliance on any biochemical adjuncts, this technique is able to induce and reverse systemic hypotension to any desired level in a rapid and safe manner.

Approximately 20% of cardiac output is used to perfuse the coronary arteries and the great vessels supplying the brain (15%) and upper extremities.<sup>6</sup> Of the remaining 80% of aortic blood flow, 65% to 70% of its venous return enters the right atrium from the IVC, with the balance made up from the azygos veins and the coronary sinus. Therefore, by occluding the IVC at the atriocaval junction, the majority of the preload is acutely reduced with concomitant lowering of the cardiac output and systemic blood pressure. Historically, this phenomenon has been observed during management of retrohepatic caval injury requiring IVC occlusion and orthotopic liver transplantation, which can cause severe hypotension immediately after cross-clamping the IVC unless the patient is supported with an atriocaval shunt during the anhepatic phase of the procedure.

In one magnetic resonance imaging

study, the mean diameter of the human infrarenal IVC was  $23.5 \pm 4$  mm.<sup>7</sup> The mean diameter of the suprahepatic IVC in our series based on computed tomography



**Figure 2.** Representative curves of systolic pressure, mean pressure, and heart rate from two patients who required molding balloons after endograft deployment. Pressures were measured from a right radial arterial catheter. In panel A: (1) atrial inflow occlusion initiated, (2) target hypotension reached, (3) proximal aortic molding balloon inflated, and (4) atrial balloon relaxed and deflated. In panel B: (1) atrial inflow occlusion initiated, (2) target hypotension reached, (3) proximal aortic molding balloon inflated, (4) aortic balloon deflated, (5) aortic balloon reinflated, (6) atrial balloon relaxed, (7) distal aortic balloon inflated, (8) distal aortic balloon deflated, (9) distal aortic balloon reinflated, and (10) distal aortic balloon and atrial balloon deflated. Abbreviations: BP, blood pressure; BPM, beats per minute; HR, heart rate; MAP, mean arterial pressure; SBP, systolic blood pressure.

measurements was slightly larger at  $28.1 \pm 3$  mm. Based on the compliance characteristics of the Reliant balloon, a 25-mL inflation (34.4-mm diameter) should achieve sufficient diameter to occlude the IVC in 95% of patients. Although a conventional aortic occlusion balloon was used in our initial experience with this technique, a semicompliant balloon specially designed for this purpose may be desirable. Unlike a globular or tubular shape of currently available occlusion balloons, a funnel (reverse teardrop) shape may allow more effective occlusion of the IVC by wedging into the atriocaval junction and be variably positioned using a constant inflation volume.

We have also considered modification of our technique to bicaval inflow occlusion by introduction of a second balloon catheter through the internal jugular vein, which would be used to occlude the inflow from the SVC as was originally described by Ishiguchi et al.<sup>8</sup> Given the effectiveness of IVC inflow occlusion alone in reducing the blood pressure and the theoretical benefit of preserving myocardial and cerebral perfusion by maintaining some (approximately 20%) level of cardiac output to the coronary and carotid arteries during periods of ballooning, stenting, or any intervention that involves distal aortic arch occlusion, we did not feel the additional technical complexity of a second balloon catheter was justified.

Deep venous thrombosis at the percutaneous insertion site is a recognized complication after femoral vein access for IVC filter placement. Although largely clinically asymptomatic, thrombosis has been identified in 25% to 40% of cases on duplex imaging.<sup>9,10</sup> Duplex imaging was not routinely performed in our series, but standard triple-phase postoperative computed tomography angiography was performed either before discharge or at 1 month in all cases. Examination of the common femoral veins at the sites of insertion did not show any evidence of acute deep vein thrombosis.

## CONCLUSION

Partial right atrial inflow occlusion is a technique that allows for rapid and controlled reduction of systemic blood pressure using simple interventional equipment that is readily available in any practice performing endovascular aortic therapy. We believe that this may be a useful adjunct during endovascular interventions involving the thoracic aorta. ■

*W. Anthony Lee, MD, is Associate Professor of Surgery with the Division of Vascular Surgery and Endovascular Therapy at the University of Florida College of Medicine in Gainesville, Florida. He has disclosed that he is a paid consultant to and*

## COMMENTARY

I congratulate Dr. Anthony Lee for providing a detailed description of a novel and practical technique for inducing controlled hypotension to facilitate endograft deployment during TEVAR. Although the need for inducing hypotension to facilitate accurate deployment of currently available thoracic stent grafts is not always needed, in complex thoracic arch anatomy with large aortic diameter and short proximal landing zones—particularly when the stent grafts need to be placed in proximity to the innominate or the left common carotid artery—precise deployment is essential and requires us to use all the tools in our armamentarium.

Early in one's experience, I would recommend vascular surgeons and interventionists to have a continuous dialogue with the anesthesiologist and use the compliant aortic occlusion balloon that they are most comfortable with, because during balloon inflation under x-ray guidance, one also must appreciate the tactile sensitivity during gauge inflation or use insufflators to maintain balloon pressures at 1 to 2 atm. Furthermore, complete occlusion of the atriocaval junction is not necessary, and aggressive overinflation of the occlusion balloon can potentially result in a tear/avulsion of the IVC, which could be catastrophic. Finally, I believe this is a valuable technique for obtaining rapid and controlled hypotension during thoracic stent graft deployment in patients with complex thoracic arch morphology that might otherwise preclude inadvertent downward displacement of the thoracic stent graft.

—Manish Mehta, MD, MPH

*receives grant/research funding from Cook Medical. He further disclosed that he has patent ownership or part ownership in and a royalty agreement with Cook Medical. Dr. Lee may be reached at (352) 273-5484; anthony.lee@surgery.ufl.edu.*

1. Pornratanarangsri S, Webster MW, Alison P, et al. Rapid ventricular pacing to lower blood pressure during endograft deployment in the thoracic aorta. *Ann Thorac Surg*. 2006;81:e21-23.
2. Baker AB, Bookallil MJ, Lloyd G. Intentional asystole during endoluminal thoracic aortic surgery without cardiopulmonary bypass. *Br J Anaesth*. 1997;78:444-448.
3. De Giovanni JV, Edgar RA, Cranston A. Adenosine induced transient cardiac standstill in catheter interventional procedures for congenital heart disease. *Heart*. 1998;80:330-333.
4. Marty B, Morales CC, Tozzi P, et al. Partial inflow occlusion facilitates accurate deployment of thoracic aortic endografts. *J Endovasc Ther*. 2004;11:175-179.
5. Hata M, Tanaka Y, Iguchi A, et al. Endovascular repair of a descending thoracic aortic aneurysm: a tip for systemic pressure reduction. *J Vasc Surg*. 1999;29:551-553.
6. Lantz BM, Foerster JM, Link DP, et al. Regional distribution of cardiac output: normal values in man determined by video dilution technique. *AJR Am J Roentgenol*. 1981;137:903-907.
7. Kaufman JA, Waltman AC, Rivitz SM, et al. Anatomical observations on the renal veins and inferior vena cava at magnetic resonance angiography. *Cardiovasc Intervent Radiol*. 1995;18:153-157.
8. Ishiguchi T, Nishikimi N, Usui A, et al. Endovascular stent-graft deployment: temporary vena caval occlusion with balloons to control aortic blood flow—experimental canine study and initial clinical experience. *Radiology*. 2000;215:594-599.
9. Blebea J, Wilson R, Waybill P, et al. Deep venous thrombosis after percutaneous insertion of vena caval filters. *J Vasc Surg*. 1999;30:821-828.
10. Aswad MA, Sandager GP, Pais SO, et al. Early duplex scan evaluation of four vena caval interruption devices. *J Vasc Surg*. 1996;24:809-818.