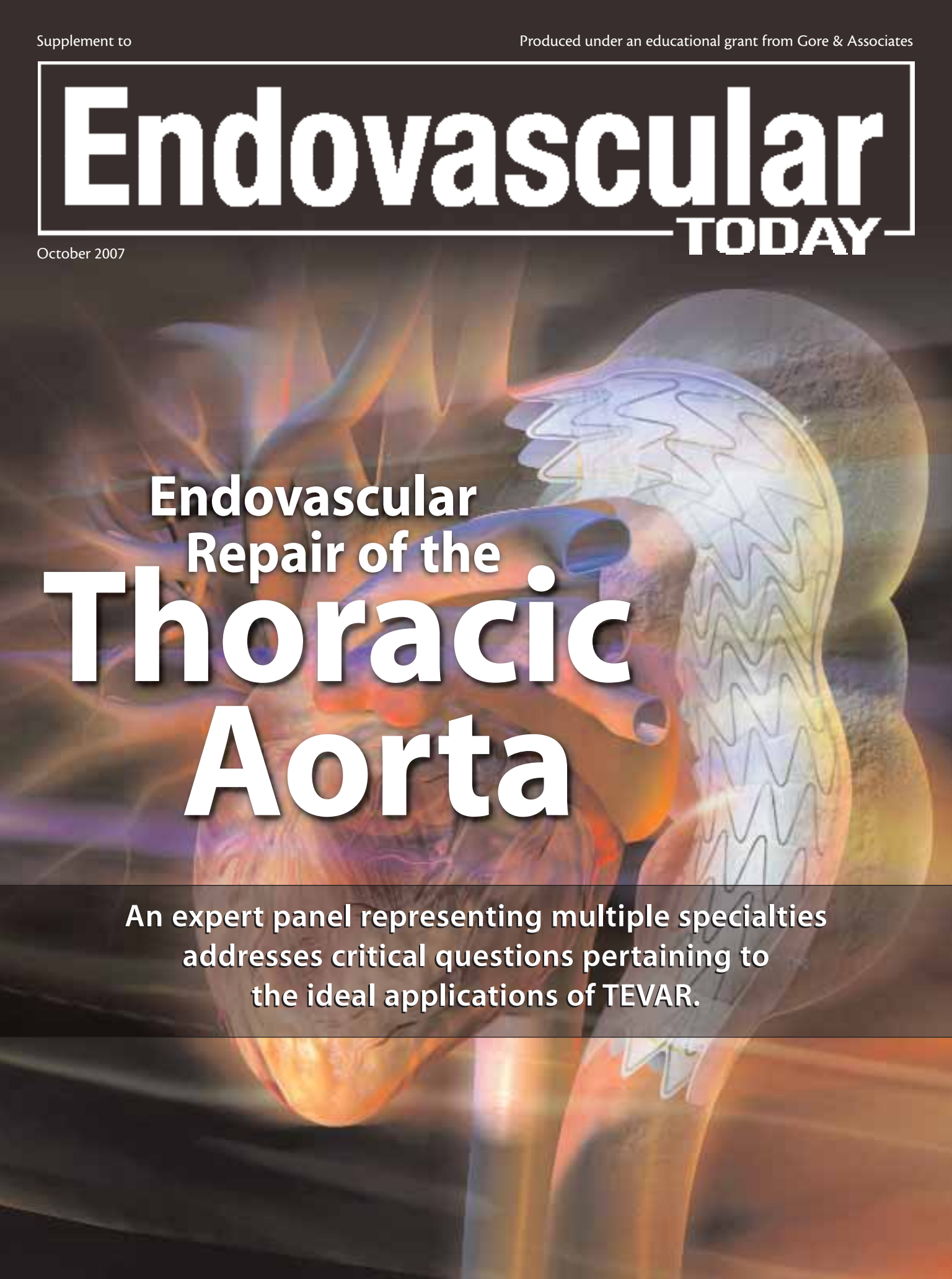


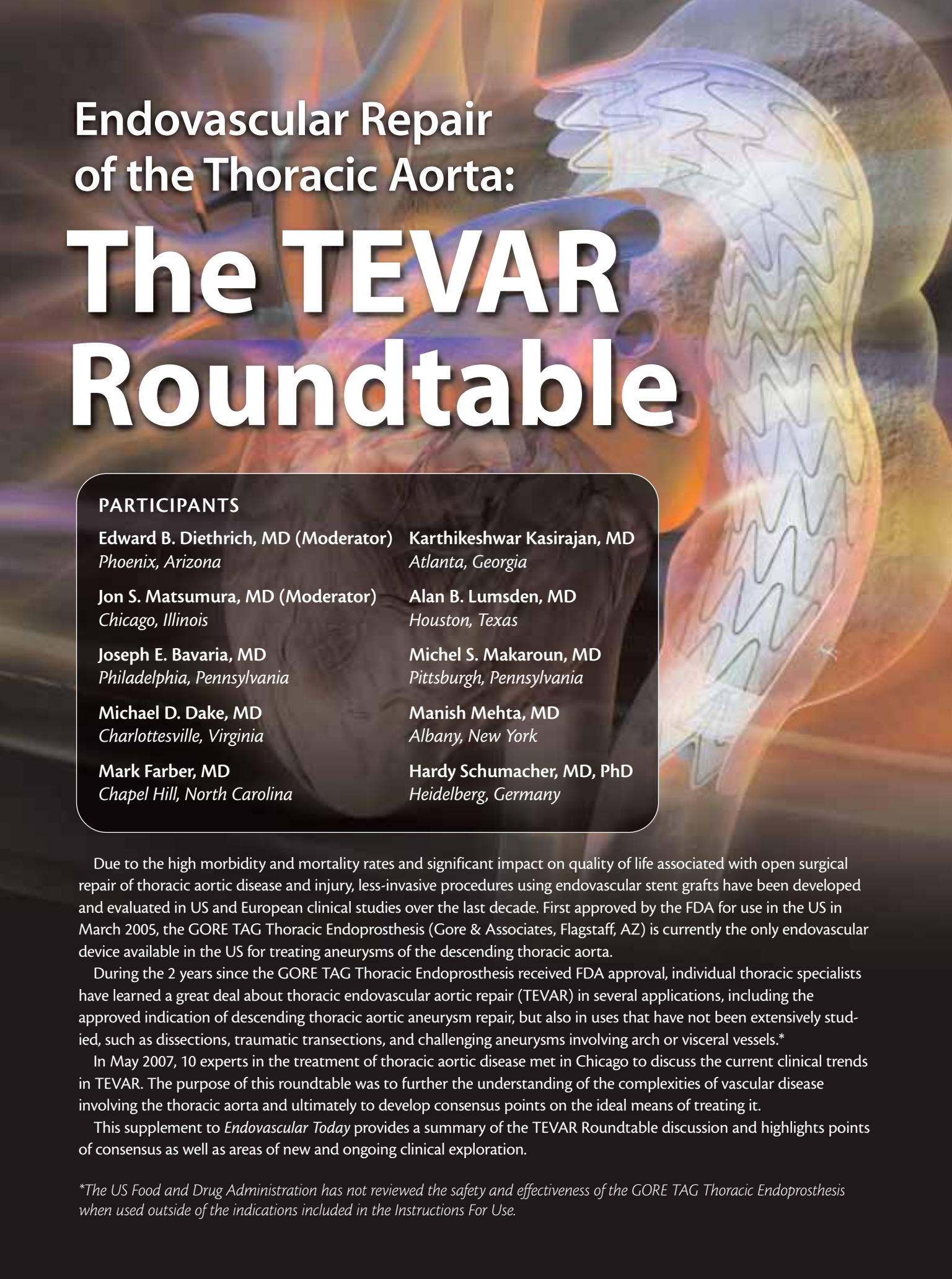
Endovascular TODAY

October 2007

An anatomical illustration of the thoracic aorta, showing the heart and the descending aorta. A stent graft is depicted as a blue, mesh-like structure with a central lumen, positioned within the aorta. The illustration uses a color palette of oranges, yellows, and blues, with a semi-transparent effect to show the underlying anatomy.

Endovascular Repair of the Thoracic Aorta

An expert panel representing multiple specialties
addresses critical questions pertaining to
the ideal applications of TEVAR.



Endovascular Repair of the Thoracic Aorta: **The TEVAR Roundtable**

PARTICIPANTS

Edward B. Diethrich, MD (Moderator) *Phoenix, Arizona*

Karthikeshwar Kasirajan, MD
Atlanta, Georgia

Jon S. Matsumura, MD (Moderator)
Chicago, Illinois

Alan B. Lumsden, MD
Houston, Texas

Joseph E. Bavaria, MD
Philadelphia, Pennsylvania

Michel S. Makaroun, MD
Pittsburgh, Pennsylvania

Michael D. Dake, MD
Charlottesville, Virginia

Manish Mehta, MD
Albany, New York

Mark Farber, MD
Chapel Hill, North Carolina

Hardy Schumacher, MD, PhD
Heidelberg, Germany

Due to the high morbidity and mortality rates and significant impact on quality of life associated with open surgical repair of thoracic aortic disease and injury, less-invasive procedures using endovascular stent grafts have been developed and evaluated in US and European clinical studies over the last decade. First approved by the FDA for use in the US in March 2005, the GORE TAG Thoracic Endoprosthesis (Gore & Associates, Flagstaff, AZ) is currently the only endovascular device available in the US for treating aneurysms of the descending thoracic aorta.

During the 2 years since the GORE TAG Thoracic Endoprosthesis received FDA approval, individual thoracic specialists have learned a great deal about thoracic endovascular aortic repair (TEVAR) in several applications, including the approved indication of descending thoracic aortic aneurysm repair, but also in uses that have not been extensively studied, such as dissections, traumatic transections, and challenging aneurysms involving arch or visceral vessels.*

In May 2007, 10 experts in the treatment of thoracic aortic disease met in Chicago to discuss the current clinical trends in TEVAR. The purpose of this roundtable was to further the understanding of the complexities of vascular disease involving the thoracic aorta and ultimately to develop consensus points on the ideal means of treating it.

This supplement to *Endovascular Today* provides a summary of the TEVAR Roundtable discussion and highlights points of consensus as well as areas of new and ongoing clinical exploration.

*The US Food and Drug Administration has not reviewed the safety and effectiveness of the GORE TAG Thoracic Endoprosthesis when used outside of the indications included in the Instructions For Use.

INDICATIONS FOR ANEURYSMAL INTERVENTION

The meeting began with a discussion about when to intervene in the treatment of descending thoracic aortic aneurysms. The key factors in determining when intervention is indicated are aneurysm size, rate of growth, and individual anatomy and morphology. Although all three elements are of importance, they must be evaluated as a combination when deciding on the appropriate procedural course.

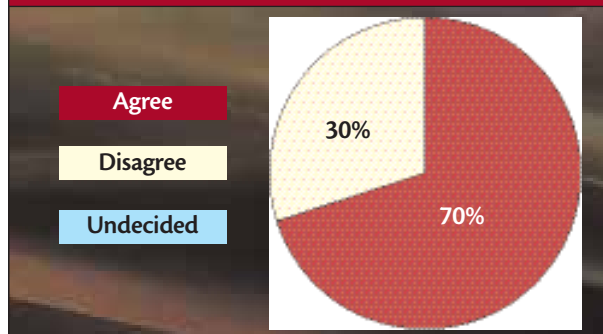
Size

The majority of participants agreed that the safe and conservative threshold for when an aneurysm of the descending thoracic aorta should be treated has traditionally been when the diameter of the aneurysm reaches 6 cm; this threshold was originally determined when open surgery was the only available treatment option. Those physicians who hold to the 6-cm threshold do so because level-1 evidence does not yet exist for endovascular therapy in aneurysms smaller than this diameter. However, many participants also stated that with the availability of an endovascular alternative to open surgical repair, a 5.5-cm aneurysm diameter in a good-risk patient has become the standard threshold for treatment in their daily practices. Dr. Matsumura commented, "TEVAR has introduced us to a treatment that is less morbid, and in some cases, I have lowered my threshold to 5.5 cm in patients who have good anatomy, good access, and long projected survival. A corollary of this individualization of patient management is that some patients have high risk or short projected survival and should not be repaired until a size threshold >6 cm is reached."

Growth

Another factor that plays a considerable role in deciding when to treat a thoracic aneurysm is its rate of growth.

When treating aneurysms of the descending thoracic aorta, the indication for treatment is 5.5 cm diameter or aneurysm growth >1 cm over 1 year.



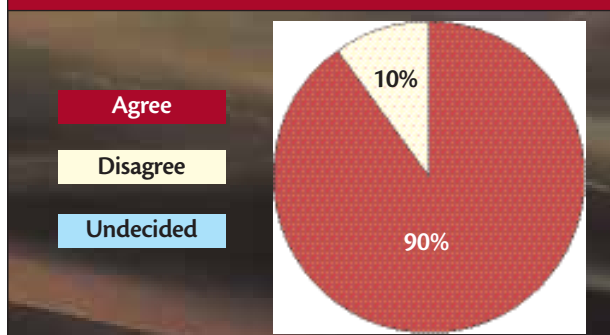
The consensus of this group was that aneurysmal diameter growth of >1 cm over 1 year warrants intervention; however, if the diameter increases approximately 4 mm to 5 mm in a 6-month period, it should be treated promptly even if its diameter is <5.5 cm to 6 cm.

Risk, Anatomy, and Morphology

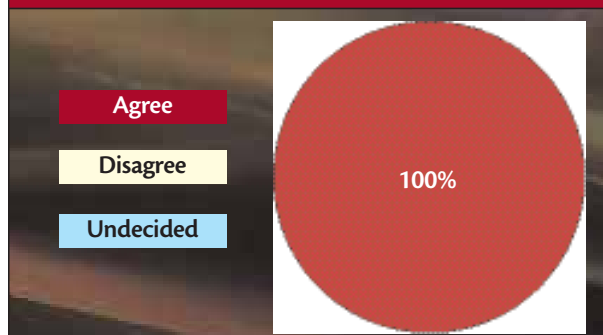
Aneurysmal diameter is also relative to the patient's healthy aortic diameter and likely also to his or her gender, as most women's aortas are smaller in diameter than men's. Patients with abnormal or saccular morphologies, associated symptoms, family history of aneurysms, or longer predicted survival may warrant early intervention despite not meeting the size and/or growth thresholds for treating an aneurysm of typical morphology. "We would operate on saccular aneurysms due to their higher rupture risk, and we would operate on penetrating ulcers at >2 cm to 2.5 cm in the diameter of the sac itself," said Dr. Bavaria.

Dr. Diethrich brought up the emerging trend of patient preference, noting that not only are many patients asking for one therapy over another, some are also asking for early intervention as soon as they are informed they have an

The availability of TEVAR slightly lowers the standard for when intervention is warranted.



In general, TEVAR is preferred over open surgery for the treatment of pseudoaneurysms resulting from previous open operations.



aneurysm. He cited a particular case of a patient living in a remote location, far from emergent care facilities, and the complex decision an interventionist faces in these unique situations. Dr. Mehta echoed the sentiment, adding that there is significant variance from patient to patient—both related to anatomy and lifestyle, and the treatment choice must be tailored to each.

The participants agreed that each decision to intervene is patient-specific, and that no hard number can be used as the standard for all cases, but that the aforementioned guidelines were safe and reasonable.

PREVENTING AND MANAGING SPINAL CORD ISCHEMIA

Risk Assessment

To begin a discussion regarding complications-management strategies, Dr. Makaroun gave a review of clinical data pertaining to the incidence of neurologic complications in both open and endovascular descending thoracic aortic aneurysm repair. He presented a meta-analysis of published studies examining the paraplegia risk associated with repair of aneurysms of the descending thoracic aorta that shows an approximate 3.8% incidence for open repair versus 3% for TEVAR. Perioperative results from the pre-market approval trial of the current version of the GORE TAG Device showed a 2% incidence of paraplegia or paraparesis.

A publication by Carroccio et al classified the causes of spinal cord ischemia (SCI) in open and endovascular procedures.¹ The investigators concluded that one of the mechanisms leading to SCI is the interruption of multiple branch vessels that provide spinal cord perfusion. Sacrificing critical intercostals via either approach can lead to immediate paraplegia, and the length of the replacement or stent graft placement directly relates to the incidence of paraplegia. Another principle introduced by the investigators is that spinal cord perfusion pressure is equal to the mean blood pressure of the patient minus the cerebrospinal fluid (CSF) pressure. Both of these elements can be affected using multiple steps during the procedure (eg, clamping, medications). During TEVAR, episodes of hypotension may occur, with subsequent loss of collaterals; there may be delayed thrombosis of the intercostals. Finally, inflammatory cytokines derived from visceral ischemia may contribute to SCI.

The multiple collateral vessels between the aorta and the spinal cord allow for some collaterals to be sacrificed if necessary to successfully treat a diseased aorta in most cases. Greipp et al reported that no single intercostal is absolutely necessary for spinal cord integrity.² These investigators also stated that the risk of paraplegia increases when more than 10 intercostal pairs are sacrificed. Accordingly, short-seg-

ment replacement is associated with a lower risk of interrupting collaterals and incidence of SCI.

Dr. Makaroun also provided a summary of a recent publication by Safi et al that looked at predictors of delayed neurologic deficit;³ in 854 patients, renal dysfunction was the most significant predictor, with an odds ratio of 5.9, followed by acute dissection (3.9) and extent II replacement (3.0). In this series, 57% of the delayed deficits improved with optimization of CSF pressure and mean arterial pressure.

Prevention Strategies

In 2005, Dr. Bavaria and colleagues published their strategies for managing paraplegia risk after TEVAR.⁴ Their publication advocated the use of selective monitoring (somatosensory-evoked potentials) for patients having previous abdominal aortic aneurysms (AAAs) and in those requiring long replacements. In their series of 75 patients, five experienced paraplegia or paraparesis. However, two of these patients fully recovered as a result of increasing mean blood pressure alone, and there were two full recoveries and one partial recovery as a result of increasing blood pressure and draining spinal fluid. Several other studies have also shown the utility of CSF drainage in preventing and managing paraplegia.⁵⁻⁷

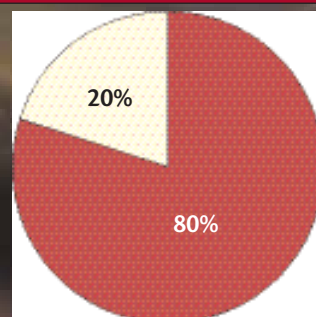
The majority of the roundtable participants agreed that prophylactic CSF drains should be placed before TEVAR in patients who require extensive coverage of the thoracic aorta or in patients with previous AAA repair. However, spinal drainage is not without complications (eg, epidural or subdural bleeds), so it is recommended that CSF drainage be used selectively, on an individual basis. Additional patient groups that may be at increased risk for paraplegia and therefore should be considered for CSF drainage include those with poor pelvic collaterals, those in whom coverage of the left subclavian artery (LSA) is planned, dissection patients, and patients being

CSF drains should be placed before TEVAR in patients requiring extensive coverage of the thoracic aorta or in patients with previous AAA repair.

Agree

Disagree

Undecided



treated with a hybrid approach. Although drainage techniques vary, most of the participants routinely drain pressures of >12 cm H₂O down to between 8 cm H₂O and 10 cm H₂O; most drainage takes place intermittently over the first 24 to 48 hours postprocedure. In addition to CSF drainage, most of the panel members employ increased mean arterial pressure (≥ 90 mm Hg, but <120 mm Hg). Neurocerebral monitoring can be effective both in deciding which patients should have CSF drainage and also for managing the amount and timing of drainage.

Regarding delayed-onset paraplegia, there was agreement that postoperative hypotension is a precipitating factor that can be controlled by the hospital staff. The

staff must be aware of the paraplegic risk, and an emergency protocol should be in place in the event of post-procedural hypotension. Additionally, Dr. Lumsden commented on the importance of educating patients about the potential for delayed paraplegia, saying, "We have had several patients who have gone home with no symptoms of SCI and who have come back paraplegic, for a variety of different reasons. We now give them a letter (see *Patient Education Regarding TEVAR*), and we talk to them about this possibility before they go home. We instruct them to call or come back immediately to the emergency room for aggressive treatment if they notice any change, numbness, or weakness in their legs."

PATIENT EDUCATION REGARDING TEVAR

Dr. Lumsden's practice sends each TEVAR patient home with a letter explaining the nature of thoracic aortic aneurysms and dissections. The letter also informs the patient of the potential complications that may arise after TEVAR, so that if the patient observes any of the warning signs, he will quickly seek emergent care.

Dear Patient,

The aorta, which is the main artery in your body, transports blood from your heart to all other parts of your body. The aorta is defined by the part of the body it runs through. As it courses through your chest, it is called the *thoracic aorta*. At times the aorta will weaken, bulge, or expand, and when it does so in the chest, it is referred to as a *thoracic aortic aneurysm (TAA)*. Only 20% to 25% percent of all aortic aneurysms are in the thoracic aorta.

At times, as the aorta weakens, the blood can push its way between the layers of the aorta, which leads to a dissection or separation of its layers. Depending on which sections of the aorta become involved in the dissection, one can expect a wide range of problems. This is because dissection can lead to the blockage of blood vessels throughout its entire length, including arteries to the spinal cord, brain, intestines, kidneys, and legs. The risk with these thoracic aortic aneurysms is that they can burst or rupture. A ruptured aneurysm can cause severe internal bleeding, possibly leading to death.

Instead of open aneurysm repair, your surgeon has treated you with an endovascular stent graft. *Endovascular* means that the treatment is performed using catheters. After having made a small incision in your groin to gain access to your artery, the catheters are directed through your blood vessels. The graft is placed through these catheters without exposing you to the risks of open surgery. Like the graft used in open surgery, this stent graft allows blood to flow through your aorta without putting any stress on the damaged wall of your

aneurysm, and therefore keeps your aneurysm from rupturing. After endovascular stent graft repair, your recovery will be significantly faster, and you should anticipate being released within a few days. However, this treatment is not widely available, and its long-term results are still not fully known. As such, it is extremely important that ongoing follow-up with periodic scans be performed to evaluate whether the graft is functioning properly. Additionally, you should be aware that reduced blood supply to your spine (spinal cord ischemia) is a potential complication.

Spinal cord ischemia, which causes paralysis of the legs, has always been a devastating complication of surgical repair of aneurysms involving the thoracic aorta. Despite refinements in surgical technique, the risk of postoperative neurologic complications remains significant. Traditionally, open surgical procedures for repair of the thoracic aorta have reported neurological complications in the range of 5% to 21% of patients. Although experience with stent grafts is limited, reports of neurologic complications have been somewhat lower, at about 3% to 12%. Patients who are at particular risk include those with long-segment thoracic aortic repair and those with simultaneous or previous abdominal or thoracic aortic replacement.

Leg weakness can present early during your period of hospitalization, but more importantly, it can occur after your discharge and has been reported to happen up to 30 days after the operation. Presentation of this complication will generally be fairly acute but also progressive and include loss of sensation and strength to the legs. These symptoms can frequently be improved by simple treatments such as increasing blood pressure and reducing cerebrospinal fluid pressure. These treatments must be instituted immediately, and it is therefore imperative that, should you experience these symptoms, you immediately return to the hospital for evaluation by our staff.

(Courtesy of Mark Farber, MD.)

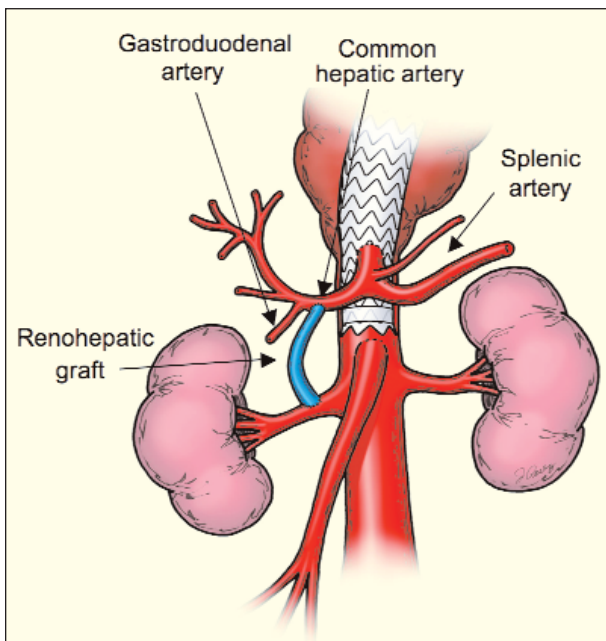


Figure 1. Diagram depicting hybrid thoracic repair involving renohepatic bypass and coverage of the celiac origin.

HYBRID OPEN/ENDOVASCULAR ANEURYSM REPAIR

Aneurysms Involving the Visceral Vessels

Dr. Farber presented his 2006 publication on *Visceral Vessel Relocation Techniques* that can be employed to facilitate endovascular repair.⁸ He reported that upward of 10% to 20% of thoracic aneurysms involve the visceral segment, and that these cases represent an Achilles' heel in thoracic repair. The primary difficulty in treating aneurysms involving the distal thoracic aorta and ending at or near the crus of the diaphragm or in the visceral section is providing adequate fixation and seal for exclusion. One possible solution is to lengthen the distal neck by performing aortic debanching techniques of celiac and/or superior mesen-

(Courtesy of Mark Farber, MD.)

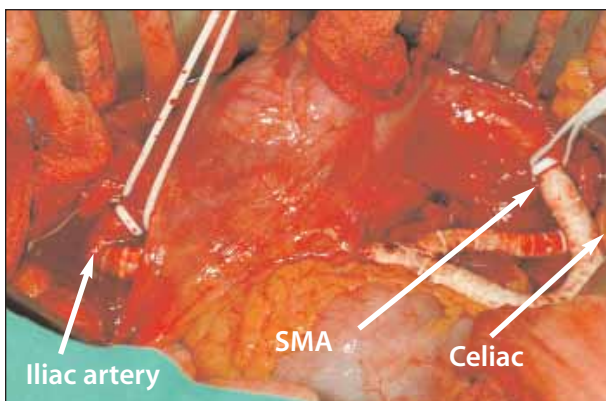
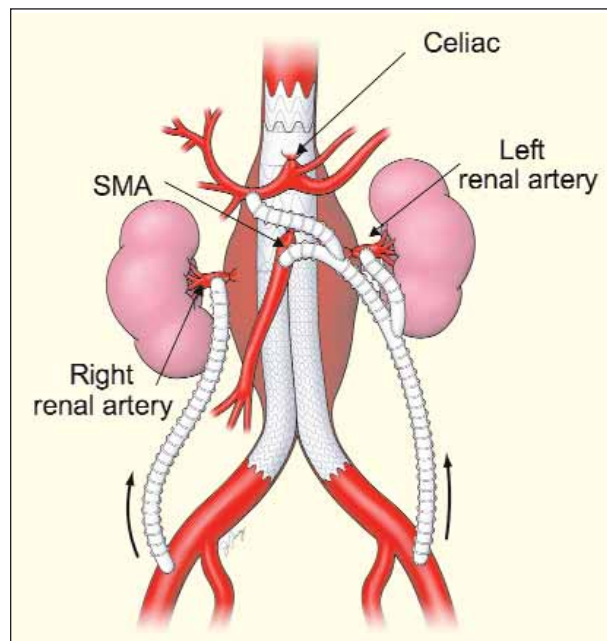


Figure 2. Hybrid thoracic repair involving celiac and SMA reconstructions.



(Courtesy of Mark Farber, MD.)

Figure 3. Diagram depicting total visceral revascularization.

teric (SMA) and/or renal arteries (Figures 1-3). In these patients, this type of hybrid approach can expand the utility of endovascular stent grafts.

The contribution of the celiac artery to the visceral blood flow is variable; this vessel may be stenotic, occluded, or a major contributing vessel. It is not always possible to determine celiac flow from noninvasive imaging alone, and ultrasound, pressure measurement, and collateral angiogram inspection may be required. Options for covering the celiac artery origin include coil embolization (covering the celiac artery without embolization may lead to type II endoleak) and revascularization. Although there are reports of celiac artery coverage without incident, severe complications may arise from either hepatic or pancreatic ischemia, potentially resulting in patient death. Revascularization options include creation of renohepatic, ilioceliac, thoracoceliac, or renosplenic bypasses. Vein or artificial conduit can be used, according to the operator's preference and/or emergent status of the case.

The SMA is considered by many to be the most critical vessel in the visceral vasculature. SMA reconstructions are required in some patients for additional neck length, and some patients may require a bifurcated graft to both the celiac and SMA. Bypass grafting in both of these situations typically comes off of the iliac.

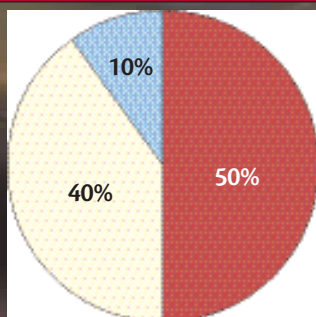
There was considerable discussion among the participants about the value of hybrid techniques versus open surgery for thoracoabdominal aneurysms. According to Dr. Bavaria, "What it comes down to is whether the visceral

To reduce the risk of paraplegia, hybrid procedures for the treatment of thoracoabdominal aortic aneurysms should be performed in stages, rather than simultaneously.

Agree

Disagree

Undecided



debranching operation is better or worse than an open operation.” The participants agreed that visceral vessel debranching is still considerably invasive, but it may have a role in treating some patients—particularly patients who are not good thoracic surgery candidates. Dr. Farber commented, “In general, if you are not a busy center that does a lot of open thoracoabdominal procedures, a hybrid procedure can reduce some of your mortality and morbidity.”

In all of these reconstructions, the proximal portion of the reconstructed vessels should be ligated to prevent type II endoleaks when possible. Postprocedure and follow-up protocol should include blood pressure management and routine monitoring to ensure patency of the bypass grafts and absence of endoleaks. Recommended specific monitoring methods include mesenteric and/or renal duplex ultrasound and CT scan.

The group was divided on whether hybrid procedures should be performed in stages, rather than simultaneously, in order to reduce the risk of paraplegia, indicating that more research is needed in this area. The panel members agreed that in undertaking both the surgical and endovas-

cular portions of the procedure, the operator must also plan for any future surgeries or interventions that may be needed and preserve access options whenever possible. There was also consensus that CSF drains should routinely be used in these patients.

In these challenging cases, many of the roundtable participants consider hybrid repair a viable option in suitable candidates, although some have limited experience in these procedures. It was noted that longer-term data are needed. Additionally, branched and fenestrated devices may provide another viable treatment option, but likewise, there are currently no data to support their use, and there is little access to these devices at the present time.

Aneurysms Involving the Arch Vessels

Dr. Bavaria gave a presentation on debranching and open arch operations to facilitate endovascular repair of thoracic aneurysms involving arch vessels. In patients at high risk for open surgical repair who are unsuitable for endovascular therapy due to inadequate proximal landing zones, hybrid solutions combining stent grafts with great vessel transposition have been explored.⁹⁻¹¹ Several techniques have been attempted, each tailored to unique patient anatomical demands.

Most of the roundtable participants agreed that in TEVAR procedures requiring coverage of the LSA, prophylactic transposition or bypass of the LSA is only necessary if the patient has a dominant left vertebral artery, a left vertebral artery that ends in a posterior inferior cerebellar artery, a left internal mammary artery graft, or if the patient requires extensive stent graft coverage.

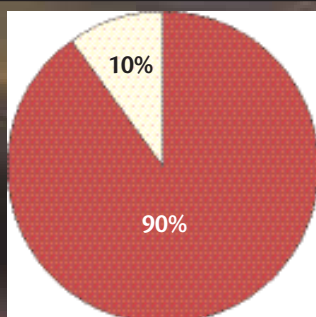
The majority also agreed that in most patients, the distance between the left common carotid artery and the innominate artery is too short to function as a suitable landing zone (zone 1). That said, 90% of the participants

For aneurysms involving the arch vessels, performing a carotid-carotid bypass and a carotid-LSA bypass are appropriate strategies for creating a suitable location for stent graft landing in zone 1.

Agree

Disagree

Undecided

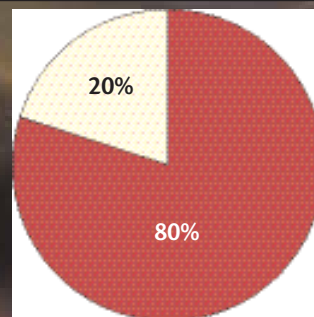


In TEVAR procedures requiring coverage of the LSA, prophylactic transposition or bypass of the LSA is only necessary if the patient has a dominant left vertebral artery, a left vertebral artery that ends in a PICA, a LIMA graft, or the patient requires extensive stent graft coverage.

Agree

Disagree

Undecided



(Courtesy of Alan B. Lumsden, MD.)

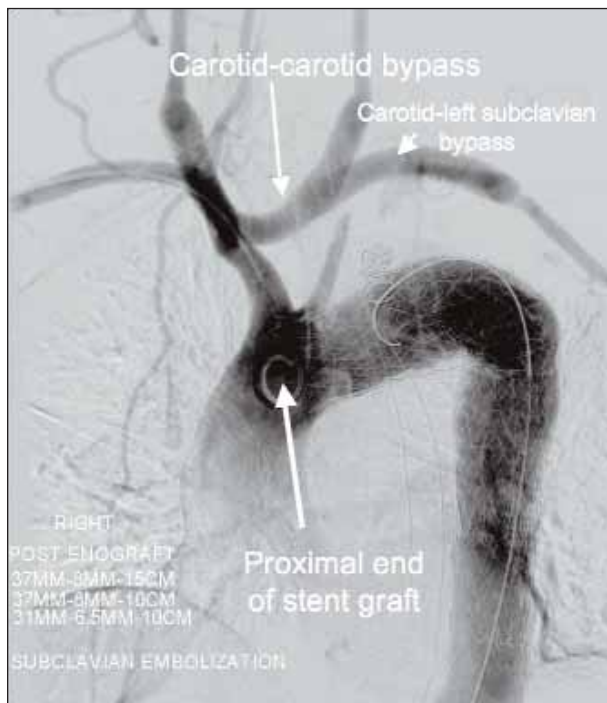


Figure 4. Hybrid repair involving a carotid-carotid bypass and a carotid-LSA bypass followed by endovascular placement of a stent graft.

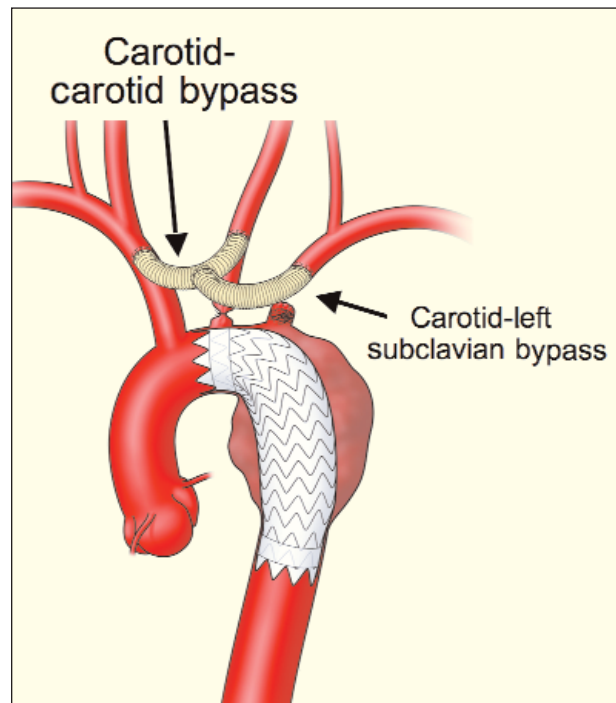
indicated that in patients with suitable anatomy, performing a carotid-carotid bypass and a carotid-left subclavian bypass are appropriate strategies for creating a usable location for stent graft landing in zone 1 (Figures 4 and 5).

DISSECTIONS: MEDICAL MANAGEMENT, STENT GRAFTS, OR OPEN SURGERY

Evaluating INSTEAD

Michael D. Dake, MD, led a discussion on thoracic aortic dissections, beginning with a review of the findings of the INSTEAD trial.¹² INSTEAD was a prospective, multicenter, randomized trial conducted in Europe. The objective of the study was to compare the results of optimal medical therapy and implantation of an endovascular stent graft (Talent; Medtronic Vascular, Santa Rosa, CA) with those of optimal medical therapy alone in patients with type B dissections older than 14 days and younger than 52 weeks. Between February 2002 and May 2005, the trial enrolled 136 subjects into two equal-sized groups. The primary endpoint was all-cause mortality at 1 year.

The INSTEAD investigators reported that at discharge, two patients in the stent graft arm had died, one due to stroke, and the other due to a presumed aortic rupture 5 days after implantation. At 3 months, three additional patients in the stent graft arm had died versus zero in the medical therapy arm. At 1 year, there was a slightly higher rate of all-cause



(Courtesy of Alan B. Lumsden, MD.)

Figure 5. Diagram depicting carotid-carotid and carotid-LSA bypasses.

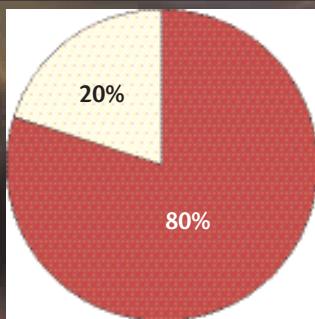
mortality in the stent graft arm (7/70) than the medical therapy arm (2/66), but this difference was not statistically significant. There was a high rate of induced false-lumen thrombosis reported in patients randomized into the stent graft group, and in the medical therapy arm, although a low mortality rate was observed, there was a higher rate of late adverse events. During the first year, seven patients in the medical therapy arm crossed over to the stent graft arm, and there were no deaths in this crossover group; their results were included with the medical therapy arm per intention-to-treat protocol. The preliminary conclusion of the trial was that for uncomplicated type B dissection, careful monitoring and tailored antihypertensive medical therapy is justified, with deferred stent graft implantation being an option for patients failing to respond to medical management alone.

The roundtable participants largely agreed that INSTEAD supported initiating medical management as the best treatment strategy for chronic, uncomplicated type B dissections. However, the INSTEAD trial by its inclusion criteria alone was not designed to produce data or conclusions on how to treat acute dissection patients. The mean time between diagnosis and randomization was 56 days in the stent graft group and 75 days in the medical management group.

The consensus of the group was that a trial is needed to evaluate the use of stent grafts and medical therapy alone in

The results of the INSTEAD trial have not affected my views on how best to treat uncomplicated type B dissections.

Agree
Disagree
Undecided



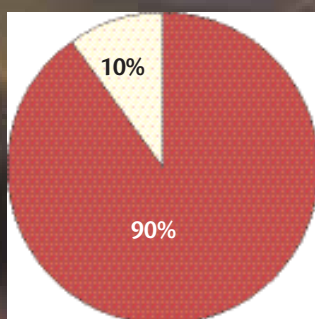
patients with acute uncomplicated type B dissections, because patients treated earlier than 2 weeks after symptom onset may likely have different natural histories and outcomes than patients who are stable for at least 2 weeks. Such a trial would also be more effective with longer-term follow-up. Further, in the current environment that demands high-quality medical evidence for newer treatments, randomized trials must be initiated to evaluate TEVAR for all indications, including those likely to show efficacy, such as in patients with traumatic injury and complicated type B dissection.

ACUTE UNCOMPLICATED TYPE B DISSECTIONS

The participants spent a good deal of time discussing the applicability of stent graft use in treating patients with acute, uncomplicated type B dissections. Most of the roundtable participants agreed that dissections can be considered acute if they are <14 days from symptom onset. Because of a lack of evidence supporting the routine use of endovascular or open surgical procedures in these patients, the group currently recommends the use of medical management. However, Dr. Dake pointed out that the in-hospital

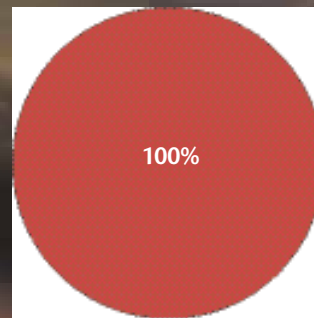
Medical management is currently the most appropriate treatment for acute, uncomplicated type B dissections.

Agree
Disagree
Undecided



In utilizing stent grafts for the treatment of acute type B dissections with distal malperfusion, treatment should consist of covering the primary entry tear and assessing the impact on distal perfusion. If distal perfusion is sufficient, no further treatment is needed to further expand the true lumen.

Agree
Disagree
Undecided



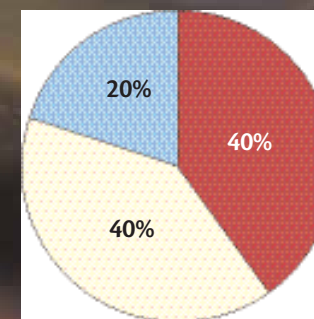
tal mortality rate of these patients enrolled in the IRAD database who were treated with medical management was 10%, and he questioned whether early intervention with a stent graft might prevent these early deaths.¹³

The ADSORB Study

The recently initiated ADSORB study will evaluate the use of best medical therapy versus the GORE TAG Endoprostheses plus best medical therapy in treating acute, uncomplicated type B dissections ≤14 days after symptom onset. ADSORB will prospectively randomize 250 patients (125 test, 125 control) at 25 to 30 European centers. The study's duration will include 1 year of recruitment and 3 years of follow-up. The primary endpoint will be no false-lumen thrombosis at, aortic dilatation at, and rupture at the 1-year follow-up visit.

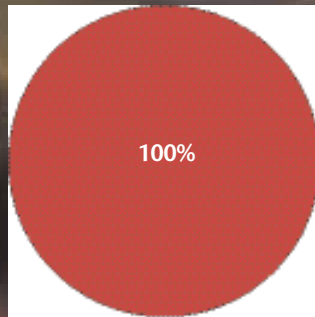
In determining the suitability of a complicated type B dissection for endovascular repair, the radiographic appearance of the septum between the true and false lumens is more relevant than the elapsed time from symptom onset. (A "subacute" classification is needed for these dissections >2 weeks old that are suitable for endovascular repair.)

Agree
Disagree
Undecided



Stent graft oversizing for the treatment of acute complicated type B dissections should be less than that for thoracic aortic aneurysms.

Agree
Disagree
Undecided



ACUTE COMPLICATED TYPE B DISSECTIONS

In contrast to acute uncomplicated type B dissections, the group indicated that acute complicated type B dissections have been studied—albeit to a limited extent. Participants referenced a clinical study that is currently underway that is assessing the utility of stent graft repair using the GORE TAG Device for acute complicated type B dissections as well as traumatic aortic tears and thoracic aortic rupture. While evidence regarding the optimal treatment strategy for patients with acute complicated type B dissections is still being gathered, the consensus of the group was that these patients should be treated using endovascular stent grafts. Results with open surgery and medical management in this population have been dismal, and in the group's experience, stent graft treatment is efficient, effective, and less invasive, with significantly lower morbidity and mortality.

In utilizing stent grafts for treatment of acute type B dissections with distal malperfusion, the procedure should consist of covering the primary entry tear and assessing the impact on distal perfusion. If distal perfusion is sufficient, no additional treatment is needed to further expand the true lumen.

The participants discussed several areas that should be considered when determining the size of the stent graft to implant when treating acute complicated type B dissections. These include the degree to which the false lumen will collapse when the stent graft is deployed in the true lumen, the fact that patients may be abnormally hypotensive during treatment with blood pressures (and aortic diameters) that will rise after the procedure, and the potential for stent grafts to cause acute proximal retrograde dissections. The panel expressed concerns that extreme over- and undersizing could contribute to device compression. The participants unanimously agreed that stent graft oversizing for

the treatment of acute complicated type B dissections should be less than that for thoracic aortic aneurysms.

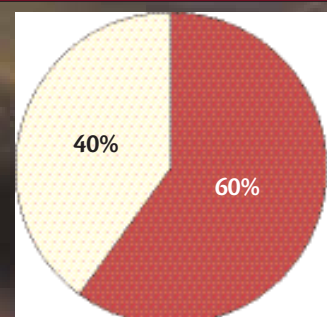
Using a combination of CT and intravascular ultrasound (IVUS; Volcano Therapeutics, Inc., Laguna Hills, CA) can be an effective means of determining the appropriate device size. Dr. Kasirajan pointed out that using CT alone, the image produced will show either the systolic or the diastolic aortic diameter, whereas IVUS can show the range in diameter for each patient and allow the interventionist to freeze the image when the largest diameter is reached. Ballooning is not usually required; if it is necessary to achieve seal, it should only be done cautiously in the proximal portion of the stent graft that lies in nondissected aorta. Follow-up imaging and evaluation should take place at 3, 6, 9, and 12 months, and yearly thereafter.

CHRONIC TYPE B DISSECTIONS WITH FALSE-LUMEN ANEURYSMS

The roundtable participants did not reach consensus on the ideal means of treating patients with chronic type B dissections with false-lumen aneurysm formation. A slight majority of the participants indicated that open surgery is the optimal treatment strategy for most patients with this condition, due to the lack of evidence supporting stent graft therapy in this situation. Anecdotally, stent graft therapy has been effective in treating some DeBakey type III dissections; however, participants expressed concerns about continued false-lumen aneurysm expansion and the effect that false-lumen thrombosis may have on visceral artery perfusion. According to Dr. Makaroun, "I have seen very few patients that have anatomy in which you can land a stent graft and completely exclude a false-lumen aneurysm. By far, the more common anatomic scenario is aneurysm enlargement in the distal thoracic aorta or right at the subclavian and a patent dissection all the way down.

Surgery is the optimal treatment strategy for most patients with chronic type B dissections with false-lumen aneurysm formation.

Agree
Disagree
Undecided

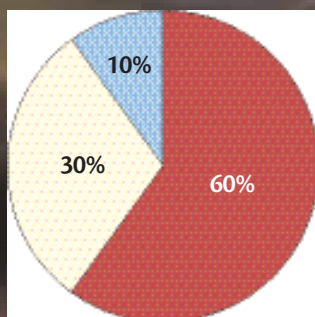


Surgery is the optimal treatment strategy for most patients with type A dissections with primary entry tears distal to the LSA.

Agree

Disagree

Undecided



Clearly, if you cover the area that is enlarged with a stent graft, the retrograde pressure from the patent distal false lumen may still enlarge the aneurysmal portion of the false lumen." A trial evaluating open and endovascular therapies in these patients is needed.

TYPE A DISSECTIONS

The group reported that type A dissections with primary entry tears distal to the LSA are not often seen in their practices, and a single ideal treatment method has yet to be determined. There are no data showing which therapies are or are not effective. The roundtable participants reported using several different treatments, including operative and endovascular repair, as well as hybrid approaches. The gold standard for the treatment of type A dissection is open surgical repair.

TRAUMA AND TRANSECTIONS

The current generation of thoracic endografts is designed for the treatment of aneurysms, and these devices have undergone accelerated fatigue testing out to 10 years. Performance beyond this time period has not been evaluated. However, there was agreement among the panel that endovascular repair is the first option for most trauma patients with suitable anatomy and who are high risk for open surgical repair, regardless of their age. In this acute setting, the panel believes that the short-term benefits of endovascular repair, such as the reduced risk of paraplegia in comparison to open repair, outweigh any potential long-term durability concerns.

CONCLUSION

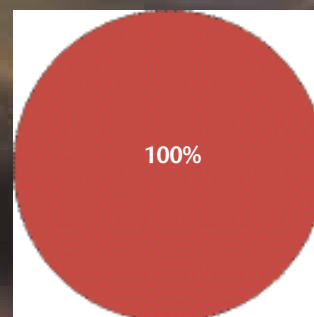
The spirited discussion held by these 10 experts illustrated the highly variable nature of thoracic aortic disease and injury, as well as the information that has been learned through growing clinical experiences, and the many areas in which further study is needed. The emer-

In traumatic transection patients with suitable anatomy, endovascular repair has become the preferred treatment option.

Agree

Disagree

Undecided



gence of an endovascular option provides clinicians and patients with an alternative to the significant morbidity and mortality of open surgical procedures, but only when used in appropriately selected cases. Forums such as this, in which published data and anecdotal experiences are shared and critiqued, aim to further the understanding of aortic disease, the role of today's technologies and procedures, and what we may expect as these therapies evolve. ■

- Carroccio A, Marin M, Ellozy S, et al. Pathophysiology of paraplegia following endovascular thoracic aortic aneurysm repair. *J Card Surg.* 2003;18:359-366.
- Greipp RB, Ergin MA, Galla JD, et al. Looking for the artery of Adamkiewicz: a quest to minimize paraplegia after operations for aneurysms of the descending thoracic and thoracoabdominal aorta. *J Thorac Cardiovasc Surg.* 1996;112:1202-1215.
- Estera AL, Miller CC, Hunyh TT, et al. Preoperative and operative predictors of delayed neurologic deficit following repair of thoracoabdominal aortic aneurysm. *J Thor Cardiovasc Surg.* 2003;126:1288-1294.
- Cheung AT, Pochettino A, McGarvey ML, et al. Strategies to manage paraplegia risk after endovascular stent repair of descending thoracic aortic aneurysms. *Ann Thorac Surg.* 2005;80:1280-1289.
- Weigang E, Hartert M, Siegenthaler MP, et al. Perioperative management to improve neurologic outcome in thoracic or thoracoabdominal aortic stent-grafting. *Ann Thorac Surg.* 2006;82:1679-1687.
- Estera AL, Rubenstein FS, Miller CS, et al. Descending thoracic aortic aneurysm: surgical approach and treatment using the adjuncts cerebrospinal fluid drainage and distal aortic perfusion. *Ann Thorac Surg.* 2001;72:481-486.
- Cinà CS, Abouzahr L, Arena GO, et al. Cerebrospinal fluid drainage to prevent paraplegia during thoracic and thoracoabdominal aortic aneurysm surgery: a systematic review and meta-analysis. *J Vasc Surg.* 2004;40:36-44.
- Farber M. Visceral vessel relocation techniques. *J Vasc Surg.* 2006;43(A):81-84.
- Bergeron P, Mangialardi N, Costa P, et al. Great vessel management for endovascular exclusion of aortic arch aneurysms and dissections. *Eur J Vasc Endovasc Surg.* 2006;32:38-45.
- Zhou W, Reardon M, Peden EK, et al. Hybrid approach to complex thoracic aortic aneurysms in high-risk patients: surgical challenges and clinical outcomes. *J Vasc Surg.* 2006;44:688-693.
- Carroccio A, Spielvogel D, Ellozy SH, et al. Aortic arch and descending thoracic aortic aneurysms: experience with stent grafting for second-stage "elephant trunk" repair. *Vascular.* 2005;13:5-10.
- Nienaber CA. Are aortic stent grafts indicated for uncomplicated type b aortic dissections: results of a randomized controlled trial (INSTEAD trial) comparing endografts to best medical therapy. Paper presented at: VEITH Symposium 2006; November 17, 2006; New York.
- Suzuki T, Mehta RH, Ince H, et al. Clinical profiles and outcomes of acute type B aortic dissection in the current era: lessons from the International Registry of Aortic Dissection (IRAD). *Circulation.* 2003;108(Suppl 1):II312-II317.

5 + 2 + 9

Years of
Pivotal Study
Clinical Data

Years of
Confirmatory Study
Clinical Data

Years of
Commercial Experience
Data

adds up to proven performance.

Demand proven performance.
Demand GORE TAG® Thoracic Endoprosthesis.



When compared to open surgical repair through two years, subjects treated with the GORE TAG® Device experienced**:

- Lower incidence of major adverse events (63% vs. 22% freedom from major adverse events)
- Lower aneurysm-related death (98% vs. 90% freedom from aneurysm-related death)

For Pivotal Study, Confirmatory Study, and Worldwide Commercial Experience data, visit goremedical.com.

**Confirmatory Study (NCT007005)

W. L. GORE & ASSOCIATES, LLC

Flagstaff, AZ 86004

800.437.6361 (US)

928.779.2771 (US)

00000.6334.6678 (EU)

For international contacts and additional product information, visit goremedical.com



Pioneering Aortic Performance

Product(s) listed may not be available in all markets pending regulatory clearance. GORE, TAG®, and Tagore are trademarks of W. L. Gore & Associates, Inc. ©2007 W. L. Gore & Associates, Inc. AUGUST 2011 JUNE 2007

US Indication for Use: The GORE TAG® Thoracic Endoprosthesis is indicated for endovascular repair of aneurysms of the descending thoracic aorta in patients who have appropriate anatomy, including adequate iliac/femoral access, aortic cross-clampable in the range of 255 mm, a2 or nonaneurysmal aortic aneurysm and distal to the aneurysm. Contraindications: There are no known contraindications for this device. Refer to Instructions for Use at goremedical.com for a complete description of all warnings, precautions and adverse events.