

Endovascular TODAY

August 2019



TCAR
REVOLUTION
IN CAROTID REVASCULARIZATION



There is a fundamental educational responsibility for a procedure that has the potential to disrupt a decades-old standard of care. The Vascular Quality Initiative (VQI) transcarotid artery revascularization (TCAR) Surveillance Project (TSP) has great practical worth in this regard through its rapid acquisition of real-world data. One example is Dr. Marc Schermerhorn's analysis of local bleeding after TCAR and its reduction with protamine reversal of heparin (after a test dose) compared to no protamine, constituting an extremely important safety signal.

As worldwide experience with TCAR continues to rapidly accrue, it is also our responsibility at Silk Road Medical to ensure that new learnings are shared with physicians who wish to offer this therapy to their patients, so that pitfalls may be avoided and potential complications are managed effectively with the best possible outcomes. In this *Endovascular Today* supplement, we seek to share those insights to support you in the development of your TCAR programs.

Sumaira Macdonald, MD, PhD, MBChB, MRCP, FRCP, FRCR
Executive Medical Director | Silk Road Medical

TABLE OF CONTENTS

2 Introduction

With Sumaira Macdonald, MD, PhD, MBChB, MRCP, FRCP, FRCR

3 The TCAR Revolution

By Peter A. Schneider, MD

4 Challenging Case: The Consequence of Unmanaged Hypotension After TCAR

By Angela A. Kokkosis, MD, FACS, RPVI

8 Challenging Case: Retrograde Transcarotid Revascularization for Symptomatic Proximal Common Carotid Stenosis

By Peter Rossi, MD, FACS, FSVS

10 Challenging Case: Acute Thrombosed Carotid Stent Recanalization

By Inkyong K. Parrack, MD, and Russell H. Samson, MD, DFSVS

13 The Evidence Base Dictating Practice in Patients With Concomitant Significant Coronary Artery and Carotid Artery Disease

By Sumaira Macdonald, MD, PhD, MBChB, MRCP, FRCP, FRCR; Richard P. Cambria, MD; and Douglas Massop, MD

16 Vascular Quality Initiative: Transcarotid Stenting Project Update

By Marc Schermerhorn, MD, and Patric Liang, MD

18 TCAR Pearls and Pitfalls

By Michael C. Stoner, MD, RVT, FACS, and Jeffrey Jim, MD, MPHS, FACS

20 Identifying Clopidogrel Resistance in the Setting of TCAR

By Edgar D. Guzman, MD, FACS, RPVI, and Jessica Titus, MD

23 TCAR TEST Drive

By Wesley S. Moore, MD, and Michael C. Stoner, MD, RVT, FACS

The TCAR Revolution

BY PETER A. SCHNEIDER, MD

It is not often that a specific approach to therapy comes along and rapidly changes the way we think about or manage a major vascular disease process. Previously, such leaps of progress have included the introduction of stents, endovascular aneurysm repair, and peripheral drug delivery. Within these leaps of progress, there is typically an introduction of the innovation followed by a developmental process, during which the skills and devices are gradually improved, and the therapy is standardized.

Transcarotid artery revascularization (TCAR) has changed the way we evaluate patients with carotid disease. TCAR permits endovascular access with avoidance of the aortic arch and the establishment of protection prior to crossing the lesion. It also results in more complete particle capture than previous protection technologies. The intolerance rate is very low, as oxygenated blood is entrained into the target hemisphere through the process of flow reversal, a concept that may not immediately seem intuitive upon first evaluation. Although any major therapy innovation is an uncommon event, the vascular field has particularly never witnessed the actual quantitative evaluation of the rollout and developmental process so early in the life cycle of the procedure as has occurred with TCAR. The Vascular Quality Initiative TCAR Surveillance Project (VQI-TSP) records all cases, including the learning curve for each physician and institution. There are no “lead-in” cases prior to data entry, hence, the TSP captures all patients, complications, and outcomes regardless of the experience of the treating physicians.¹

Carotid endarterectomy (CEA) has been developed and refined for more than 6 decades and transfemoral carotid stenting (TF-CAS) for more than 2 decades. Results have been excellent with these therapies in the hands of many interventionalists. The comparative data from the past 15 years are well known and have taught us much about carotid disease. Substantial time and effort have gone into refining these therapies, and they will remain in our armamentarium. The introduction of an option like TCAR, which will serve as an alternative to established therapy in certain patients, and ultimately be complementary to our disease management algorithms,

must be followed by well-developed rationale and data sets. The results must speak for themselves.

We have also learned that new white lesions on diffusion-weighted MRI (DW-MRI) can be used as a surrogate for neurological risk in these various procedures. DW-MRI lesions for TF-CAS range from 45% to 87%, and range for CEA from 12% to 25%.²⁻⁴ When TCAR was evaluated in the PROOF study, DW-MRI new white lesions occurred in 18%, which is fairly consistent with CEA.⁵ This may help to explain why the results of TCAR, especially early in its evolution, are on par with, and in some ways, better than established therapies.⁶

New therapies bring new challenges. Avoiding access site injuries such as common carotid artery dissection is key to procedural safety. Deliberate lesion evaluation helps to select patients with carotid disease that are amenable to stent placement, and much of this knowledge has carried over from experience with TF-CAS. Although none of the procedural steps are new or foreign to us, they must be done in the correct sequence and with tight specifications and little leeway for error.

In summary, TCAR is an innovation that has changed the landscape in carotid therapy. ■

1. Malas M. Outcomes of Transcarotid Revascularization with Dynamic Flow Reversal Versus Carotid Endarterectomy in the Transcarotid Revascularization Surveillance Project. Presented at: SVS Vascular Annual Meeting; National Harbor, Maryland; June 12-15, 2019.

2. Bonati L, Jongen LM, Haller S, et al. New ischaemic brain lesions on MRI after stenting or endarterectomy for symptomatic carotid stenosis: a substudy of the International Carotid Stenting Study (ICSS). *Lancet Neurol*. 2010;9:353-362.

3. Bijuklic K, Wandler A, Hazzi F, Schofer J. The PROFI study (prevention of cerebral embolization by proximal balloon occlusion compared to filter protection during carotid artery stenting): a prospective randomized trial. *J Am Coll Cardiol*. 2012;59:1383-1389.

4. Gargiulo G, Sannino A, Stabile E, et al. New cerebral lesions at magnetic resonance imaging after carotid artery stenting versus endarterectomy: an updated meta-analysis. *PLOS ONE*. 2015;10:e0129209.

5. Pinter L, Ribo M, Loh C, et al. Safety and feasibility of a novel transcervical access neuroprotection system for carotid artery stenting in the PROOF study. *J Vasc Surg*. 2011;54:1317-1327.

6. Kashyap V. ROADSTER-2 study results. Presented at: SVS Vascular Annual Meeting; National Harbor, Maryland; June 12-15, 2019.



Peter A. Schneider, MD

Professor of Surgery
Division of Vascular and Endovascular Surgery
University of California at San Francisco
San Francisco, California
peteraschneidermd@gmail.com
Disclosures: Proctor and TEST DRIVE faculty for Silk Road Medical.

The Consequence of Unmanaged Hypotension After TCAR

BY ANGELA A. KOKKOSIS, MD, FACS, RPVI

A 71-year-old man presented to our institution for evaluation of left carotid stenosis noted on duplex imaging to be 70% to 99% and on CTA to be about 90% (Figure 1).

He had a complex medical history of hypertension, hyperlipidemia, antiphospholipid syndrome on lifelong warfarin (INR maintained > 3), right lower extremity deep venous thrombosis in 2003 with subsequent pulmonary embolism and resultant pulmonary hypertension, inferior vena cava filter placement and subsequent filter occlusion, and bone cancer (he underwent localized radiation and chemotherapy, with good prognosis).

In 2010, he suffered an ischemic stroke to his posterior intracranial circulation with visual changes and headaches. He reported residual partial peripheral vision loss to his left eye.

The patient also reported frequent vasovagal episodes, which was never fully elucidated. He was maintained

on 81 mg of aspirin and a statin in addition to his anticoagulation. He had never smoked cigarettes in his life.

TREATMENT OPTIONS

The patient was deemed high risk for left carotid endarterectomy based on his poor pulmonary status secondary to the significant pulmonary hypertension. There was concern for alterations in right ventricular preload or afterload induced by fluid shifts, medications, or changes in the autonomic nervous system, as can occur in open surgery under general anesthesia. Although carotid endarterectomy is not solely performed under general anesthesia and can be accomplished with a regional nerve block, other concerns, such as the long surgical procedure time, were taken into consideration. Ultimately, transcarotid artery revascularization (TCAR) with local anesthesia and minimal sedation was offered to the patient.

MEDICAL MANAGEMENT

Aside from the pulmonary hypertension, the most treacherous component of this patient's perioperative management was the anticoagulation and antiplatelet therapy. Given his significant history for arterial and venous thrombotic events, there was concern for stent thrombosis. After discussion with the hematology and cardiology services, it was decided to maintain the patient on 81 mg of aspirin indefinitely. Standard of care for carotid stent placement includes dual antiplatelet therapy (DAPT), so he was

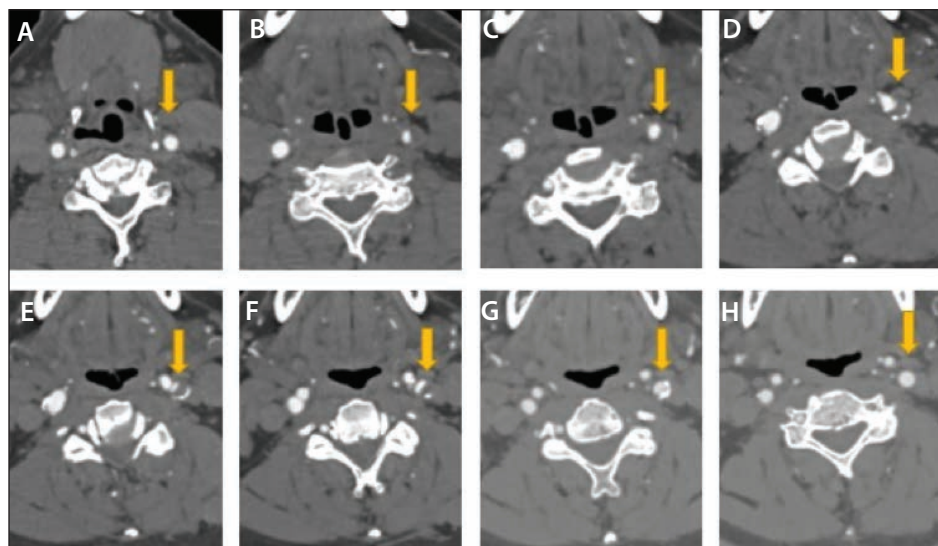


Figure 1. CTA depicting the left carotid stenosis (yellow arrows) from proximal (A) to distal (H). Of note, the right carotid and vertebral arteries were widely patent, and the left vertebral artery was hypoplastic. Not shown here is a hypoplastic posterior circulation secondary to the patient's previous cerebrovascular event.

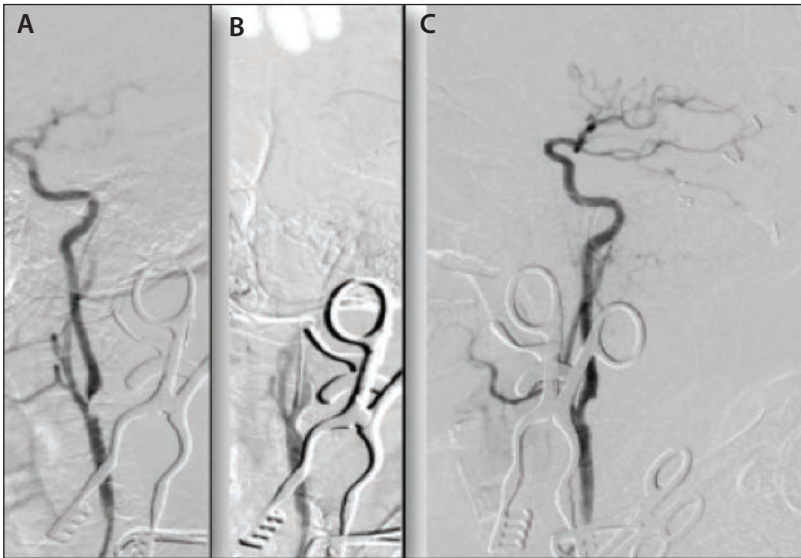


Figure 2. Intraoperative angiograms of the left carotid artery: pretreatment (A), after stenting (B), and after stenting with the intracranial circulation (C).

started on clopidogrel 1 week before surgery, with the intent to discontinue it 1 week after surgery to address the bleeding concern from DAPT and anticoagulation. The warfarin was bridged with enoxaparin 1 week prior to surgery, and the morning dose on the day of surgery was held. Thereafter, enoxaparin was resumed the evening after surgery, with the intent to restart warfarin within a couple days.

PROCEDURE

The patient received local anesthesia (1% lidocaine/0.25% bupivacaine) for the access site, and he was under mild conscious sedation for the carotid exposure before being wakened for the stenting.

The ENROUTE® Transcarotid Neuroprotection System (Silk Road Medical) was connected and placed on the high setting, as is the standard practice. The patient was

asked to squeeze a toy in his hand and answer questions, which he was able to do, confirming a maintained baseline neurologic status.

Several other intraoperative conditions were also confirmed prior to proceeding with stent placement: activated clotting time > 250 seconds after intraoperative administration of heparin, a systolic blood pressure (SBP) of 140 to 160 mm Hg, and adequate flow reversal once the common carotid artery was clamped to occlude the proximal inflow.

The patient was again asked to squeeze the toy and answer questions; however, he now could not perform these actions, demonstrating intolerance to the flow reversal. The carotid artery was unclamped, and after a few seconds, he regained full neurologic function. Based on the principle of “preconditioning,” the carotid was again clamped to test

the patient's tolerance. This time, he was able to squeeze the toy and answer questions. We then proceeded with the case.

The lesion was crossed with a 0.014-inch wire and predilated with a 5- X 20-mm balloon. In anticipation of hypotension with the balloon, atropine was preemptively administered. However, despite the atropine administration, the patient became bradycardic (heart rate dropped to the 40s) and hypotensive (60/40 mm Hg) for about 2 seconds. Another dose of atropine was administered, along with initiation of a phenylephrine drip. The patient's heart rate was normalized to the 70s, and his blood pressure returned to an SBP of 150 to 160 mm Hg.

In assessing the patient's neurologic status, he was unable to follow commands. His blood pressure increased to SBP > 160 mm Hg, and the 9- X 30-mm ENROUTE® Transcarotid Stent was quickly deployed.

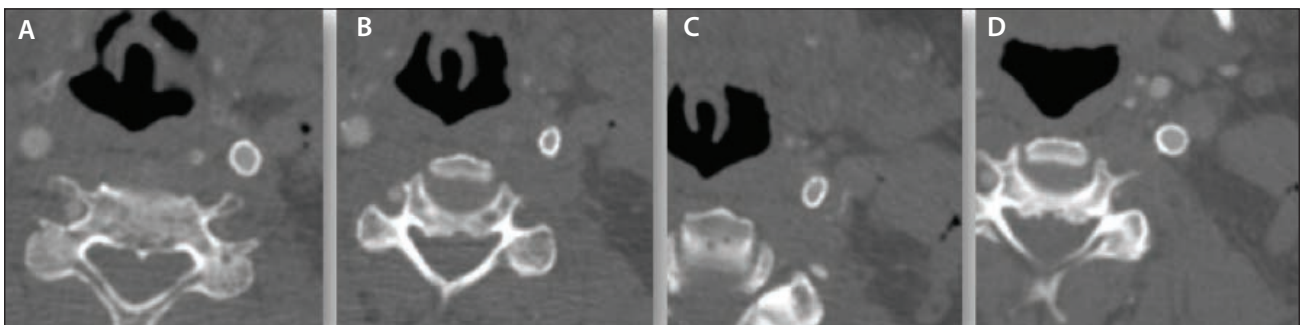


Figure 3. Postoperative CTA demonstrating stent patency from proximal (A) to distal (D).

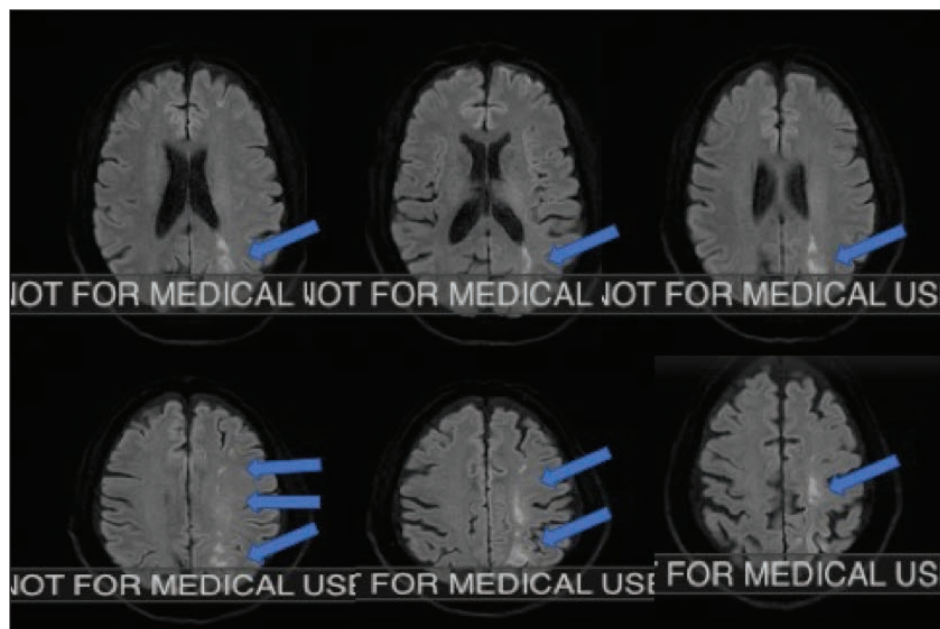


Figure 4. Diffusion-weighted MRI demonstrating the watershed infarct (blue arrows) in the left hemisphere.

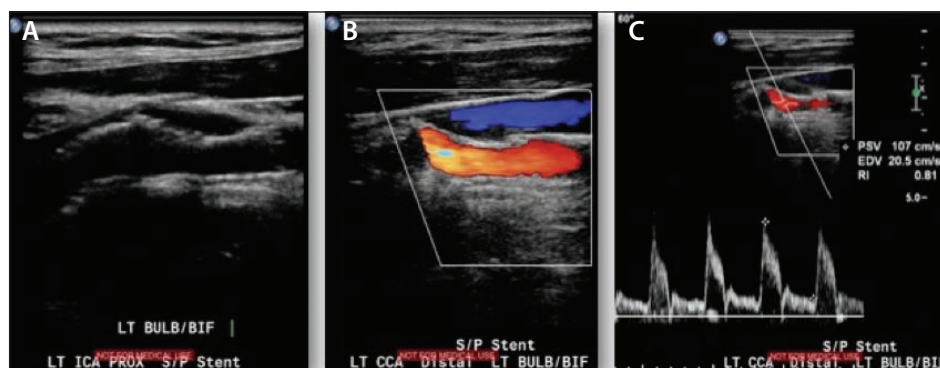


Figure 5. Duplex ultrasound 1 year after TCAR demonstrating a patent left carotid stent on B-mode (A), color flow (B), and Doppler (C).

After stent deployment, a completion angiogram of the carotid stent in two views demonstrated brisk filling without any narrowing of the stent and no significant residual stenosis (Figure 2). An intracranial angiogram was also performed, demonstrating brisk filling of the left side of the brain with maintenance of the intracranial circulation and no evidence of distal embolization (Figure 2C).

The flow reversal system was then disconnected. The common carotid artery was unclamped. The sheath was removed from the common carotid artery, and the preplaced purse-string stitch was cinched to achieve hemostasis.

At this point, the patient's neurologic status returned completely to baseline (alert and oriented, full motor sensory function of upper and lower extremities, no dysarthria, and

no facial droop). The heparin was reversed with 30 units of protamine. He was then taken to the recovery room in stable condition.

RESULTS

Upon arrival to the recovery room, however, the patient demonstrated right hemiparesis and hemineglect while he was being connected to the monitors. His blood pressure dipped to an SBP of 60 mm Hg, and his phenylephrine dose was increased. Both neurology and neurosurgery services were consulted.

A quick bedside duplex ultrasound confirmed that the carotid stent was patent, so he was taken for a CTA (Figure 3) and CT perfusion scan. The CTA demonstrated patent intracranial vasculature and carotid stent. The results of the perfusion scan were normal as well.

With these negative studies, we proceeded to obtain a diffusion-weighted MRI (Figure 4), which demonstrated a left-sided watershed infarct. This finding was likely due to the

few seconds of hypotension with the carotid ballooning, the second hypotensive event in the recovery room, and the patient's baseline dependence of intracranial blood flow on the left carotid artery (with his chronically occluded left vertebral and hypoplastic posterior circulation on preoperative CTA).

The patient regained some neurologic function over the ensuing 2 to 3 hours, was maintained with permissive hypertension (SBP, 160–180 mm Hg), and as previously planned, enoxaparin was resumed that evening.

On follow-up, he regained motor sensory function of his right arm and leg, but sustained permanent loss of his peripheral vision bilaterally. At 1 year, his carotid stent was still widely patent (Figure 5).

DISCUSSION

As a result of this early experience, my practice has changed in the perioperative management of patients undergoing TCAR. It became exceedingly clear that hemodynamic management is vital to the treatment of these patients, and that this point needs to be understood by all parties involved in the patient's care (anesthesia, surgery, trainees, and nursing staff). Every second truly matters when cerebral function is at stake. Recently published data from the Vascular Quality Initiative (VQI) confirms that postoperative hypotension is significantly more common in stented patients as compared to carotid endarterectomy patients in whom hypertension is more common.¹

Instead of atropine administration, which becomes more of a reactive response rather than a protective treatment for hemodynamic changes, I now administer glycopyrrolate in every case once the carotid artery is surgically exposed. The duration of action is longer, and there are less hemodynamic swings. Typically, intracranial views are not recommended during the TCAR procedure due to the potential risk of showering emboli from a freshly angioplastied and stented lesion because the protective flow reversal is temporarily

stopped for the angiogram. However, in this case due to the intraoperative concern of a stroke event, intracranial views were performed.

Education to the whole perioperative team has been clarified to emphasize the high likelihood of hypotension after stenting (secondary to the radial force of the stent on the carotid baroreceptors), and the patient leaves the operating room with the phenylephrine drip and a portable monitor. ■

1. Schermerhorn ML, et al. In-hospital outcomes of transcatheter artery revascularization and carotid endarterectomy in the Society for Vascular Surgery Vascular Quality Initiative. Published online June 18, 2019. *J Vasc Surg*. 2019.



Angela A. Kokkosis, MD, FACS, RPVI

Associate Professor of Surgery
Director of Carotid Interventions
Division of Vascular and Endovascular
Surgery

Stony Brook Medicine
Stony Brook, New York

*Disclosures: Consultant and faculty proctor
for Silk Road Medical.*

Retrograde Transcarotid Revascularization for Symptomatic Proximal Common Carotid Stenosis

BY PETER ROSSI, MD, FACS, FSVS

Symptomatic common carotid artery and/or innominate artery disease is uncommon. Management options for proximal common carotid stenosis include open surgical reconstruction, transfemoral carotid artery stenting, or retrograde transcarotid revascularization (R-TCAR). Origin common carotid or innominate lesions can present procedural difficulties: engaging the lesion can itself be challenging, and distal embolic protection is extremely difficult. R-TCAR can provide a novel approach to these challenging lesions while providing excellent embolic protection with flow diversion to the femoral vein.

CASE REPORT

A 65-year-old man presented to a referring institution with repeated episodes of left-sided amaurosis fugax. Carotid duplex ultrasound revealed tardus parvus waveforms throughout the entire cervical carotid system. Subsequent CTA revealed high-grade common carotid artery stenosis starting 1.5 cm from the aortic arch (Figure 1). Dual antiplatelet therapy was initiated with clopidogrel and aspirin, along with atorvastatin, and recommendation was made for R-TCAR.

Under general anesthesia, the distal left common carotid artery was exposed through a small longitudinal incision. R-TCAR with distal common carotid artery

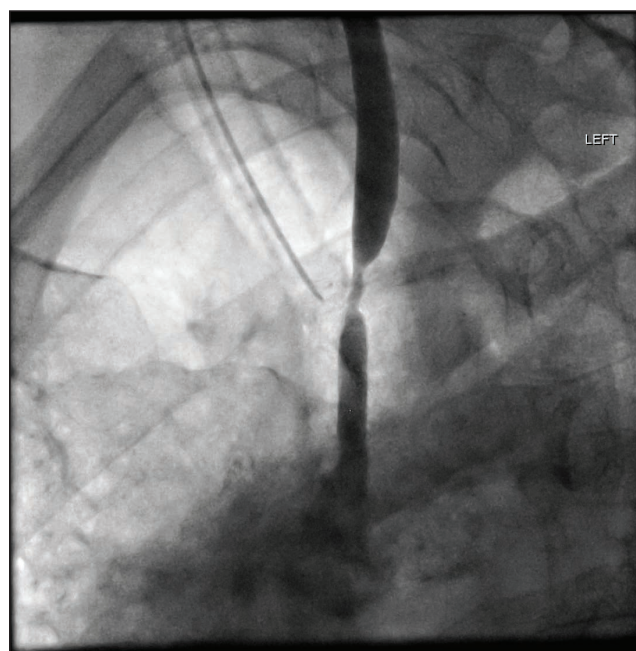


Figure 1. Initial angiogram prior to treatment.

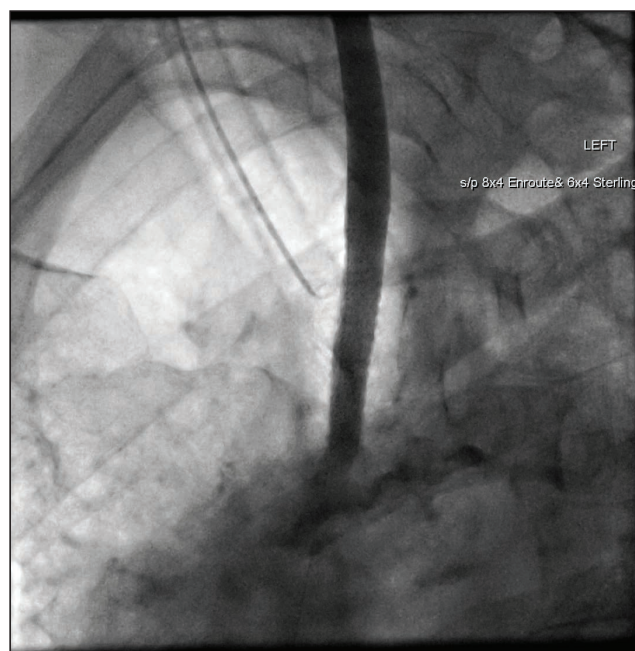


Figure 2. Angiogram immediately after treatment.

retrograde access was performed utilizing flow diversion to the right femoral vein. An 8- X 40-mm ENROUTE® Transcarotid Stent (Silk Road Medical) was placed. The R-TCAR procedure was uncomplicated, with a total flow diversion time of 9 minutes and total procedure time of 68 minutes, which was well tolerated with no neurological events (Figure 2). The patient was discharged to home the following day with no perioperative complications. At 1-year follow-up, he remained asymptomatic and his stent was widely patent with no evidence of stenosis.

DISCUSSION

Symptomatic severe (> 70%) internal carotid artery stenosis is associated with an ipsilateral stroke rate of up to 26% over 2 years following the initial event.¹ Carotid endarterectomy (CEA) is the gold standard for correction of carotid artery stenosis in appropriately selected symptomatic patients, but may be associated with a periprocedural stroke and death rate of up to 5.8%.¹ Patients with cardiac comorbidities may have increased perioperative cardiopulmonary risk with carotid endarterectomy. Corresponding data are not available for proximal carotid and innominate lesions, with most literature being limited to case reports and small case series. In our practice, surgical and endovascular management of these lesions is offered almost exclusively to symptomatic patients.

Transfemoral carotid angioplasty and stenting (CAS) with an embolic protection device (EPD) is currently approved by the Centers for Medicare and Medicaid Services (CMS) only for symptomatic patients, as several well-publicized studies have shown increased risk of perioperative stroke with CAS compared to CEA. One hypothesis for the increased stroke risk is manipulation of the sheath and catheter system in the aortic arch, along with the need to cross the carotid lesion with a wire prior to deployment of the EPD. Over the last few years, antegrade transcarotid artery revascularization (TCAR) has emerged as a promising technique for treatment of high-risk patients with carotid artery disease. TCAR with neuroprotection using the ENROUTE® Transcarotid

Neuroprotection System (Silk Road Medical) for flow reversal to the femoral vein is the only CMS-approved technique for CAS in asymptomatic, high-risk patients. The ROADSTER 1 trial demonstrated an ipsilateral stroke rate with this technique of 1.3%, which compares favorably with historical CEA stroke rates.²

Retrograde carotid stenting has been shown to be safe when combined with CEA in selected cases.³ While transfemoral stenting may be feasible for these proximal lesions, a recent meta-analysis showed a 30-day stroke rate of up to 3%, with only half of the patients in the overall study being symptomatic.⁴ To date, no large prospective trial data validate this concept for stroke prevention in asymptomatic patients.


To our knowledge, this is the first reported case of R-TCAR for a symptomatic proximal lesion. Further study is necessary to determine the safety and efficacy of this technique, and we do not recommend its use for asymptomatic patients whose stroke rate with good medical management is not clearly defined. ■

1. North American Symptomatic Carotid Endarterectomy Trial Collaborators; Barnett HJM, Taylor DW, Haynes RB, et al. Beneficial effect of carotid endarterectomy in symptomatic patients with high-grade carotid stenosis. *N Engl J Med*. 1991;325:445-453.

2. Malas MB, Dakour-Arifi H, Wang GJ, et al. Transcarotid artery revascularization versus transfemoral carotid artery stenting in the Society for Vascular Surgery Vascular Quality Initiative. *J Vasc Surg*. 2019;69:92-103.e2.

3. Bozzay J, Broce M, Mousa AY. Hybrid treatment of extracranial carotid artery disease. *Vasc Endovascular Surg*. 2017;51:373-376.

4. Zhang X, Ma H, Li L, et al. A meta-analysis of transfemoral endovascular treatment of common carotid artery lesions. *World Neurosurg*. 2019;123:89-94.



Peter Rossi, MD, FACS, FSVS

Chief, Division of Vascular and Endovascular Surgery

Associate Professor of Surgery, Radiology and Orthopedic Surgery

Associate Director, Heart and Vascular Service Line

Medical College of Wisconsin
Milwaukee, Wisconsin

prossi@mcw.edu

Disclosures: Proctoring and consulting fees from Silk Road Medical.

Acute Thrombosed Carotid Stent Recanalization

BY INKYONG K. PARRACK, MD, AND RUSSELL H. SAMSON, MD, DFSVS

A 70-year-old man presented with new-onset right handed weakness, and MRI confirmed that he had an acute left temporoparietal infarct. He has a history of untreated bilateral frontal stroke with expressive aphasia and flat affect. Carotid ultrasound showed bilateral 80% to 99% carotid stenosis, and he underwent a left carotid endarterectomy without complication. The patient complained of dysphagia after the carotid endarterectomy, and workup revealed a squamous cell carcinoma of the right supraglottis requiring chemotherapy and radiation. Repeat duplex 6 months after the previous study showed increased right internal carotid artery (ICA) stenosis (peak systolic velocity, 451 cm/sec; end diastolic velocity, 124 cm/sec). Given the high-grade stenosis and recent cervical radiation, transcarotid artery revascularization (TCAR) was recommended.

PROCEDURE

Under general anesthesia, a right supraclavicular transverse incision was made, and the common carotid artery (CCA) was exposed; 100 units/kg intravenous heparin was administered for an activated clotting time > 250 seconds. Left common femoral vein access was achieved, and an 8-F venous sheath was inserted. The CCA was accessed with a micropuncture system, and an angiogram confirmed a high-grade stenosis. An 8-F arterial sheath was inserted over a J-wire. Flow reversal was established with the ENROUTE® Transcarotid Neuroprotection System (Silk Road Medical), and the CCA was occluded with a vessel tie. The lesion was crossed with a 0.014-inch wire without significant difficulty. A 3- X 20-mm Sterling angioplasty balloon (Boston Scientific Corporation) was used to predilate the lesion. A 9- X 40-mm ENROUTE® Transcarotid Stent (Silk Road Medical) was placed across the lesion. The stent was postdilated with a 5- X 40-mm Sterling angioplasty balloon. Angiography showed a patent stent with a patent CCA, external carotid, and distal ICA into the cerebral circulation (Figure 1). The total flow reversal time was 10 minutes. Protamine was administered for full heparin reversal.

The patient was slow to arouse, unable to follow major commands, and not moving the left upper or left lower extremity. Immediate CTA showed acute occlusion of the ICA stent without intracranial bleed. On axial imaging, the stent was noted to be compressed into an ovoid shape (Figure 2). The patient emergently returned to the operating room and the previous incision was reentered. Digital subtraction angiography was suspicious for a stent fracture (Figure 3). A Bentson wire was passed into the external carotid artery and a 6-F sheath was placed in the CCA. Arteriography demonstrated thrombus burden within the stent but cross-filling through the external carotid artery into the distal ICA. Next, antegrade flow was occluded with vessel tie of the CCA. Abciximab (4 mg), tissue plasminogen activator (4 mg),

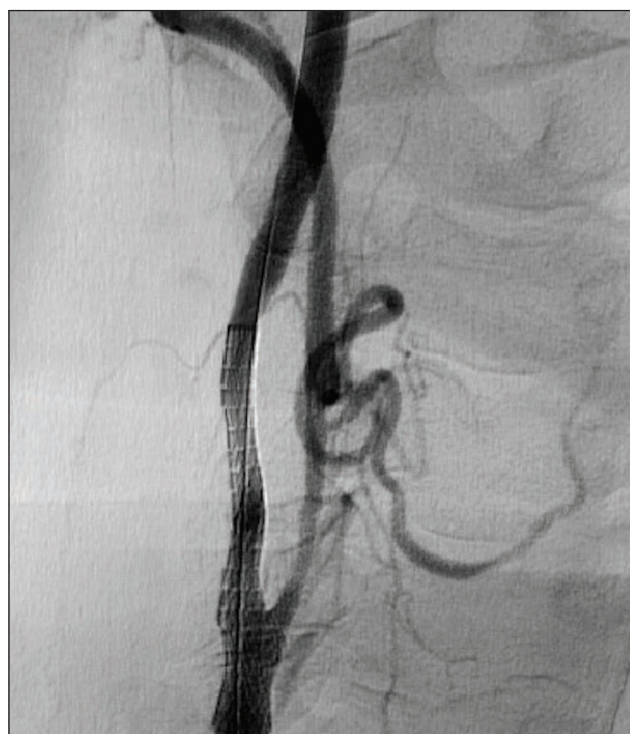

Figure 1. Poststenting angiogram showed a patent stent, CCA, external carotid, and distal ICA into the cerebral circulation.

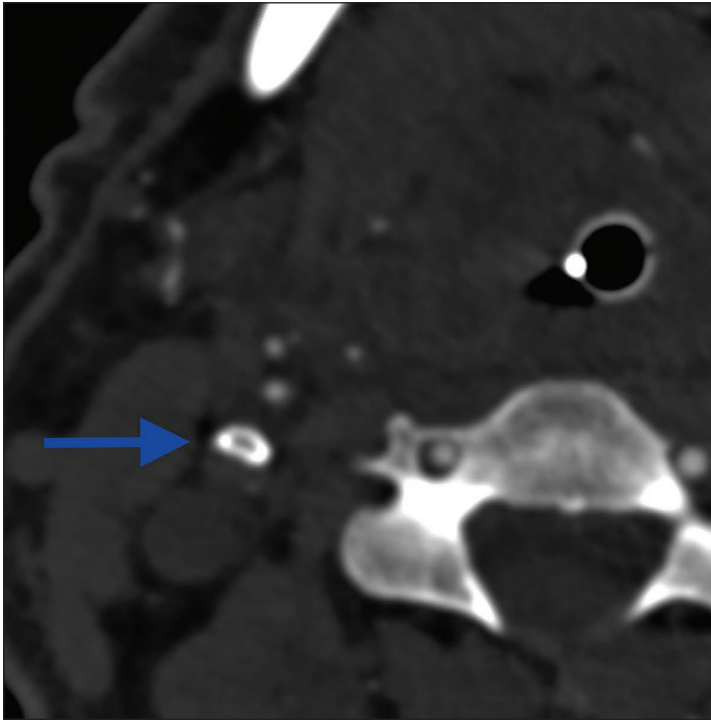


Figure 2. Axial imaging showed the stent compressed into an ovoid shape.

and verapamil (10 mg) were administered slowly through the sheath and allowed to dwell for 5 minutes. Angiography initially demonstrated large air bubbles and a stagnant column of blood in the proximal ICA. This was immediately evacuated via a 20-mL syringe applied to the sheath. Repeat angiography showed a now-patent stent with flow into the distal ICA. Due to the potential stent fracture, the previous stent was relined with a 6- X 40-mm Zilver PTX drug-eluting stent (Cook Medical) and postdilated with a 5- X 40-mm angioplasty balloon. Completion angiogram showed a patent stent and distal ICA without notable kink or defect (Figure 4).

RESULTS

The patient awoke from general anesthesia and could move all extremities and follow commands. Repeat CT scan showed no new infarcts. The patient was back to his baseline by the morning of postoperative day 1. At 6-month follow-up, repeat CTA showed a widely patent stent without kinks or deficits (Figure 5).

DISCUSSION

The etiology of acute stent thrombosis in this case is unknown. There is radiographic evidence as shown for possible stent fracture (Figure 3), incomplete stent apposition (Figure 2), and possible failure to exclude the entire lesion (Figure 1). With thrombolysis and vasodilation, mechanical aspiration, and relining the lesion with an additional stent to extend proximally as well as further aggressive post dilation yielded successful radiographic and clinical outcomes.

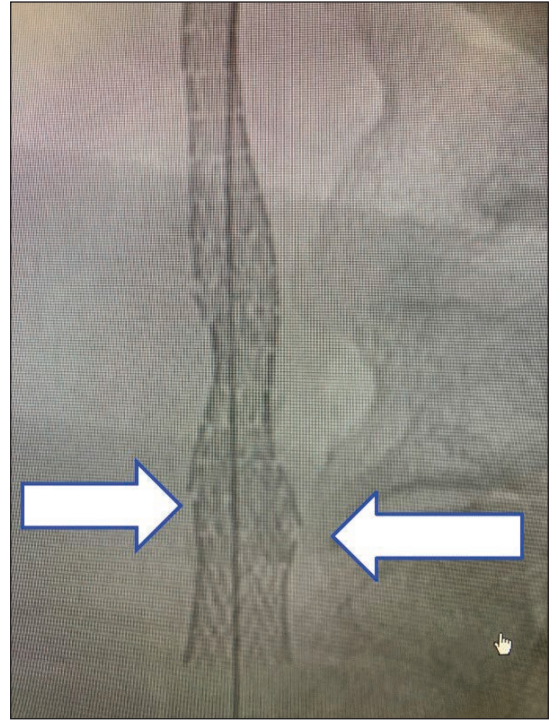


Figure 3. Digital subtraction angiography showed a potential stent fracture.

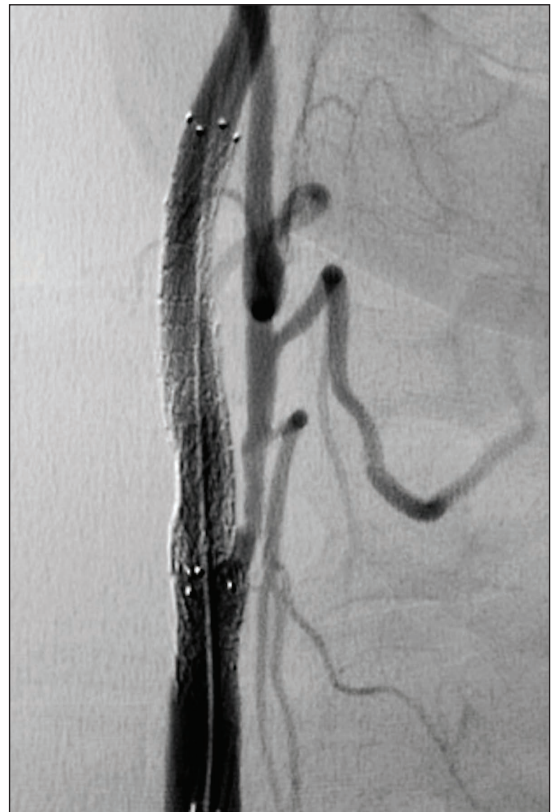

Figure 4. Completion angiogram showed a patent stent and distal ICA without notable kink or defect.

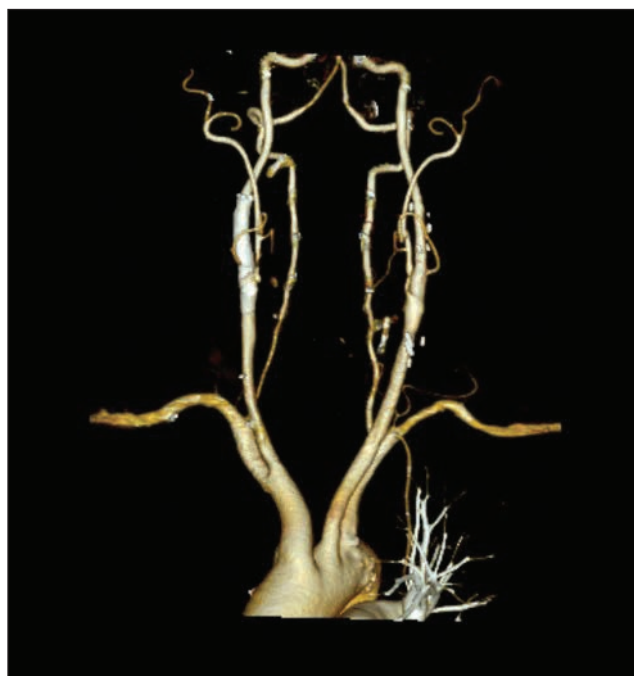

Figure 5. CTA at 6-month follow-up showed a widely patent stent without kinks or deficits.

There have been numerous other TCAR procedures performed since without any complications. This case represents one of the earlier experiences. A major change in protocol after this experience has been aggressive predilation of the lesion prior to stent placement. This step allows for improved stent deployment, apposition, and prevention of any kink or stent fracture. ■



Inkyong K. Parrack, MD

Clinical Assistant Professor of Surgery
Florida State University
Sarasota, Florida
iparrack@veinsandarteries.com

Disclosures: None.



Russell H. Samson, MD, DFSVS

Clinical Professor of Surgery
Florida State University
Sarasota, Florida
rsamson@veinsandarteries.com

Disclosures: None.

The Evidence Base Dictating Practice in Patients With Concomitant Significant Coronary Artery and Carotid Artery Disease

BY SUMAIRA MACDONALD, MD, PhD, MBChB, MRCP, FRCP, FRCR; RICHARD P. CAMBRIA, MD; AND DOUGLAS MASSOP, MD

There is a degree of controversy regarding the optimal management of patients undergoing coronary artery bypass grafting (CABG) who are also found to have concomitant severe carotid artery disease.

The evidence base is less well understood for patients requiring surgical valve repair and carotid revascularization. Therapeutic strategies have previously included CABG alone, staged carotid endarterectomy (CEA) plus CABG, reverse-staged CABG plus CEA, synchronous CEA plus CABG on-pump (cardiopulmonary bypass), synchronous CEA plus off-pump CABG, staged transfemoral carotid artery stenting (TF-CAS) plus CABG, and more recently, staged transcatheter artery revascularization (TCAR) plus CABG.

The management controversy for patients with unilateral asymptomatic carotid disease is highlighted by conflicting reports. An updated systematic review and meta-analysis of stroke after cardiac surgery and its association with asymptomatic carotid disease demonstrated an uncertain evidence base supporting a strategy of prophylactic TCAR/TF-CAS/CEA in cardiac surgery patients with unilateral asymptomatic carotid disease.¹ However, cardiac patients with significant carotid disease were shown to be safely treated with concomitant CABG and CEA in a publication detailing the late results of combined carotid and coronary surgery using actual versus actuarial methodology in a 500-patient cohort.² Two randomized trials in this clinical setting came to different conclusions, thus adding to the management quandary.^{3,4}

There is minimal controversy, however, regarding the benefits of carotid revascularization prior to cardiac surgery in patients with significant bilateral carotid disease (to include unilateral occlusion). The other notable cohort in this clinical setting is the patient with a symptomatic carotid stenosis requiring cardiac surgery; these patients are at significant stroke risk during cardiac surgery without prior carotid revascularization.

PATHO-ETIOLOGIES OF INTRAPROCEDURAL STROKE DURING CABG

The underlying etiologies of the intraprocedural stroke hazard during CABG must be understood before addressing the role of carotid revascularization prior to CABG. These etiologies include aortic cross-clamping; the use of aortic cannulas; and, when on-pump (cardiac bypass), the fact that the normal peak and trough of the systolic and diastolic cardiac waveforms are averaged out to a lower-than-peak mean. Thus, strokes may arise from embolization of aortic atheroma (not avoided by prior carotid revascularization) or cerebral hypoperfusion (possibly avoided), the latter mostly occurring when there are significant bilateral carotid stenoses of hemodynamic relevance (hemodynamic relevance starts at a 75% stenosis of the carotid artery). Against these presumptions is a risk stratification publication from the Buffalo Cardiac-Cerebral Study Group, which revealed that 66% of periprocedural strokes in patients with a > 50% carotid stenosis undergoing carotid surgery occurred in the postoperative rather than intraprocedural setting, implying carotid lesion destabilization in the hypercoagulable milieu after cardiac surgery.⁵

THE REASONABLE APPROACH TO TCAR WITH COMBINED CAROTID AND CARDIAC DISEASE

If within the current limitations of the knowledge base we are faced with an undeniable management challenge, we should consider a safe algorithm for sequential treatment of combined carotid and cardiac disease as described.

A fundamental premise for the safe performance of any vascular procedure is to understand the indications, contraindications, and technique described during the research of the medical device and follow the instructions for use. TCAR was developed as a surgically inspired procedure with control of the treated vessel with proximal occlusion and robust flow reversal while intervening. The

indication for TCAR, targeted carotid lesion, access, and overall anatomy of the carotid bifurcation need to be assessed. Just as important, all cases need to be performed with medical therapy compliance of dual antiplatelet therapy (DAPT) and statin therapy, while still being able to maintain heart rate and blood pressure for the flow reversal. Several of these fundamentals can be challenged when trying to treat a patient with both significant carotid and cardiac disease with multiple procedures. For the purposes of this article, *cardiac* means any acute/subacute CABG or surgical structural valve procedure. The carotid revascularization paradigms prior to percutaneous coronary intervention and transcatheter aortic valve replacement are different and will require further elucidation.

A simple way to look at these combinations is to consider how a patient presents for evaluation. This can evolve in presentation as carotid then coronary, coronary then carotid, or simultaneous symptomatic carotid and coronary. The management then requires a true team effort of the carotid team, cardiac team, and anesthesia services.

The team members all need to understand both the indications and procedural requirements for TCAR before their recommendation is made. The Society for Vascular Surgery (SVS) Vascular Quality Initiative database is now getting quite large with well over 2,000 patients and continued rapid growth. Based on the experience of the operator, access anatomy, and patient preference, TCAR can be performed under local or general anesthesia. Typically, the TCAR procedure time is in the range of just over 1 hour, which compares very favorably to CEA (ROADSTER 1, 74 min⁶ vs CREST, 121 min⁷; $P < .001$). This is likely one of the reasons that the myocardial infarction rate is significantly less for TCAR compared to CEA (0.9% vs 2.3%).⁸ Further, the time required for flow reversal is typically under 10 minutes for most operators and cases. The reversal time is important from the standpoint of need for elevated rate-pressure product and the added associated cardiac risk for that brief period. These facts are all very important in considering the cardiac risk of the TCAR procedure itself.

Carotid Then Coronary Presentation

An asymptomatic > 80% or symptomatic > 50% carotid lesion that is considered for intervention will also have some form of cardiac risk assessment. First, assume that the patient is a good candidate for TCAR from a carotid perspective. Then, a cardiac risk assessment needs to consider whether the patient can safely tolerate the desired rate-pressure product (rate > 70 bpm, BP 140–160 mm Hg systolic) for flow reversal in the TCAR procedure. If the patient is a good candidate from a cardiac perspective, then proceed with TCAR. However, if the patient's cardiac risk is too high for hemodynamics to maintain flow reversal, options

could include TF-CAS under local anesthesia or carotid endarterectomy under either local or general anesthesia, while accepting more stringent control of the hemodynamics (eg, tighter rate and pressure control). Again, this should be decided with the thoughtful input of all services involved.

Coronary Then Carotid Presentation

Most patients who present with cardiac disease requiring treatment are in some way symptomatic, with either myocardial infarction, angina, exercise intolerance, or shortness of breath. The Society of Thoracic Surgeons (STS) now recommends all cardiac cases to have a carotid duplex prior to the cardiac procedure to help assess carotid disease and decrease the risk of stroke. As a result, carotid surgeons are called more often to provide input for the care algorithm. In most symptomatic cardiac cases, the cardiac disease should be treated first. The question is whether this should be done with coronary stenting under DAPT, CABG with just aspirin, or structural heart intervention (either an open or endovascular procedure) with associated anticoagulation indications. Most cardiac surgeons are reluctant to perform CABG or valve surgery under DAPT. If the team and patient elect to treat a severe carotid lesion first with either TCAR or TF-CAS, the patient should go through at least 30 days of DAPT before stopping the clopidogrel. This period allows stabilization and partial reendothelialization of the stented site, which is necessary for the patient to safely go on a heart-lung machine with low-pressure flow for the cardiac surgery. The team should not try to cut the DAPT interval shorter before surgery.

SIMULTANEOUS PRESENTATION OF SYMPTOMATIC CAROTID AND CORONARY DISEASE

This scenario is rare in clinical practice. Again, input from the cardiac team will help guide decision making. If both vascular beds are truly acutely symptomatic, then these cases should often be managed with combined carotid endarterectomy and coronary/cardiac surgery, as the likely early cessation of DAPT after TCAR and before urgent cardiac surgery will render the patient at increased risk of stroke arising from platelet aggregation on the carotid stent and/or acute stent occlusion. CEA does not require DAPT (most importantly, the P2Y₁₂ inhibitor component—clopidogrel [Plavix, Bristol-Myers Squibb Company and Sanofi]). However, decision-making will depend on both the severity of the lesions and symptoms caused by these lesions in both of these anatomic areas.

TCAR AND CARDIAC SURGERY; TO REITERATE

Given the stringent requirements for the DAPT necessary for TCAR (and TF-CAS), synchronous rather than staged

TF-CAS/CABG and TCAR/CABG are fraught with risk and require pharmacological gymnastics; this practice cannot be supported. Many (but not all) cardiac surgeons will not perform CABG in patients on aspirin plus a P2Y12 inhibitor such as clopidogrel (Plavix) because of the excess bleeding risk. DAPT in advance of ENROUTE® Transcarotid Stent (Silk Road Medical) placement prior to TCAR and for 1 month following is strongly recommended, if not mandatory. These recommendations are listed in the SVS guidelines for the management of extracranial carotid disease under the section related to carotid stenting.⁹ Omitting the DAPT regimen in the setting of TCAR is contrary to the FDA-approved labelling pertaining to implantation of the ENROUTE® Stent (and in fact, any FDA approved carotid stent).¹⁰ Discontinuation of clopidogrel after TCAR prior to 30 days in order to perform an urgent CABG would be against SVS guidelines for TF-CAS/TCAR and would constitute off-label use for the ENROUTE® Stent. The performance of CABG and TCAR in the same operating room time frame (which has once been reported) requires that the CABG is performed first, without the required DAPT regimen, followed immediately by TCAR, wherein the patient is subsequently administered loading doses of clopidogrel (Plavix) or other P2Y12 inhibitor in recovery. This is an extremely high-risk strategy regarding the fate of the newly implanted carotid stent and defies both the SVS carotid stent guidelines for the pharmacologic regimen and the FDA labelling of the carotid stent. Clopidogrel (Plavix) is a pro-drug that requires hepatic enzyme metabolism into its active metabolite. This explains resistance through genetic polymorphisms, but also highlights that even loading doses require sufficient processing time until the full antiplatelet effect is achieved, meaning that post-loading is ineffective and fraught with unnecessary risk.


Staged TCAR and cardiac surgery, preferably 30 days apart, is very achievable.

SUMMARY

The primary consideration can be summarized as “the separation of procedural risk” of the cardiac and carotid procedures. The requirement for synchronous coronary/valve and carotid procedures for urgent symptoms from both territories is relatively rare. The options for treatment of the carotid bifurcation have been safely expanded with the TCAR procedure, but TCAR cannot be recommended in those rare circumstances wherein both urgent carotid and coronary revascularization is required on account of the requirements for DAPT. When performed following the accepted instructions for use, excellent results have been achieved. The scenarios described in this article are a reasonable algorithm for consideration. Essential to success are an approved indication for the procedure, medication

compliance (DAPT and statin therapy preoperatively and for 30 days postoperatively), adequate anatomy (both cervical and cerebral), ability to reach the hemodynamics recommended for flow reversal (heart rate > 70 bpm and BP 140–160 mm Hg), and continuous hemodynamic monitoring postop (BP > 110 mm Hg). These factors must be considered reasonably attainable prior to consenting for TCAR in the patient who also has cardiac disease. ■

1. Naylor AR, Brown MJ. Stroke after cardiac surgery and its association with asymptomatic carotid disease: an updated systematic review and meta-analysis. *Eur J Vasc Endovasc Surg.* 2011;41:607–624.
2. Akins CW, Hilgenberg AD, Vlahakes GJ, et al. Late results of combined carotid and coronary surgery using actual versus actuarial methodology. *Ann Thorac Surg.* 2005;80:2091–2097.
3. Illuminati G, Ricco JB, Calio F, et al. Short-term results of a randomized trial examining timing of carotid endarterectomy in patients with severe asymptomatic unilateral carotid stenosis undergoing coronary artery bypass grafting. *J Vasc Surg.* 2011;54:993–999.
4. Weimar C, Bilbilis K, Rekowski J, et al; CABACS Trial Investigators. Safety of simultaneous coronary artery bypass grafting and carotid endarterectomy versus isolated coronary artery bypass grafting a randomized clinical trial. *Stroke.* 2017;48:2769–2775.
5. Ricotta JJ, Faggioli GL, Castilone A, Hassett JM. Risk factors for stroke after cardiac surgery: Buffalo cardiac-cerebral study group. *J Vasc Surg.* 1995;21:359–363.
6. Kwolek C, Jaff MR, Leal JJ, et al. Results of the ROADSTER multicenter trial of transcarotid stenting with dynamic flow reversal. *J Vasc Surg.* 2015;62:1227–1234.
7. Brott TG, Hobson RW 2nd, Howard G, et al; CREST Investigators. Stenting versus endarterectomy for treatment of carotid-artery stenosis. *N Engl J Med.* 2010;363:11–23.
8. Kashyap VS, Schneider P. ROADSTER 2 Post Approval Study final results. Presented at: 2019 VAM Annual Meeting, June 2019.
9. Ricotta JJ, Aburahma A, Ascher E, et al. Updated Society for Vascular Surgery guidelines for management of extracranial carotid disease. *J Vasc Surg.* 2011;54:e1–e31.
10. ENROUTE® Transcarotid Stent System [Instructions for use number 11752 Rev2]. Sunnyvale, CA: Silk Road Medical; 2018.



Sumaira Macdonald, MD, PhD, MBChB, MRCP, FRCP, FRCR

Vascular Interventional Radiologist
Executive Medical Director
Silk Road Medical
Sunnyvale, California



Richard P. Cambria, MD

Robert R. Linton MD Professor of Vascular and Endovascular Surgery (Emeritus)
Harvard Medical School
Chief of Vascular and Endovascular Surgery
St. Elizabeth's Medical Center
System Chief for Vascular Services
Steward Health Care
Boston, Massachusetts
Disclosures: Consultant for and stock options in Silk Road Medical.



Douglas Massop, MD

Vascular Surgeon
The Iowa Clinic
Des Moines, Iowa
dmassop@iowaclinic.com
Disclosures: Consultant and proctor for Silk Road Medical.

Vascular Quality Initiative: Transcarotid Stenting Project Update

BY MARC SCHERMERHORN, MD, AND PATRIC LIANG, MD

Since the introduction of transcarotid artery revascularization (TCAR), we have seen nationwide adoption of this technique. Starting in October 2018, over 50% of all carotid stenting procedures performed in the Vascular Quality Initiative TCAR Surveillance Project (VQI-TSP) are now via TCAR instead of the transfemoral carotid artery stenting (TF-CAS) approach (Figure 1). With over 5,250 TCAR procedures registered in the VQI-TSP, we recently evaluated the outcomes following TCAR compared to TF-CAS and carotid endarterectomy (CEA).

Propensity-matched analysis of patients undergoing TCAR and patients undergoing TF-CAS resulted in 3,286 matched pairs of patients, with outcomes favoring TCAR (Table 1). We found that TCAR was associated with lower rates of in-hospital stroke or death (1.6% vs 3.1%; $P < .001$) as well as the individual rates of stroke (1.3% vs 2.4%; $P = .001$) and death (0.4% vs 1%; $P = .008$). There were no differences in in-hospital myocardial infarction between the two procedures (0.2% vs 0.3%; $P = .47$). TCAR procedures were also associated with less radiation (total fluoroscopy time, 6.1 vs 19 min; $P < .001$) and contrast use (37 mL vs 94 mL; $P < .001$). The benefits from TCAR extended out to 1 year on Kaplan-Meier analysis, with a higher rate of stroke-/death-free survival with TCAR compared to TF-CAS (94.9% vs 90.5%; $P < .001$).

Compared to TF-CAS, TCAR was associated with higher rates of bleeding complications that resulted in reintervention or thrombin injection (1.3% vs 0.8%; $P = .041$). However, not all patients received protamine following TCAR procedures. In a separate propensity matched analysis comparing patients undergoing TCAR with and without protamine use in the VQI-TSP, we found that protamine use was associated with significantly lower rates of bleeding complications (1% vs 3.6%; $P < .001$), without an increase in stroke or myocardial infarction. In fact, protamine use was associated with a trend toward lower rates of stroke (1.1 vs 2%; $P = .09$).

The hesitancy in using protamine following carotid revascularization stems from early studies showing an

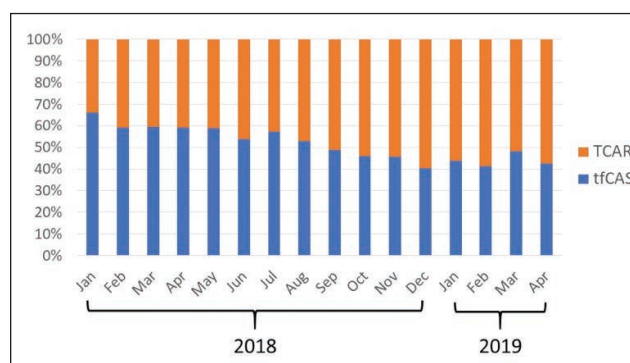


Figure 1. Proportion of carotid stents placed via the transcarotid (TCAR) and transfemoral (tfCAS) approach.

increased risk of carotid thrombosis after protamine use. However, larger studies, including one utilizing data from the Vascular Study Group of Northern New England, a subsidiary of the VQI, found no significant difference in perioperative stroke with and without protamine use in CEA (0.8% vs 1.2%; $P = .2$).¹ These unsubstantiated concerns for protamine use in CEA have undoubtedly permeated into carotid stenting, as the trial investigators for CREST strongly discouraged the use of protamine in carotid stenting. Because perioperative bleeding following carotid revascularization has a known association with increased stroke risk, and we found that protamine use

TABLE 1. VQI-TSP PROPENSITY-MATCHED IN-HOSPITAL OUTCOMES OF PATIENTS UNDERGOING TCAR AND TF-CAS FROM SEPTEMBER 2016 TO APRIL 2019

Endpoint	TCAR	TF-CAS	P Value
Stroke/death	1.6%	3.1%	< .001
Stroke	1.3%	2.4%	.001
Death	0.4%	1%	.008
Myocardial infarction	0.2%	0.3%	.47
Fluoroscopy time	6.1 min	19 min	< .001
Contrast volume	37 mL	94 mL	< .001

is associated with lower bleeding complication in TCAR without an increase in thrombotic events, we recommend that all patients undergoing TCAR receive protamine.

The gold standard method for carotid revascularization is CEA. Using data from the VQI, we compared outcomes between patients undergoing TCAR to CEA. On unadjusted analysis, patients undergoing TCAR had higher rates of death (0.5% vs 0.3%; $P = .03$) and similar rates of stroke (1.4 vs 1.2; $P = .37$). However, because carotid stenting—including TCAR—is reserved for high-surgical-risk patients, TCAR patients were older and had more medical comorbidities. A propensity-matched analysis was performed to account for these baseline differences for patients undergoing TCAR and CEA, and 5,160 pairs of patients were identified. Following matching, we found that TCAR was actually associated with a trend in lower odds of in-hospital stroke or death (odds ratio [OR], 0.77; 95% confidence interval [CI], 0.57–1.04; $P = .09$). However, TCAR was associated with lower odds of both myocardial infarction (OR, 0.41; 95% CI, 0.26–0.66; $P < .001$) and cranial nerve injury (OR, 0.13; 95% CI, 0.07–0.22; $P < .001$).

This updated analysis of the VQI-TSP continues to support the use of TCAR over TF-CAS given its improved safety profile with lower rates of stroke and death. Furthermore, TCAR has continued to show its equivalence to CEA. TCAR is currently restricted to high surgical risk patients. However, given the overall low stroke and death rates following TCAR (despite the majority of VQI-TSP cases [81%] have been within the

surgeon's first 20 performed TCAR procedures), it is possible that TCAR will soon be expanded to patients at normal risk. If TCAR becomes approved to standard-risk patients, the VQI-TSP will again be integral in monitoring the safety of TCAR compared to CEA in this new patient subset. ■

1. Stone DH, Nolan BW, Schanzer A, et al. Protamine reduces bleeding complications associated with carotid endarterectomy without increasing the risk of stroke. *J Vasc Surg.* 2010;51:559-564, 564.e1.



Marc Schermerhorn, MD

George H.A. Clowes Jr. Professor of Surgery
Harvard Medical School
Chief, Vascular and Endovascular Surgery
Department
Beth Israel Deaconess Medical Center
Boston, Massachusetts
*Disclosures: Consultant for Silk Road Medical,
Abbott Vascular, Cook Medical, Endologix,
and Medtronic.*



Patric Liang, MD

Vascular Surgery Resident
Beth Israel Deaconess Medical Center
Fellow
T32 Harvard-Longwood Vascular Surgery
Research Training Program
Boston, Massachusetts
Disclosures: None.

TCAR Pearls and Pitfalls

BY MICHAEL C. STONER, MD, RVT, FACS, AND JEFFREY JIM, MD, MPHS, FACS

Transcarotid artery revascularization (TCAR) represents a novel, minimal-access technique indicated for revascularization of the internal carotid artery (ICA) in patients with clinically or hemodynamically significant lesions. TCAR maintains the benefit of a minimally invasive procedure while mitigating much of the procedural embolization risk of traditional transfemoral-based stenting. The results of this procedure have been exceptional in both clinical trials and real-world registry studies.^{1,2} With over 12,000 cases completed to date, a robust evolving training program, and a culture of continuous improvement, the procedure continues to be optimized and improved. The following learning points were recognized to aid novice users as well as experienced practitioners to achieve the excellent results seen in TCAR.

► Realize the Short, but Real, Learning Curve

TCAR leverages current skills of most endovascular surgeons (eg, carotid exposure, angioplasty with 0.014-inch platforms, and stenting). TCAR procedure times have consistently been shown to be almost 40 minutes less than standard carotid endarterectomy. However, this is still a new procedure for novel users. Meticulous procedural techniques are required to realize the efficiency and achieve the safety of TCAR.

► Take Time for Preoperative Case Planning

Attention to the common carotid access site, lesion characteristics, distal ICA anatomy, and intracranial atherosclerotic burden is paramount to the success of this procedure. Careful adherence to adequate anatomic requirements is necessary to ensure safe arterial sheath placement without engaging the lesion. Heavily calcified lesions should be avoided because of the known long-term adverse outcomes (eg, recurrence, thrombosis) with stent placements in these types of lesions.

► Medical Therapy Is the Cornerstone of Safety

Violation of the drug regimen is one of the most common causes of the rare adverse events seen in TCAR. Angioplasty and stenting disrupts the intimal-medial interface, exposing blood flow to a thrombogenic surface. All patients should be on dual antiplatelet

therapy to prevent platelet aggregation. Statin therapy has also been shown to have plaque-stabilizing properties. The beneficial use of these agents has been well-described in the literature and is considered as standard of care.

► Meticulous Angiographic Technique

Use a low-and-slow technique to avoid high-pressure injection next to the carotid lesion. Syringes for injection should be loaded at the beginning of the case to allow the bubbles of air to leave the solution. Keep in mind that angiography requires antegrade flow, and this is a potential source of distal embolization. Avoid unnecessary imaging, especially after the lesion has been treated.

► Minimize Postdilation

The authors advocate for a more generous predilation strategy, approaching a nominal internal carotid artery diameter. This allows for better stent apposition and reduces this risk of prolapsing atheromatous material through the stent during postdilation. Furthermore, disruption of the plaque earlier during the flow reversal duration may be more protective for the patients.

► Always Use Protamine

The intra-arterial manipulation during TCAR mandates a therapeutically heparinized patient. However, as previously mentioned, the procedure time is quite short and the patient is likely to be fully anticoagulated during incision closure. Cervical hematoma is a risk that can be mitigated by both careful dissection and heparin reversal. Furthermore, the use of protamine has been shown to eliminate the risk of bleeding complications, but it was not associated with increased stroke risk or other complications.³

► Diligent Intraoperative and Postoperative Blood Pressure Management

The protective nature of TCAR is generating retrograde flow in the internal carotid artery during treatment. Flow reversal and ipsilateral cerebral blood flow are both predicated on maintaining adequate arterial pressure and relative hypertension during the procedure. Proactive use

of anti-bradycardia agents should be applied, and clear communication with the anesthesia team regarding flow reversal parameters is critical. Postoperatively, hyper- and hypotension are to be avoided to prevent hyperperfusion syndromes or stent thrombosis.

CONCLUSION

TCAR is an excellent procedure that has low periprocedural stroke rates in high-risk patients. However, it should be remembered that this is a relatively new procedure in which we continue to gain insights from expanding experience. In order to maintain excellent results, practitioners should keep themselves updated on the evolving best practices to ensure the best clinical outcomes for their patients. ■

1. Kwolek CJ, Jaff MR, Leal JJ, et al. Results of the ROADSTER multicenter trial of transcarotid stenting with dynamic flow reversal. *J Vasc Surg.* 2015;62:1227-1234.
2. Malas MB, Dakour-Aridi H, Wang GJ, et al. Transcarotid artery revascularization versus transfemoral carotid artery stenting in the Society for Vascular Surgery Vascular Quality Initiative. *J Vasc Surg.* 2019;69:92-103.e2.
3. Schermerhorn M. Transcarotid artery revascularization. Presented at: the Society of Vascular Surgery Vascular Annual Meeting; June 2019.



Michael C. Stoner, MD, RVT, FACS

Chief, Division of Vascular Surgery
University of Rochester Medical Center
Rochester, New York
michael_stoner@urmc.rochester.edu

Disclosures: Case proctor and educational consultant for Silk Road Medical.



Jeffrey Jim, MD, MPH, FACS

Associate Professor, Section of Vascular Surgery
Program Director, Vascular Surgery Fellowship/Residency
Washington University School of Medicine
St. Louis, Missouri
jimj@wustl.edu

Disclosures: Co-Director National TEST Drive Program, education consultant, and case proctor for Silk Road Medical.

Identifying Clopidogrel Resistance in the Setting of TCAR

BY EDGAR D. GUZMAN, MD, FACS, RPVI, AND JESSICA TITUS, MD

Dual antiplatelet therapy (DAPT) in addition to statins has become the cornerstone medical treatment of cerebrovascular disease requiring carotid stenting. The combination of aspirin and a thienopyridine following coronary intervention became widespread in the late 1990s after studies showed it to be superior to aspirin plus anticoagulation in reducing stent thrombosis and bleeding risk. Shortly thereafter, studies were performed evaluating this combination therapy in cerebrovascular intervention demonstrating similar findings. Current guidelines from most major societies recommend the use of DAPT both pre- and postoperatively in carotid artery stenting.

The most common antiplatelet medication used today in addition to aspirin is clopidogrel. A second-generation thienopyridine, clopidogrel is a prodrug that undergoes two-step hepatic metabolism involving the cytochrome P450 (CYP) system. Thus, the onset of action of clopidogrel is relatively slow because it requires conversion to its active metabolite. Medications or disease processes that interfere with the CYP system can lead to clopidogrel resistance or diminished antiplatelet effect. In addition, gene polymorphisms can cause a patient to be a slow metabolizer or nonresponder. These two mechanisms leading to clopidogrel resistance expose patients to the risks associated with aspirin monotherapy. Beyond this, patient noncompliance, reduced bioavailability, increased platelet turnover, competitive inhibition by less potent antagonists, and other factors may impede the desired effect of both aspirin and clopidogrel.^{1,2} Failure to achieve sufficient levels of platelet inhibition with either drug have been correlated with undesirable cardiovascular outcomes.^{3,4}

Clopidogrel resistance is not an uncommon phenomena. Literature suggests that this is an issue in 15% to 48% of the population.⁵⁻⁷ Identifying these patients is important, as other steps can be taken in their treatment algorithm to provide them the protection of DAPT. The gold standard of testing is light transmission aggregometry, however this is time-consuming and

cumbersome. Several commercial point-of-care tests are now available that are quicker and easier to apply clinically.

PREOPERATIVE THROMBOELASTOGRAPHY

Thromboelastography (TEG) is a whole blood assay that tracks the formation and destruction of thrombus over time as measured by variations in clot strength. It provides information regarding coagulation, platelet aggregation, and fibrinolysis. TEG has become increasingly available as it is useful to guide blood product therapy in the settings of trauma and cardiac surgery.⁸ Results are delivered as easily recognizable traces and numerical values that describe clot kinetics. The maximum amplitude (MA) of the trace in millimeters quantifies peak clot strength and is representative of platelet function.

TEG has been further developed to test for platelet inhibition through the addition of adenosine diphosphate (ADP) or arachidonic acid (AA) to the samples. This allows discrimination of the contribution of the P2Y₁₂ and cyclooxygenase pathways to clot formation. Results are expressed as the MA-ADP and MA-AA, or more intuitively, as the percentage of inhibition of ADP- or AA-mediated pathways. More than 30% ADP inhibition and > 50% AA inhibition are considered therapeutic.⁹ Later publications suggest that an MA-ADP under 47 mm correlates best with the avoidance of ischemic events following coronary stenting.¹⁰

In one early case experience, a patient undergoing transcarotid artery revascularization (TCAR) sustained an ipsilateral stroke 12 hours after surgery. Preoperative compliance with DAPT had been confirmed and imaging excluded a technical issue. The event was initially attributed to plaque extrusion through the stent, but was later considered to be due to clopidogrel resistance. TEG with platelet mapping showed a subtherapeutic MA-ADP of 49 mm and borderline AA inhibition of 49%. The next day, after a loading dose of an alternative P2Y₁₂ inhibitor and an increase in the aspirin dose from 81 mg to 325 mg, his MA-ADP was 45 mm, and AA inhibition

was 91%. The patient avoided further neurologic events and had a good recovery. A subsequent decision to test platelet function on every patient the morning of their TCAR led to changes in management of 20% to 30% of cases at Hattiesburg Clinic Vascular Specialists, which is in line with literature reports.¹¹ A consistent correlation has been seen at our institution between medication manipulations and changes in TEG parameters, and it has been recognized that 81 mg of aspirin is not universally effective.

A man undergoing staged bilateral TCAR was shown to have clopidogrel resistance. Given his recent history of stroke, he was loaded with ticagrelor. His MA-ADP fell below 47 mm, and he underwent an uneventful first operation that same day. A few weeks later, he returned on a Tuesday for his contralateral stent and answered positively to taking aspirin and ticagrelor that morning. Surprisingly, his MA-ADP was once again subtherapeutic. Upon further questioning, he admitted to missing his weekend doses of ticagrelor and resumed medication the day prior to surgery. He received a loading dose, his MA-ADP responded adequately, and his second TCAR was uneventful as well.

VERIFYNOW

The VerifyNow system (Accriva Diagnostics) involves measurement of P2Y12 reaction units (PRU). The desired level of PRU is < 180, and partial response is considered from 180 to 208. A PRU > 208 is considered a nonresponder. At Abbott Northwestern, partial responders are treated with a doubled clopidogrel dose of 150 mg daily. Nonresponders and those who don't respond to the increased dosage are switched to an alternative antiplatelet. Every effort is made to obtain this lab after a week of treatment; however, symptomatic patients don't always afford the luxury of time. In these patients, a baseline PRU is obtained to assist in interpreting the response after therapy is initiated. If there is no significant reduction in PRU, the patient is switched to an alternative antiplatelet (Table 1).

Utilizing this protocol, 20.4% of patients at Abbott Northwestern required a change in therapy. Nine percent of patients were found to be partial responders

Clopidogrel Response in TCAR Patients at Single Institution

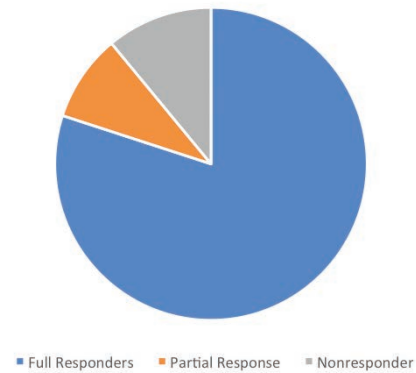


Figure 1. Of the tested patients undergoing TCAR at Abbott Northwestern, 9% were partial responders and 11% were nonresponders who required a change in antiplatelet medication.

who responded to an increased dose of clopidogrel. An additional 11% were nonresponders who required a switch to an alternative antiplatelet medication (Figure 1). There were no bleeding or embolic complications noted that could be attributed to the DAPT regimen.

MEDICATION ALTERNATIVES

Because both mechanisms of clopidogrel resistance result in decreased bioavailability, some patients may simply require a higher dose of clopidogrel to obtain the desired response. Those who are complete nonresponders or who do not reach the desired inhibition with increased dosing may require a switch to an alternative antiplatelet medication.

Prasugrel, a third-generation thienopyridine, is a common alternative. It is also a prodrug; however, it only requires single-stage activation, making it less prone to genetic polymorphisms and CYP alterations. When compared to clopidogrel, prasugrel showed decreased risk of stent thrombosis, myocardial infarction, or cardiovascular death but had an increased risk of major bleeding and life-threatening bleeds.¹² In addition, this medication tends to be more costly for patients.

TABLE 1. TARGETED THERAPEUTIC PLATELET INHIBITION VALUES

	Thromboelastogram	VerifyNow
Aspirin	> 50% AA inhibition	350 to 550 ARU
P2Y12 inhibitors	MA-ADP, < 47 mm	10 to 180 PRU
Abbreviations: AA, arachidonic acid; ARU, aspirin reaction units; MA-ADP, maximum amplitude adenosine diphosphate; PRU, P2Y12 reaction units.		

Ticagrelor is another alternative. Similar to thienopyridines, it binds to P2Y12 to antagonize the ADP receptor on platelets. However, unlike clopidogrel, this binding is reversible and does not require hepatic enzymatic activation, potentially providing less drug interaction and more reliable inhibition.

CONCLUSION

Clopidogrel resistance is not uncommon, and missing the identification of these patients potentially deprives them of the known benefits of DAPT. Although demonstration of suboptimal platelet inhibition through various assays has been repeatedly associated with undesirable outcomes, wider application of these technologies has failed to yield improved results. Whether this represents a failure of the concept or simply a need for further technical refinement remains to be determined. In the meantime, preoperative platelet testing is in keeping with best efforts to ensure an indispensable element of carotid intervention is delivered. The implementation of clopidogrel response testing and medication protocol is recommended to help achieve the best outcomes in TCAR. ■

1. Ferguson AD, Dokainish H, Lakkis N. Aspirin and clopidogrel response variability: review of the published literature. *Tex Heart Inst J*. 2008;35:313-320.
2. Michos ED, Ardehali R, Blumenthal RS, et al. Aspirin and clopidogrel resistance. *Mayo Clin Proc*. 2006;81:519-526.
3. Krasopoulos G, Brister SJ, Beattie WS, Buchanan MR. Aspirin "resistance" and risk of cardiovascular morbidity: a systematic review and meta-analysis. *BMJ*. 2008;336:195-198.

4. Snoep JD, Hovens MM, Eikenboom JC, et al. Clopidogrel nonresponsiveness in patients undergoing percutaneous coronary intervention with stenting: a systematic review and meta-analysis. *Am Heart J*. 2007;154:221-231.
5. Yusuf S, Zhao F, Mehta SR, et al. Effects of clopidogrel in addition to aspirin in patients with acute coronary syndromes without ST-segment elevation. *N Engl J Med*. 2001;345:494-502.
6. Matetzky S, Shenkman B, Guetta V, et al. Clopidogrel resistance is associated with increased risk of recurrent atherothrombotic events in patients with acute myocardial infarction. *Circulation*. 2004;109:3171-3175.
7. Gurbel PA, Bliden KP, HiattBL, et al. Clopidogrel for coronary stenting: response variability, drug resistance, and the effect of pretreatment platelet reactivity. *Circulation*. 2003;107:2908-2913.
8. Thakur M, Ahmed AB. A review of thromboelastography. *Int J Periop Ultrasound Appl Technol*. 2012;1:25-29.
9. Bliden KP, DiChiara J, Tantry US, et al. Increased risk in patients with high platelet aggregation receiving chronic clopidogrel therapy undergoing percutaneous coronary intervention. *J Am Coll Cardiol*. 2007;49:657-666.
10. Gurbel PA, Bliden KP, Navickas IA, et al. Adenosine diphosphate-induced platelet-fibrin dot strength: a new thromboelastographic indicator of long-term post-stenting ischemic events. *Am Heart J*. 2010;160:346-354.
11. McTaggart RA, Choudhri OA, Marcellus ML, et al. Use of thromboelastography to tailor dual-antiplatelet therapy in patients undergoing treatment of intracranial aneurysms with the Pipeline embolization device. *J NeuroIntervent Surg*. 2015;7:425-430.
12. Wiviott SD, Braunwald E, McCabe CH, et al. Prasugrel versus clopidogrel in patients with acute coronary syndromes. *N Engl J Med*. 2007;357:2001-2015.



Edgar D. Guzman, MD, FACS, RPVI

Vascular Surgeon
Vascular Insititue of Michigan
Flint, Michigan

Disclosures: Honoraria from Silk Road Medical.



Jessica Titus, MD

Vascular and Endovascular Surgeon
Center of Vascular and Endovascular Surgery
Minneapolis Heart Institute
Abbott Northwestern Hospital
Allina Health

Minneapolis, Minnesota

Disclosures: None.

TCAR TEST Drive

BY WESLEY S. MOORE, MD, AND MICHAEL C. STONER, MD, RVT, FACS

Direct carotid stent/angioplasty with flow reversal (or transcarotid artery revascularization [TCAR]) is a new approach to carotid stenting. The potential for reducing risk of periprocedural complications associated with transfemoral carotid artery stenting was documented in the PROOF trial performed in Dusseldorf, Germany.¹ This approach was brought to the United States in the form of an FDA investigational device exemption trial (ROADSTER). Following the successful outcome of the ROADSTER trial, the technology received FDA approval.² Silk Road Medical, manufacturer of the ENROUTE® Transcarotid Neuroprotection System components for TCAR, considered it crucial for new users of the approach to receive adequate training prior to beginning clinical practice, and implemented the TEST DRIVE training program. This is now available for practicing surgeons as well as for individuals completing their vascular surgery training.

The TEST DRIVE training course, carried out in a facility near Chicago O'Hare airport, provides both didactic and "wet model" training. The course includes didactic lectures from respected surgeons who have had extensive experience with the procedure. Participants are encouraged to bring case material, including appropriate imaging for presentation, discussion, and case planning. Finally, training stations are set up to include instructions regarding the use of the ENROUTE® Transcarotid Stent delivery system (Silk Road Medical) and deployment of the stent. Angioscopy is included in the training, giving trainees the opportunity to visualize insertion of the micropuncture needle, guidewire passage, and insertion of the Uber-Flex™ arterial sheath (Silk Road Medical).

The company also has developed wet models that include a cutdown to expose a realistic carotid artery and jugular vein. The model has active fluid circulation to provide a realistic simulation of all procedural steps from needle puncture, guidewire placement, flow reversal with carotid clamping, and extracorporeal side arm connection to the femoral vein. Guidewire access to the lesion under fluoroscopic control and stent deployment completes the hands-on part of the program.

The TEST DRIVE program has been conducted 40 times to date, has been replicated off-site as a regional program, and trained over 1,000 practicing surgeons. Based on the success of the program and a need to meet an expanding clinical demand, a specific version of the program was developed in 2018 for vascular surgery residents and fellows. Leveraging the curriculum of the standard TEST DRIVE, specific modules

were developed to meet trainees' needs as they first enter practice. These modules included expanded information and tips on how to navigate value analysis committees, supply chain management, reimbursement, and how to utilize new technologies and industry partnerships in practice development. Fifty trainees completed the program last year, and an anticipated 80 more will matriculate through the program in 2019.

The success of this program is attested by the fact that 75% of participants in the ROADSTER 2 program were new operators. Having completed the TEST DRIVE program and subsequent proctoring of their initial three cases, these participants were able to provide results that were comparable to those seen in ROADSTER 1. Considering the ROADSTER trials were carried out in patients who were believed to be high surgical risk from either a medical or technical standpoint, the results were comparable to the best results of carotid endarterectomy in average-risk patients, as documented in clinical trials. Because the results of TCAR are far superior to results reported with the transfemoral approach to carotid stenting,³ TEST DRIVE training provides an excellent opportunity and service to the vascular community and their patients. ■

1. Alpaslan A, Wintermark M, Pinter L, et al. Transcarotid artery revascularization with flow reversal. *J Endovasc Ther*. 2017;24:265-270.

2. Kwolek CJ, Jaff MR, Leal JL, et al. Results of the ROADSTER multicenter trial of transcarotid stenting with dynamic flow reversal. *J Vasc Surg*. 2015;62:1227-1234.

3. Schermerhorn ML, Liang P, Dakour-Aridi H, et al. In-hospital outcomes of transcarotid artery revascularization and carotid endarterectomy in the Society for Vascular Surgery Vascular Quality Initiative [published online June 18, 2019]. *J Vasc Surg*.



Wesley S. Moore, MD

Professor and Chief, Emeritus
Division of Vascular and Endovascular
Surgery

UCLA Medical Center

Los Angeles, California

wmoore@mednet.ucla.edu

Disclosures: Educational speaker for Silk Road Medical.



Michael C. Stoner, MD, RVT, FACS

Chief, Division of Vascular Surgery
University of Rochester Medical Center
Rochester, New York

michael_stoner@urmc.rochester.edu

Disclosures: Case proctor and educational consultant for Silk Road Medical.

Endovascular

TODAY

