

Endovascular TODAY

June 2009

Advances in Embolization



The Role of Hydrogel-Coated Coils in
the Treatment of Peripheral
Vascular Abnormalities

ADVANCES IN EMBOLIZATION

The Role of Hydrogel-Coated Coils in the Treatment of Peripheral Vascular Abnormalities

The use of coil embolization—a less-invasive treatment option for a variety of conditions in the intracranial and peripheral vasculature, such as hemorrhage, aneurysms, and vascular abnormalities—is growing. However, several clinical problems have been associated with its use, including coil migration, nontarget embolization, compaction, and collateral vascularization, which may lead to further invasive procedures, additional risk to patients, and increased costs. Issues contributing to these clinical problems include inadequate filling of the vascular space and difficulty in coil placement.

Advances in embolization technology have addressed these issues and led to the development of helical platinum coils with an outer layer of hydrogel polymer that swells in the presence of blood to provide additional filling of the vascular space and improved stability. A detachable delivery system provides improved control over the placement of coils, diminishing the chance of coil migration and nontarget embolization. Hydrogel-coated coils have been successfully used in cerebral vascular applications for a number of years, and the technology has been cleared by the U.S. Food and Drug Administration for use in peripheral vascular applications.

This white paper supplement, sponsored by Terumo Interventional Systems (Somerset, NJ), developer of the AZUR Peripheral HydroCoil Embolization System, provides an overview of current technologies, issues, and advances in coil embolization. The white paper reviews key clinical experience and results of numerous clinical studies evaluating hydrogel-coated coils in cerebral vascular applications, as well as early clinical experience in peripheral vascular applications. Case studies also illustrate the use of hydrogel-coated coils in peripheral applications such as arteriovenous malformations and renal artery aneurysms. A growing body of evidence suggests that the expansion of the hydrogel enables superior mechanical occlusion, increased healing, lower recurrence rates, and the use of fewer coils for procedures.

Terumo Interventional Systems is committed to providing innovative technologies that allow interventional radiologists to more effectively treat a variety of diseases and conditions with less risk, pain, and recovery time. The unique characteristics of its hydrogel-coated coils offer the potential to achieve better patient care, cost savings, and increased patient satisfaction.

Table of Contents

Introduction	4
Clinical Applications	4
Current Coil Technology: Role & Issues	4
Coil migration	5
Nontarget embolization	5
Reperfusion	6
Coil compaction	6
Thrombus resorption/resolution	6
Hydrogel-Coated Coils: Greater Filling & Mechanical Occlusion	6
Detachable Delivery System	7
Clinical Track Record	7
Clinical Experience: Peripheral Vascular Applications	9
Additional Benefits	10
Conclusion	11
Clinical Case Studies	12
Arteriovenous Malformation	12
Renal Artery Aneurysm	13
References	14

INTRODUCTION

Since the 1960s, advances in catheterization techniques and innovations in technology have allowed physicians to nonsurgically manage a variety of medical conditions in the cerebral and peripheral vasculature, such as hemorrhages, aneurysms, and vascular abnormalities, where blood vessel occlusion is required for the effective treatment of patients.¹

Key among these developments have been the introduction and ongoing evolution of embolotherapy—a minimally invasive technique in which physicians introduce embolic agents ranging from chemicals and synthetic materials to metal coils into blood vessels via catheters to block blood flow.² Current materials used in embolotherapy include liquids, particles, gelfoam, microfiber collagen, and coils.² Coils were introduced in 1975 and are routinely used for a variety of conditions depending on a patient's diagnosis and treatment plan. In particular, microcatheters allow superselective coil embolization of bleeding vessels, aneurysms, tumors, and vascular abnormalities.³ However, problems such as coil migration, nontarget embolization, collateralization, and compaction can occur, negatively impacting the success of treatment.⁴⁻⁶

To address these challenges, a new generation of peripheral vascular coils has been developed. The AZUR Peripheral HydroCoil Embolization System (Terumo Interventional Systems, Somerset, NJ) was recently cleared for marketing by the U.S. Food and Drug Administration and is the first peripheral platinum coil embolization system with a hydrogel coating that expands when introduced into the bloodstream, delivering greater filling and mechanical occlusion with fewer coils (Figure 1). The system is based on technology successfully used in cerebral vascular embolization applications since 2002.



Figure 1. AZUR Detachable Peripheral HydroCoil System.

CLINICAL APPLICATIONS

Coil embolization is performed tens of thousands of times per year in the peripheral vasculature in procedures less invasive than surgery. In 2006, coils were utilized in 42,500 peripheral vascular cases in the United States.⁷ The predominant use was to embolize hemorrhages (approximately 16,000 cases) and included:

- Gastrointestinal hemorrhage
- Pelvic hemorrhage
- Hemoptysis
- Epistaxis
- Posttraumatic hemorrhage
- Pseudoaneurysm

Coil embolization also is frequently used to treat a variety of peripheral aneurysms (approximately 11,000 cases in 2006) and vascular abnormalities, such as hemangiomas, arteriovenous malformations (AVMs), and arteriovenous fistulas (approximately 5,000 cases in 2006).⁷ The technique also is used to occlude blood supply to tumors and treat varicocele, among other conditions.

CURRENT COIL TECHNOLOGY: ROLE & ISSUES

Coils have several advantages over other embolic agents such as polyvinyl alcohol, trisacryl gelatin microspheres, and gelfoam.⁴ For example, coils

can be positioned under fluoroscopic control, with immediate knowledge of nontarget embolization.⁴ In addition, platinum microcoils, delivered through microcatheters, are particularly useful when superselective coil embolization is required. Occlusion typically occurs as a result of coil-induced thrombosis rather than complete mechanical occlusion of the lumen by the coil.⁶ To increase thrombogenicity and reduce recurrence rates, synthetic fibers of various lengths sometimes are added to bare-metal coils (Figure 2).⁶ Bare-metal and fibered coils are available in a variety of dimensions for use in vessels, aneurysms, and malformations of various sizes and shapes.

Although bare-metal and fibered coil placement has proven to be safe and effective in the treatment of a range of cerebral and peripheral vascular conditions, several clinical problems have been identified with their use. For example, embolization of aneurysms with bare-platinum coils has a high incidence of incomplete aneurysm obliteration and recurrence—in two different studies, the authors have found recurrence rates of 33% at 1 year and 25% at 2 years, respectively.^{8,9} A 2003 study reported a 14% incidence of rebleeding after coil embolization of lower gastrointestinal hemorrhage.¹⁰ Recurrent hemorrhage may result in further invasive therapies and additional risk to patients, diminishing the benefits of the initial less-invasive procedure. Reduced coil mesh stability and recanalization over time, requiring retreatment, surgery, or other interventions, also have been reported.^{9,11}

In particular, several clinical issues have been associated with bare-metal and fibered coil embolization, including:

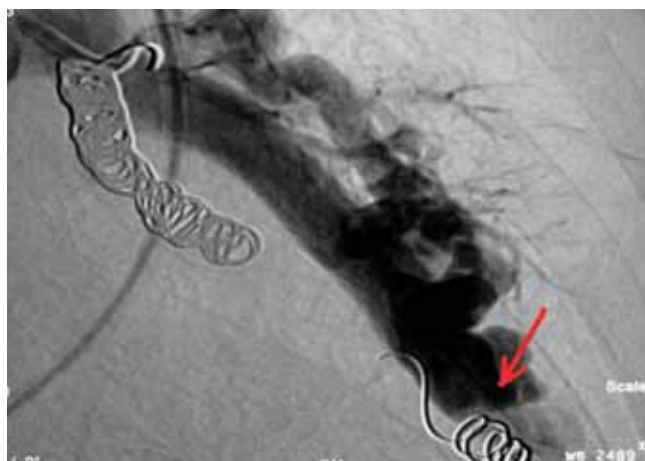
- **COIL MIGRATION.** Ideally, occlusion from embolotherapy occurs quickly and only at the targeted site: the coil is placed at the desired

location where it occludes the vessel and does not move from there. However, in some instances, coils migrate from where they were placed, creating adverse effects (Figure 3). Coil migration needs to be minimized in order to achieve successful treatment and avoid occlusion of sites other than the target. This issue is of particular concern with the pushable coils traditionally used for peripheral vascular applications, which cannot be repositioned.²

- **NONTARGET EMBOLIZATION.** In a related problem, nontarget embolization can occur if coils are placed or migrate to areas in the artery other than those intended to be occluded. Nontarget embolization can negatively affect treatment success, cause complications such as organ necrosis, and result in additional procedures to correct the problem.

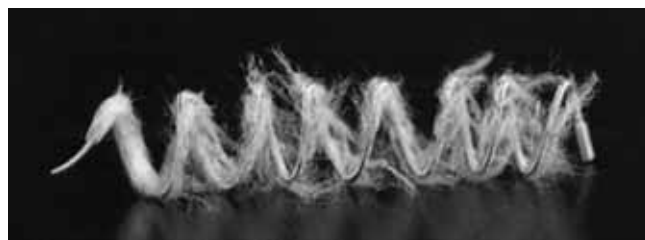

Figure 2. Nester Embolization Coil (Cook Medical, Bloomington, IN).



(Image courtesy of Craig Greben, MD)

Figure 3. Migration of a pushable coil in a pulmonary AVM.

- **REPERFUSION.** Reperfusion, or persistent flow at the target site after embolization, can be caused by such problems as recanalization and collateral vascularization. Rates of reperfusion after embolization of pulmonary AVMs range from 7% to 57%, with recanalization accounting for 63% to 100% of those cases.^{12,13} A study by Pollak and colleagues found that 16% of pulmonary AVMs treated with bare-metal and fibered coils experienced reperfusion, resulting in significant risk of adverse events.¹⁴ Another study found that recanalization of AVMs treated with bare-metal and fibered coils was associated with increased feeding artery diameter, low number of coils, use of oversized coils, and proximal coil placement within the feeding artery.¹³ Collateral reperfusion also can occur if coils are not placed at the correct target. For example, a pulmonary AVM must be embolized at the nidus, or the risk of collateral reperfusion is high. Detachable coil embolization systems that offer more control to precisely place coils may reduce the incidence of reperfusion.

- **COIL COMPACTION.** Very small movement of coils can result in compaction of coils at the target site, sometimes leading to reopening of the vessel. Compaction is an important contributing factor in the reopening of aneurysmal lumens, which may expose patients to the risk of recurrent hemorrhage.^{11,15,16}

- **THROMBUS RESORPTION/RESOLUTION.** Reopening of occluded vessels may be caused by factors other than compaction, such as thrombus resorption or resolution.^{5,15} Thrombus resorption or resolution may reduce the percentage of occlusion, possibly leading to recanalization, compaction, regrowth, and rebleeding.

HYDROGEL-COATED COILS: GREATER FILLING & MECHANICAL OCCLUSION

Interventional radiologists can now tackle these clinical issues with an important new advance in peripheral vascular coil embolization. Based on technology used successfully in cerebral vascular applications, the AZUR HydroCoil Embolization System is the only peripheral platinum coil embolization system with a hydrogel coating that expands when introduced into the bloodstream, delivering greater filling and mechanical occlusion with fewer coils.⁶

HydroCoil implants are helical platinum coils whose outer layer is a biologically inert hydrogel polymer. The hydrogel technology was developed to improve the endovascular occlusion of intracranial aneurysms.⁴ When hydrogel-coated coils are deployed into the vascular space using conventional coil techniques, the acrylamide/sodium acrylate polymer swells. In the presence of blood, the coating undergoes a limited expansion within the first three minutes, and fully expands within 20 minutes (Figure 4).¹⁶ The result is




Figure 4. AZUR HydroCoil implants: unexpanded (A) and expanded (B).

greater filling and stabilization of vascular space—nearly five times more filling volume for the 0.018-inch coil and four times more filling volume for the 0.035-inch coil versus platinum coils of the same size. This greater filling of the interstices of the coil mass and resulting high-percentage filling volume may result in reduced recurrence rates.²

HydroCoil implants provide a biologically inert scaffolding for natural tissue proliferation and wound healing.¹⁷ The hydrogel layer does not degrade in the body and is not bioactive. In fact, acrylamide polymers are commonly used in other implants, such as ocular lenses and vascular sealing devices. The expanded hydrogel, which remains soft and compliant, provides a stable and permanent platform for blood stasis, thrombus organization, and neointima formation. The hydrogel-coated coils will not continue to expand once equilibrium is achieved. They also do not exert expansive force on the walls of the vessel, as the hydrogel only expands where there is space available, and they are compatible with imaging modalities.

DETACHABLE DELIVERY SYSTEM

The HydroCoil System uses a detachable delivery system, allowing physicians to detach coils in < 1 second with the push of a button (Figure 5). With the capability to withdraw and reposition the coil until it is securely placed, the easy-to-use system minimizes the risk of coil migration and nontarget embolization.^{2,5} This design provides a high level of control, especially important in high-flow areas and challenging vascular anatomy such as that found in the peripheral vasculature, in which targeted embolization with pushable coils is difficult.²

The thermomechanical detachment is not operator-dependent, ensuring more precise deployment of coils. The tether is tied and bonded

with adhesive to the proximal end of the HydroCoil implant (Figure 6). The detachment zone is < 0.5mm long. The shortness of this rigid zone improves maneuverability and decreases the likelihood of vessel wall trauma during placement. Heat severs the polymer tether connecting the pusher to the coil. When the detachment zone is severed, no melted polymer or particles are released. Only a very short tail—with a square end—remains on the coil, and visible and audible indicators of detachment are provided (Figure 7).

CLINICAL TRACK RECORD

HydroCoil implant embolization has been shown to be safe and effective.^{9,18} Results of clinical studies evaluating the core technology of the AZUR Peripheral HydroCoil System used in cerebral vascular applications, as well as initial studies and clinical experience in the peripheral vasculature, have shown that the expansion of the hydrogel enables superior mechanical occlusion, lower recurrence rates, and increased healing.^{8,19,20}

Because the volume of coils is defined as πr^2 times coil length, small increases in the thickness of the coil result in a large increase in coil volume.¹⁵ A number of studies have demonstrated the greater filling achieved with hydrogel-coated coils, as well as other benefits. For example, a recent study by Gaba and colleagues evaluating the embolization of intracranial aneurysms



Figure 5. The AZUR Detachment Controller facilitates manipulation of the coil prior to detachment.




Figure 6. Detachment mechanism of the AZUR Detachable Coil.

showed that the percentage of occlusion (by volume) of aneurysms is significantly greater with hydrogel-coated coils than bare-platinum coils.²¹ Specifically, volumetric percentage occlusion with HydroCoil implant embolization was 84.8% versus 29.8% with bare-platinum coils. This study also found lower recurrence and retreatment rates with HydroCoil implants.

In an animal study directly comparing several coil types, Ding and colleagues found that HydroCoil implants allowed significant increases in filling volume compared with the other coils evaluated, including bare-platinum coils (Figure 8).⁵ The technology also achieved improved coil stability, decreased compaction, improved durability of treatment results, and increased long-term occlusion rates. The authors concluded that the results were not dependent upon host reaction but on the fact that the aneurysm was filled largely with hydrogel rather than thrombus. Excluding thrombus from the cavity prevented regrowth from thrombus resorption or recanalization and minimized compaction.⁵

Cloft and colleagues found that the expanding hydrogel displaces clotting blood from the aneurysm lumen, improving packing density.¹⁶ In their study, the HydroCoil implants achieved 72% packing of the aneurysm lumen compared with 32% packing density achieved with standard bare-platinum coils.¹⁶




Figure 7. Detachment mechanism once the coil has been detached.

A large, prospective observational study of the treatment of cerebral aneurysms found that HydroCoil implants can be safely deployed with similar initial complication rates as bare-platinum coils but improved aneurysm filling and significantly fewer major recurrences at intermediate angiographic follow-up.¹⁹ Another prospective study of the treatment of intracranial aneurysms also found significantly lower recurrence rates for hydrogel-coated coils than those reported with platinum coils.⁸

The HydroCoil System was designed to allow prolonged repositioning in the vascular space even while achieving substantial expansion. Importantly, studies of coil volume rates showed no overexpansion of the coil/hydrogel mass into the parent artery and no increase in aneurysm size due to expansion of the hydrogel.⁶ In addition,

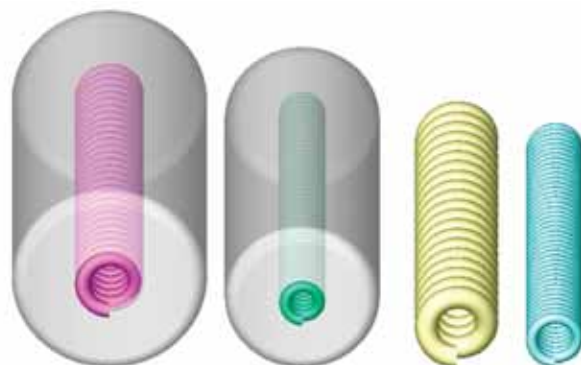


Figure 8. Relative diameter (expanded/unexpanded) of HydroCoil 0.035-inch and HydroCoil 0.018-inch versus bare-platinum coils 0.035-inch and 0.018-inch.

no cases of delayed parent artery compromise from overexpansion were observed.⁶

Analysis of aneurysms treated with HydroCoil implants in animal models have demonstrated fibrosis and endothelialization of the aneurysm wall, suggesting a healing response that may play an important role in the obliteration of aneurysms not obtained with the use of bare-platinum coils alone.^{8,22}

CLINICAL EXPERIENCE: PERIPHERAL VASCULAR APPLICATIONS

Peripheral vascular applications of hydrogel-coated coils would be expected to mirror intracranial applications in overall ease of use and effectiveness. As with other microcoils, hydrogel-coated coils can be utilized in a wide variety of peripheral vascular applications, including hemorrhage, peripheral aneurysms and pseudoaneurysms, treatment of vascular anomalies such as AVMs in the lungs and extremities, arteriovenous fistulas, and as an adjunct to transarterial chemoembolization of tumors, as well as the treatment of varicoceles.

In a study evaluating use of HydroCoil implants to occlude the mesenteric artery, Bui and colleagues concluded that the unique characteristics of the hydrogel-coated coils allowed precise and safe deployment of the coil and fast, complete occlusion of the mesenteric artery, which is resistant to more conventional embolic agents. Their success suggests that this new technology may be of great benefit in the control of bleeding outside the neurovascular system.⁴

In a case report by Greben and colleagues, a mix of coils, including HydroCoil implants, was used to

treat a large, wide-necked aortic pseudoaneurysm near the renal and mesenteric arteries (Figure 9). The authors described a number of potential advantages of hydrogel-coated coils based on the successful procedure. The use of the expanding coils allowed them to more effectively fill the volume and potentially decrease the need for additional coils, with their associated increased procedure time and costs. According to the authors, an additional benefit of the detachable HydroCoil System was that it allows the operator to ensure optimal positioning before deployment, allowing for aggressive coil packing and maximizing the chances of successful initial treatment, while minimizing the risk of nontarget embolization that might occur with forcing pushable coils into an already dense coil nest.²³

Hydrogel-coated coils have been used in numerous peripheral vascular cases since the introduction of the AZUR Peripheral HydroCoil Embolization System. In a growing registry of more than 70 cases covering the full range of peripheral vascular applications, clinicians overwhelmingly have rated the performance of hydrogel-coated coils as excellent or good on measures of positioning, repositioning, detachment, placement/stability, and overall performance (Data on file at Terumo Interventional Systems). In particular, clinicians reported that the system offered ease of detachment, control during placement

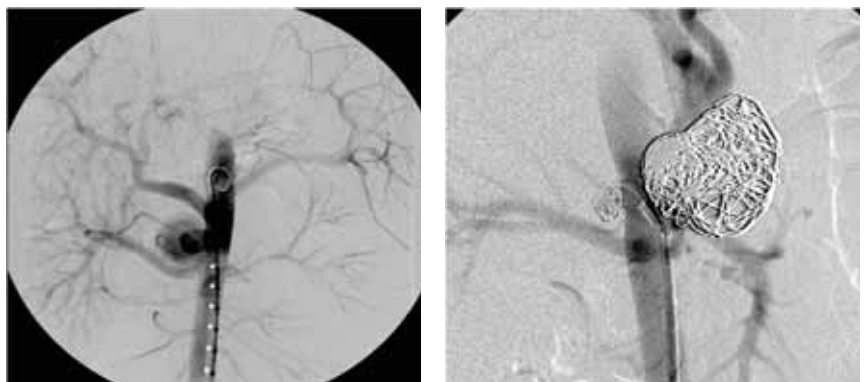


Figure 9. Treatment of a large aortic pseudoaneurysm.

and repositioning of the coils, and fewer coils needed for procedures. Cases include the use of HydroCoil implants alone or in combination with fibered or bare-platinum coils. Most procedures were successfully completed, with no complications.

In a June 2008 *Endovascular Today* article, Gandras, Greben, and colleagues from North Shore University Hospital in New York reported on their experience with a large number of cases performed since 2004 in which newer embolization tools such as hydrogel-coated coils have been used in complex peripheral endovascular applications.² Their experience has demonstrated that detachable HydroCoil implants offer a greater degree of precision than pushable microcoils because they can be repositioned or removed if their initial position is not acceptable to the operator. This capability may reduce the risk of nontarget embolization, coil migration, vessel thrombosis, and aneurysm rupture.²

They also reported that the hydrogel coating allows the clinician to exclude more volume with potentially fewer microcoils placed. The authors concluded that: “The deployment of the detachable microcoil is precise and, admittedly, once one is exposed to this degree of performance, it is difficult to return to standard, older technology... Many of our cases could only be performed by using the precision of the truly retractable and detachable microcoil because of the location of side branches with respect to the aneurysm neck and the high-flow nature of arteriovenous fistulas and malformations.”²

ADDITIONAL BENEFITS

Clinical benefits of hydrogel coils, such as reduced need for costly retreatments, the potential for lower complication rates, and reduced procedure times, may lead to improved patient care and

“The deployment of the detachable microcoil is precise and, admittedly, once one is exposed to this degree of performance, it is difficult to return to standard, older technology... Many of our cases could only be performed by using the precision of the truly retractable and detachable microcoil...”²

higher patient satisfaction. Use of hydrogel coils also could provide several other key benefits, including cost savings if fewer coils are required per case to achieve thrombosis.^{4,23} In a study by Gaba, the increased filling volume associated with HydroCoil implants enabled a decrease in total coil length.²¹ A study by Croft and colleagues also observed a decrease in the number of coils per aneurysm (3.9 coils/aneurysm for HydroCoil implants vs 4.6 coils/aneurysm for bare-platinum coils) and decreased coils per mL of aneurysm volume (55 coils/mL with HydroCoil implants vs 80 coils/mL with bare-platinum).¹⁶

A reduction in coil inventory requirements could result in lower inventory carrying costs, and fewer coils on the shelf could mean fewer coils that have the potential to expire. In addition, the HydroCoil System provides the ability to utilize a mix of detachable and pushable coils, providing needed flexibility for clinicians and potentially improving the cost-effectiveness of treatment.

Fewer coils utilized also might translate into reduced procedure times and fewer potential complications, benefiting patients, clinicians, and hospitals.²³ This was demonstrated in the study by Gaba that showed a decrease in fluoroscopy time with hydrogel coils compared with bare-platinum coils,²¹ which also reduced patient exposure to unnecessary radiation.

CONCLUSION

Coil embolization is a less-invasive treatment option for a variety of conditions in the intracranial and peripheral vasculature, such as hemorrhage, aneurysms, and vascular abnormalities. However, several clinical issues have been associated with its use, including coil migration, nontarget embolization, compaction, and collateral vascularization, which may lead to further invasive procedures and additional risk to patients, thereby diminishing the benefits of this less-invasive approach. Many of these problems are caused, at least in part, by inadequate filling of the vascular space and inadequate control of coil placement, problems associated with pushable bare-platinum coils. However, advances in embolization technology now enable interventionalists to approach even the most challenging

anatomy with new capabilities and confidence. The AZUR Peripheral HydroCoil Embolization System provides additional filling of the vascular space and improved stability. Its detachable delivery system offers improved control over the placement of coils, diminishing the chance of coil migration and nontarget embolization. Results of numerous clinical studies evaluating the core HydroCoil implant technology in cerebral vascular applications, as well as a growing body of clinical experience in the treatment of peripheral vascular conditions, have shown that the expansion of the hydrogel enables superior mechanical occlusion, increased healing, lower recurrence rates, and the use of fewer coils for procedures. These benefits offer the potential to achieve better patient care, cost savings, and higher patient satisfaction. ■

Clinical Case Study

ARTERIOVENOUS MALFORMATION

A high-flow pulmonary arteriovenous malformation in a 66-year-old woman was occluded with HydroCoil implants in a 75-minute procedure at the Montefiore Medical Center, the University Hospital and Academic Medical Center of the Albert Einstein College of Medicine, in Bronx, NY. This 3 x 3 x 3cm AVM in the middle lobe of the right lung was fed by a 3mm parent vessel (Figure 10).

The malformation was accessed through a 90cm 8F sheath from the right femoral artery. A Progreat microcatheter (Terumo Interventional Systems) was used to place two 4mm x 10cm, 0.018-inch detachable HydroCoil implants. A Prowler microcatheter (Cordis Corporation, Warren, NJ) then was used to place one Interlock fibered coil (Boston Scientific Corporation, Natick, MA). Positioning, repositioning, detachment, placement, and stability of the coils all were rated excellent, as was the overall performance of the HydroCoil implants. The malformation was successfully occluded, and no complications or adverse events were reported (Figure 11).

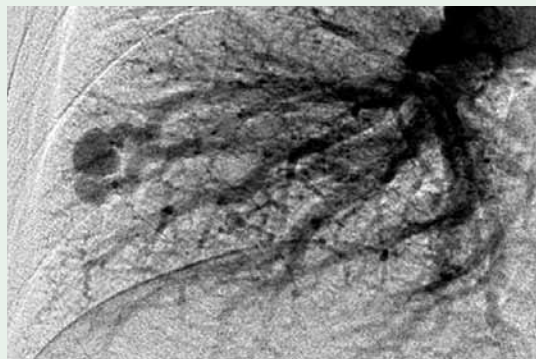


Figure 10. Pulmonary AVM in middle lobe of right lung.

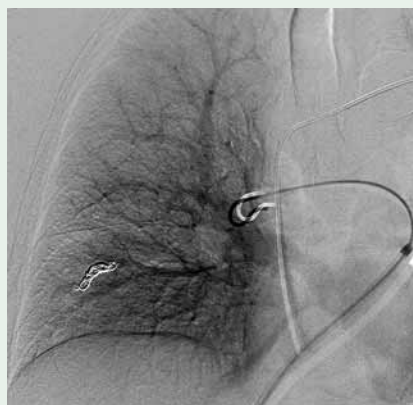


Figure 11. The malformation was successfully occluded.

Clinical Case Study

RENAL ARTERY ANEURYSM

Physicians at Emory University Hospital in Atlanta used HydroCoil implants to occlude a 2 x 1 x 1cm aneurysm in the right renal artery of a 70-year-old man (Figure 12). As expected, the 5mm to 6mm-diameter right renal artery, the aneurysm's parent vessel, had high flow. The aneurysm was accessed through the right femoral artery with a SOS OMNI II (AngioDynamics, Queensbury, NY) guide catheter through a 6F renal double-curve Pinnacle Destination sheath (Terumo Interventional Systems).

The first coil introduced into the aneurysm was removed because it was too large (20mm x 20cm). The next coil (10mm x 15cm) prolapsed through the wide neck of the aneurysm into the parent vessel and thus also was removed. A 5mm x 15cm Express LD stent (Boston Scientific Corporation) was placed across the neck of the aneurysm. A Progreat microcatheter (Terumo Interventional Systems) over a Glidewire GT guidewire (Terumo Interventional Systems) was then used to access the aneurysm for placement of three 0.018-inch detachable HydroCoil implants (one 16mm x 20cm coil and two 8mm x 10cm coils), achieving stasis of flow (Figure 13). Positioning, repositioning,

detachment, placement, and stability of these coils were excellent. A total of 110mL intravenous radiocontrast was used during the procedure. The physicians reported that the HydroCoil implants were easy to place, and no complications or adverse events occurred.

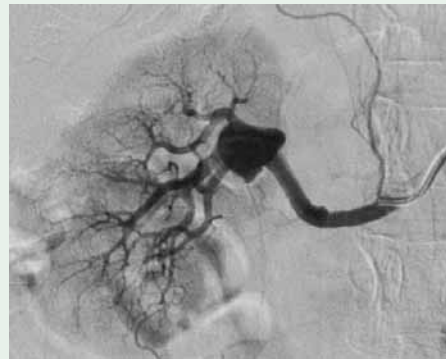

Figure 12. The size of this aneurysm of the right renal artery was 2 x 1 x 1cm.

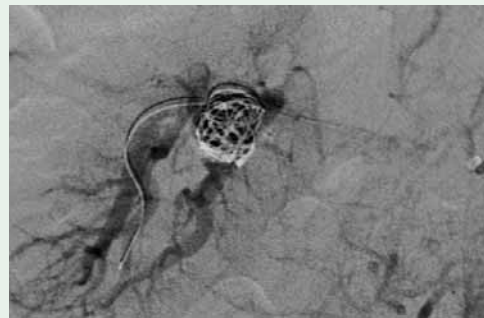


Figure 13. Three 0.018-inch AZUR Detachable HydroCoil implants were used to achieve stasis of flow.

1. White R Jr. Interventional radiology: reflections and expectations. *Radiology*. 1987;162:593–600.
2. Gandras E, Greben C, Putterman D, et al. Visceral arterial embolization. *Endovascular Today*. 2008;6:66–74.
3. Funaki B. Superselective embolization of lower gastrointestinal hemorrhage: a new paradigm. *Abdominal Imaging*. 2004;29:434–438.
4. Bui J, West D, Pai R, Owens C. Use of a hydrogel-coated self-expandable coil to salvage a failed transcatheter embolization of a mesenteric hemorrhage. *Cardiovasc Intervent Radiol*. 2006;29:1121–1124.
5. Ding Y, Dai D, Lewis D, et al. Angiographic and histologic analysis of experimental aneurysms embolized with platinum coils, Matrix, and HydroCoil. *Am J Neuroradiol*. 2005;26:1757–1763.
6. Kallmes D, Fujiwara N. New expandable hydrogel-platinum coil hybrid device for aneurysm embolization. *Am J Neuroradiol*. 2002;23:1580–1588.
7. Millennium Research Group. *US Market for Peripheral Vascular Devices*. March 30, 2007. Pub ID: MIL 1656538.
8. Deshaies E, Adamo M, Boulos A. A prospective single-center analysis of the safety and efficacy of the HydroCoil embolization system for the treatment of intracranial aneurysms. *J Neurosurg*. 2007;106:226–233.
9. Deshaies E, Bagla S, Agner C, et al. Determination of filling volumes in HydroCoil-treated aneurysms by using three-dimensional computerized tomography angiography. *Neurosurg Focus*. 2005;18:E5.
10. Kuo W, Lee D, Saad W, et al. Superselective microcoil embolization for the treatment of lower gastrointestinal hemorrhage. *J Vasc Interv Radiol*. 2003;14:1503–1509.
11. Bavinszki G, Talazoglu V, Killer M, et al. Gross and microscopic histopathological findings in aneurysms of the human brain treated with Guglielmi detachable coils. *J Neurosurg*. 1999;91:284–293.
12. Fidelman N, Gordon R, Bloom A, LaBerge J, Kerlan R. Reperfusion of pulmonary arteriovenous malformations after successful embolotherapy with vascular plugs. *J Vasc Interv Radiol*. 2008;19:1246–1250.
13. Milic A, Chan R, Cohen J, et al. Reperfusion of pulmonary arteriovenous malformations after embolotherapy. *J Vasc Interv Radiol*. 2005;16:1675–1683.
14. Pollak J, Saluja S, Thabet A, et al. Clinical and anatomic outcomes after embolotherapy of pulmonary arteriovenous malformations. *J Vasc Interv Radiol*. 2006;17:35–45.
15. Sluzewski M, van Rooij W, Slob M, et al. Relation between aneurysm volume, packing, and compaction in 145 cerebral aneurysms treated with coils. *Radiology*. 2004;231:653–658.
16. Cloft H. HydroCoil for endovascular aneurysm occlusion (HEAL) study: 3–6 month angiographic follow-up results. *Am J Neuroradiol*. 2007;28:152–154.
17. Plenk H, Killer M, Richling B. Pathophysiologic considerations on HydroCoil and platinum coil-occluded retrieved human cerebral aneurysms. Microvention Symposium. American Society of Interventional & Therapeutic Neuroradiology; 2005. Toronto.
18. White P, Lewis S, Nahser H, Sellar R, Goddard T, Gholkar A. HydroCoil endovascular aneurysm occlusion and packing study (HELPS Trial): Procedural safety and operator-assessed efficacy results. *Am J Neuroradiol*. 2008;29:217–223.
19. Fanning N, Berentei Z, Brennan P, Thornton J. HydroCoil as an adjuvant to bare platinum coil treatment of 100 cerebral aneurysms. *Neuroradiology*. 2007;49:139–148.
20. Geyik S, Yavuz K, Cekirge S, Saatci I. Endovascular treatment of basilar and ICA termination aneurysms: effects of the use of HydroCoils on treatment stability in a subgroup of patients prone to a high recurrence rate. *Neuroradiology*. 2007;49:1015–1021.
21. Gaba R, Ansari S, Roy S, et al. Embolization of intracranial aneurysms with hydrogel-coated coils versus inert platinum coils. *Stroke*. 2006;37:1443–1450.
22. Cloft H, Kallmes D. Aneurysm packing with HydroCoil Embolic System versus platinum coils: initial clinical experience. *Am J Neuroradiol*. 2004;25:60–62.
23. Greben C, Axelrod D, Charles H, Gandras E, Bank M, Setton A. Treatment of posttraumatic aortic pseudoaneurysms using detachable hydrogel-coated coils. *J Trauma*. 2008;1–4.



Expanding **TERUMO** Territory.™

Watch this little coil
become the biggest thing
in peripheral embolization



(It will only take a few minutes)

AZUR™

Peripheral HydroCoil®
Embolization System

Expanding your capabilities.

AZUR features a unique hydrogel polymer coating that expands
for increased filling with fewer coils.^{1,2}

For more information, call 800.862.4143 to speak to an Inside Sales Customer Care Representative
or visit www.terumo/s.com

References:

1. Szewski M, van Rooij WJ, Slob MI, Beecda JO, Slump CH, Wijnsda D. Relation between aneurysm volume, packing, and compaction in 145 cerebral aneurysms treated with coils. *Radiology*. 2004;231(3):653-658.
2. Cloft HJ, Kallmes DE. Aneurysm packing with HydroCoil Embolic System versus platinum coils: initial clinical experience. *AJNR Am J Neuroradiol*. 2004;25(1):60-62.

Terumo Interventional Systems, 2101 Cottontail Lane, Somerset, NJ 08873, Fax: 800.411.5870

©2008 Terumo Medical Corporation. All rights reserved. All brand names are trademarks or registered trademarks of Terumo. HydroCoil is a registered trademark of MicroVention Inc.



TERUMO INTERVENTIONAL SYSTEMS

Endovascular
TODAY



Terumo Interventional Systems
2101 Cottontail Lane, Somerset, NJ 08873
800.862.4143
www.terumo/s.com