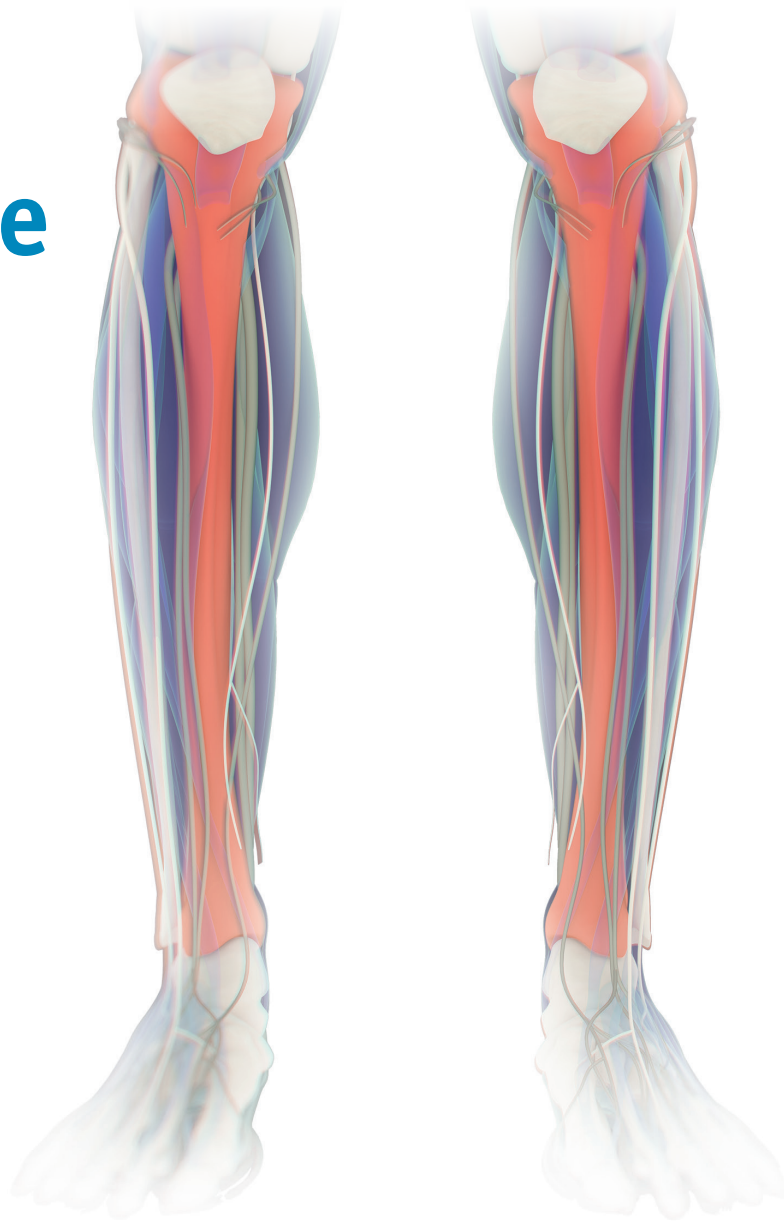

Endovascular TODAY

May 2019

Advancing the Critical Limb Ischemia Treatment Algorithm:

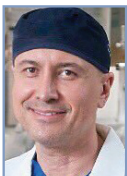Tools & Techniques for Below-the-Knee Success



TIBOR
BALÁZS, MD



PATRICK
GERAGHTY, MD



STEVE
HENA, MD



RALF
LANGHOFF, MD



ROBERT A.
LOOKSTEIN, MD




MARCO
MANZI, MD



MIGUEL MONTERO-
BAKER, MD



JIHAD A.
MUSTAPHA, MD



LUIS MARIANO
PALENA, MD



HANS VAN
OVERHAGEN, MD

Advancing the Critical Limb Ischemia Treatment Algorithm

3 Roundtable Discussion:

The Evolution of the CLI Treatment Algorithm

A multidisciplinary panel shares insights on practice patterns, treatment algorithms, and hopes for future solutions for this challenging disease.

With Ralf Langhoff, MD; Robert A. Lookstein, MD;

Miguel Montero-Baker, MD; and Jihad A. Mustapha, MD, FACC, FSCAI

9 Techniques for Successful BTK Revascularization

An overview of BTK vessel anatomy, related angiosomes, and techniques for optimal outcomes.

By Luis Mariano Palena, MD, and Marco Manzi, MD

16 Case Report: Utilizing IVUS Below-the-Knee

The importance of invasive imaging to guide treatment decisions and improve outcomes.

By Steve Henao, MD, FACS, FACC

19 Case Reports: Use of Atherectomy + DCB in CLI

Tips and tricks to achieve optimal results in patients with complex disease.

By Tibor Balázs, MD

25 The SAVAL Trial

Details on the design and rationale behind this randomized trial studying infrapopliteal drug-eluting stent use for critical limb ischemia.

By Jihad A. Mustapha, MD, FACC, FSCAI; Patrick Geraghty, MD, FACS; and

Hans van Overhagen, MD, PhD, EBIR

ROUNDTABLE DISCUSSION

The Evolution of the CLI Treatment Algorithm

A multidisciplinary panel shares insights on practice patterns, treatment algorithms, and hopes for future solutions for this challenging disease.

WITH RALF LANGHOFF, MD; ROBERT A. LOOKSTEIN, MD; MIGUEL MONTERO-BAKER, MD; AND JIHAD A. MUSTAPHA, MD, FACC, FSCAI


PARTICIPANTS

**Ralf Langhoff, MD**

Medical Director, Head of Department
Angiology/Vascular Medicine
Sankt Gertrauden-Krankenhaus GmbH
Acad. Teaching Hospital Charité
Humboldt University Berlin
Berlin, Germany
ralf.langhoff@sankt-gertrauden.de
*Disclosures: Consultancy fees from Abbott
Vascular, B. Braun, BD Interventional,
Biotronik, Boston Scientific Corporation,
Cordis, a Cardinal Health company, Medtronic,
and Terumo.*

**Robert A. Lookstein, MD**

Professor of Radiology and Surgery
Vice Chair, Interventional Services
Mount Sinai Health System
New York, New York
robert.lookstein@mountsinai.org
*Disclosures: Consultant to Boston Scientific
Corporation, Medtronic, Abbott, and BTG.*

**Miguel Montero-Baker, MD**

Associate Clinical Chief of Vascular Surgery
Associate Professor
Michael DeBakey Department of Surgery
Baylor College of Medicine
Houston, Texas
montero.bkr@gmail.com
*Disclosures: Consulting/proctoring for Abbott,
LimFlow, BD Interventional, Cook Medical,
Boston Scientific Corporation; ownership/stock
in Thermoapeutics, Profusa.*

**Jihad A. Mustapha, MD, FACC, FSCAI**

Associate Professor
Michigan State University
Advanced Cardiac & Vascular Amputation
Prevention Centers
Grand Rapids, Michigan
jmustapha@acvcenters.com
*Disclosures: Consulting agreements with
BD Interventional, Boston Scientific Corporation,
Cardiovascular Systems, Inc., Medtronic,
Philips, and Terumo.*

How would you describe the current critical limb ischemia (CLI) landscape, particularly below-the-knee (BTK) disease?

Dr. Lookstein: The last 5 years have brought about a revolution, and we can now cross 90% to 95% of all lesions. It's not 100%, but it opens opportunities to treat a much broader segment of the population. The unmet need at this point is dense circumferential calcification in the tibial arteries—it is still a technical challenge to cross.

Dr. Montero-Baker: I would agree; we've made immense strides in chronic limb-threatening ischemia therapy. With the development of robust technical skills and more appropriate technology, operators are able to treat more complex and distal disease patterns. This perfect storm of technical skills and advanced tools makes the question of "What's possible?" irrelevant and the question "What's appropriate?" extremely relevant. Overall unmet needs are mainly surrounding intraoperative performance goals. I'm still dumfounded

when I listen to opinion leaders at scientific summits who quote their own personal experience as the basis for a recommendation. I respect and appreciate experience, but we need objective, measurable tools that help us understand the effect of our intervention in the setting of the patient's needs.

Moreover, this is a complex, multidimensional problem. Revascularization, as important as it may be, is really just part of the equation. We can't negate the transcendental impact of risk modification, medical optimization, nutritional support, wound care, podiatric care, and psychological support.

Finally, I also agree that extensive occlusive and calcified disease of the BTK vessels may be the most technically challenging scenario to treat. If you have a target, you can still attempt a few things and be aggressive when scaffolding, but the results—in my view—inevitably end up being less than optimal.

Dr. Mustapha: We are starting to see more patients with stage 3 or 4 chronic kidney disease who are not necessarily on dialysis and may have diabetes. Evolving technical approaches (eg, Schmidt technique, arterial-venous flow reversal, etc) have really transformed the ability to treat the high-percentage occlusions that we used to not even attempt.

What's interesting is the robustness of medical therapy that we have adopted in our practice. With statins, we make sure the patient's LDL (low-density lipoprotein) is < 70 mg/dL and that the HDL (high-density lipoprotein) is somewhat elevated. We send the patients to supervised exercise programs. The patients go on dual antiplatelet therapy and ACE (angiotensin-converting enzyme) inhibitors, if they can tolerate them. There are multiple modalities of medications that are not being utilized in these patients, but we are starting to use them postprocedure. Today in our practice, we put patients on 80 mg of atorvastatin. We use dual antiplatelet therapy, and if the patient's lipid profile is not where it needs to be in 3 months, we add ezetimibe. This has worked really well for our patients, but unfortunately, there are no data in this area for the peripheral arteries, only the coronaries.

Dr. Langhoff: There are numerous innovations that have come along over the last few years, but it is not just the devices that improve outcomes for CLI patients. It is my belief that the access strategy and approach to the target vessel are the main drivers of success. Wire technology is probably the most important issue that interventionalists should be aware of if they want to take on "CLI treatment 2.0." There is so-called sad foot, meaning one that is almost lost because it is so difficult to establish flow due to the missing outflow. It takes a lot of effort here to establish outflow and restore blood perfusion to the wound, and is the most challenging type of case.

THE IMPORTANCE OF CARE COORDINATION AND A TEAM APPROACH IN TREATING CLI

Outside of technical advances, how has the approach to CLI care shifted in recent years?

Dr. Montero-Baker: I think we are coming to an understanding of the importance of a team approach to properly care for these patients. I think solo practitioners who have no collaborative interdisciplinary care will slowly become extinct. We truly need to work cohesively in the patient's best interest. Turf wars, particularly among vascular interventionalists, benefit no one. There is so much we can learn from each other!

The Save the Extremity Program (STEP) nests a group of different individuals who bring a different set of tools that ultimately help patients along their recovery process. For many years, our group has promoted the core model termed, "Toe and Flow." This model emphasizes the elemental role that podiatrists/wound care specialists (toe) and vascular interventionalists (flow) play. Lately, we've recognized the importance of a third core element: functional recovery. This led us to pursue a new model called, "Toe, Flow, and Go." The idea is to emphasize the importance of rehabilitation and independent living as ultimate goals of the care compendium.

Dr. Langhoff: In Berlin, the awareness of our specialty among diabetologists, who see most of our CLI candidates, has developed. They've started to notice a difference when they send their patients to a dedicated center with a CLI team versus an interventionalist or pedal bypass surgeon alone. Working within such a team approach is a great opportunity. As an interventionalist, I depend on the feedback from the wound care team. Sometimes we have patients who require interventions twice within the same hospital stay if the wound does not sufficiently heal. Thorough treatment of the underlying disease and the comorbidities is the influencing factor to change the mortality rate and long-term outcome.

Dr. Mustapha: We have what we call the "virtual multidisciplinary team." The interventionalist sees the patient, performs the necessary procedure, prescribes medication, and then refers the patient to the podiatrist. The podiatrist will see the patient for consultation and decide whether amputation is needed. The same patient will see an infectious disease specialist if they have osteomyelitis. The patient will also see our dietician, who often recommends a specific program that includes hormone injections. The patient completes this cycle within 30 days, and then comes back to us. So far, this virtual team has led to phenomenal outcomes for our patients. The collaboration and communication are key.

How can the team approach be improved upon and expanded to regions that currently do not have a robust multidisciplinary strategy?

Dr. Langhoff: Patients often tend to neglect their disease/disorder. Even when they realize that something is going wrong, it may still take them a while to see a physician. Seizing every opportunity for a CLI team member to evaluate a wound or any other relevant parameters by a software-based system would help dramatically speed up the pathway of individual wound care. Presumably, catching the patient at an earlier stage would lead to a better outcome, and this is more easily achieved if performed with an IT solution. Even in regions with a robust multidisciplinary strategy, a tool that would enable patients to easily show a foot lesion to a care provider would be of great benefit. Some training would be required when integrating these new tools, but nowadays almost everyone can handle a smartphone, for example.

Dr. Montero-Baker: It's never easy to have many cooks in the kitchen. We need to look at how we can improve the longitudinal care experience. I'm excited that Boston Scientific is piloting software to try and improve communication between all team members (specifically with the referring physicians who are the community gate keepers). It's not rare that by the time patients make it to our program, their condition has drastically deteriorated. When asked about the reasons for delay in care, I've been told, "I live 4 hours away," "I couldn't get an appointment," "I couldn't get a referral from the right person at the right time," or "You were out of town."

Dr. Mustapha: We need that improvement in patient communication immediately, especially for CLI patients. We can't FaceTime or receive pictures from our patients on our phones because of the lack of security encryption. Patients who undergo limb salvage procedures come to our office every 2 weeks. If they live far away, I don't want them to have to drive 6 hours every 2 weeks, so it would be phenomenal if I could spend 10 minutes over the phone to see everything.

Dr. Lookstein: CMS is going to change all of this very soon—there is now reimbursement for telephone interviews. The door is cracking open, and I think we're going to have more telehealth opportunities in the future, but it's going to be up to each state to determine what is safe. I think we all agree that remote surveillance is an unmet need in terms of the ability to send a patient out of the building and be able to remotely assess the perfusion at a week, 30 days, and 60 days.

Dr. Montero-Baker: Prospective knowledge can become crucial in decision making for reintervention and preventing unnecessary readmissions. The development of telemedicine and patient-directed, user-friendly interfaces is going to be

interesting (eg, photography, sensors, thermometers, etc). An example of such disruptive technology are "smart socks" (from companies such as Siren) that embeds smart threads into a sock to measure subtle changes in temperature. The principle relies on the known fact that before clinically significant breakdown, there is an increase in skin temperature in the diabetic foot. In my opinion, having systems in place to silently capture the data, process it via artificial intelligence protocols, and deliver it to the caregiver will revolutionize medicine.

Dr. Mustapha: Recently in our practice, we have had this discussion about how great it would be for the patient to have something they put on the foot that we can use to measure perfusion. The future right now is in those two elements—telemedicine and a means of measuring perfusion. To be able to tell my CLI patients, "You can stay home, you don't have to drive 2 hours to get to your appointment today," I would love to see that come to life sooner rather than later.

DCB VERSUS DES IN A TREATMENT ALGORITHM What do you think the role of BTK drug-coated balloons (DCBs) and drug-eluting stents (DESs) will be? Are both technologies needed?

Dr. Mustapha: In the first positive DCB trial, long lesions actually responded better than the shorter lesions, which is really reassuring for us.¹ It allows us to tackle the anatomy that scares us interventionalists most, which is the distal portion of the tibial artery just as it becomes the peroneal artery. The distal tibial arteries will benefit the most from proper DCB therapy, as will the ostia of other arteries (eg, going from the tibial peroneal trunk into the peroneal across the anterior tibial and posterior tibial arteries).

On the other hand, scaffolding is phenomenal, and I think scaffolds will be especially beneficial in the proximal anterior tibial and proximal posterior tibial arteries, because this is where dissections most frequently occur. Additionally, if you use a DCB for an intervention and get great results in 90% of the vessel, but there is a flow-limiting dissection in 10% or 20% of it, then you need some way out—now we will finally have scaffolding for that anatomy. This is why I think both BTK DCBs and DESs are extremely valuable.

Dr. Langhoff: Yes, I guess both technologies are needed, although the Lutonix BTK trial is the only trial to date showing positive results with BTK DCB technology.¹ All three of the BTK DES trials had been positive.

The major difference is the lesion location. We stay away from placing BTK stents distally. Proximal, focal lesions do quite well with DESs, but the longer ones will probably benefit more from a DCB, as shown in the Lutonix BTK interim analysis. I am looking forward to the first nitinol-based DES from Boston Scientific, which is currently under investigation;

it could turn out to be a game changer. It makes sense to offer longer BTK DESs than those of the coronary platform.

Dr. Lookstein: What do you think the relative need is for scaffolds versus DCBs?

Dr. Montero-Baker: When it comes to chronic total occlusions (CTOs), yes, we have crossing devices and reentry techniques, but that subgroup of lesions may have the most acute recoil. I explain to patients that we are essentially moving a huge column of cement to the side. We may get that little trickle of flow along its side, but in a day, a week, or a month, it will probably just move back to where it was. It is in those patients that I am very adamant about scaffolding.

Unfortunately, some of these are very long lesions, and scaffolding an entire tibial vessel may be overly aggressive. I do believe in some circumstances, it may be the right thing to do to prevent poor long-term or even midterm results. I'm excited to see what technology like the Tack endovascular system (Intact Vascular, Inc.) or the Saval™ DES BTK (Boston Scientific Corporation) will offer, as they may open the doors to efficiently treating more complex BTK disease patterns.

Dr. Lookstein: I agree with that. Calcium in the BTK circulation isn't going away any time soon. Crossing calcium is certainly technically feasible, but it is challenging and we're treating more challenging patients. I am skeptical that a DCB is going to be able to tackle that, especially as we're dealing with 15- to 30-cm-long lesions. I think DCBs will have their place, but probably not for calcified lesions.

I'm apprehensive about leaving behind a suboptimal result after using a DCB in a patient with an open wound. I am a big believer in scaffolds, and I have heard those stories of peripheral interventionalists using more coronary stents than some of the cardiologists, illustrating the need for stents of that size. I clearly think that the Saval™ DES BTK and any other BTK scaffolds are going to deal with a very significant unmet need.

Dr. Mustapha: The Saval™ DES BTK is going to be a paradigm-shifting tool when it comes out. In the cadaver work that we did, the one unexpected thing we discovered in the tibial arteries was a double layer of smooth muscle cells with different functions. Because of that, we need a tool like the Saval™ DES BTK that has prolonged drug elution. Many don't understand why we need to elute for that length of time. The proliferation or migration of smooth muscle cells in the tibial arteries act completely differently than any other arterial bed in the body. In the coronary arteries, we found five layers, and in the tibial arteries, there are 20 layers, and they actually function. Because of that, the prolonged drug elution of the Saval™ DES BTK will make it our primary scaffold type.

Dr. Lookstein: I agree, 100%. Is there also going to be a reemergence of bioabsorbable scaffolds for this anatomic region? Right now, it doesn't appear so, but I think everybody would agree that maybe we should look at that again in the future. We have to figure out what the exact roles of DCBs and DESs are, and only at that point will we be able to reengage with bioabsorbable scaffolds.

Dr. Mustapha: If you look at recoil in the tibial artery, the highest rates of recoil are actually in the midportion of the vessel, not at the takeoff level of the anterior to posterior tibial artery. We are conducting studies on recoil and have been using intravascular ultrasound (IVUS) in long CTOs. Due to what we've observed on IVUS, we have realized that the smallest available JETSTREAM™ Atherectomy System (Boston Scientific Corporation) achieves better vessel preparation than anything else that I know of. We used to think it was too bulky for the tibial arteries, but based on IVUS, which is the key, the luminal gain we're getting at the end of this procedure is phenomenal.

PERSPECTIVES ON THE RECENT PACLITAXEL DATA AND CURRENT DRUG-ELUTION TREATMENT ALGORITHM

What is your perspective on the recent data related to paclitaxel-coated devices?

Dr. Lookstein: I believe all vascular specialists are concerned about the conclusions of the meta-analysis. I am looking forward to reviewing patient-level data and participating in prospective research to put this issue to rest. Hopefully this will allow a return to a culture where antiproliferative therapy is once again considered standard of care for symptomatic occlusive disease in the femoropopliteal arteries.

Dr. Mustapha: I personally have not changed my practice. I continue to use paclitaxel-coated balloons just as before. We did add the recommended step of informed patient consent. But our overall approach is still the same.

Dr. Langhoff: There is no panic or fear from my side. I think we have to look at this carefully, and I strongly support all of the principal investigators of recent paclitaxel-based trials who are aiming for a 5-year mortality endpoint to collect data on this issue. When I follow the lectures that explain and analyze the Katsanos group's findings, I more and more doubt the reliability of this dataset, because the group samples were miscalculated in terms of crossover procedures and those lost to follow-up, which makes a major difference.

The benefit of this technology is so overwhelming that we have not changed our treatment algorithm so far.

Dr. Montero-Baker: Katsanos et al have shed light on a very sensitive matter. The signal should not be brushed off. That said, I don't agree with the total opposite, meaning overreacting to a particular data set analysis. Responsible and critical analysis is crucial for safer patient interventions. Moreover, not all data related to currently approved market devices were included in this analysis. Also, the most significant conclusions are a matter of associational nature, ignoring true causation. Finally, patient-level data are scarce and overall missing. Health agencies are currently analyzing the data in-depth, and I would defer to them for guidance. For now, I will continue my practice using medication-enhanced devices on case-by-case bases.

BELOW-THE-ANKLE TRENDS AND THE NEED FOR PURPOSE-BUILT TECHNOLOGIES

As the paradigm shifts to allow operators to intervene below the ankle, are the currently available devices adequate? What technologies are still needed, and is there a role for antiproliferative therapy in this area?

Dr. Mustapha: The Savion™ Guidewires (Boston Scientific Corporation) maneuver phenomenally below the ankle; they have done great things for us, especially if you have a pedal loop. I'm a big supporter of opening the artery to the segment where the ulcer is located and delivering blood there directly. Below-the-ankle therapy is a must if there is an occlusion, because if you don't have a good outflow, wound care and medical therapy are not going to help, no matter what you do. Today, we are limited to balloon angioplasty; there is not much more to do.

Dr. Lookstein: We need dedicated devices. I believe there is a growing recognition that the status of the plantar vessels is critical to wound care and limb preservation for patients with advanced disease. I think experienced operators are compulsively performing more pedal angiography and assessing the patency of the plantar circulation, and if the skill set is there, they are doing anything they can to improve or open the circulation through the plantar vessels.

That is a skill set that is not globally uniform, but I think it is being recognized as the next frontier and a growing clinical need. Unfortunately, I frequently have patients sent to me for a second or third opinion, and the supplied films don't show anything below the ankle because the imaging was never performed. We need to educate the clinical teams who are caring for these patients that pedal angiography is critical, and if the status of the plantar vessels is compromised, then the patient should be sent to a specialist who knows how to access those vessels with a guidewire or bypass.

Dr. Mustapha: What is your go-to microcatheter that you use to maneuver across the tibial circulation when you do a pedal loop?

Dr. Lookstein: I will typically use a 0.018-inch support catheter because it has a little more body to it, or I'll use a 0.014-inch over-the-wire balloon—Coyote™ (Boston Scientific Corporation) is great, as well as several other over-the-wire balloons. I strongly prefer doing these cases from an antegrade approach. I think using a contralateral approach is just asking for trouble on multiple levels. It all depends on your setup and whether you believe it is more facile and more efficient with your time to use an over-the-wire balloon or to use a support catheter.

Dr. Montero-Baker: I primarily use Coyote™ as support because I believe it saves a step. When I do use a support catheter, I like the 0.014- and 0.018-inch braided CXI® Support Catheters (Cook Medical). For most retrograde accesses, I do not use a sheath. There are compelling data from our colleagues in Japan that show that when you achieve substantial wound blush, the curves for healing significantly diverge.² I'm happy to see that we are now seriously starting to develop some objective performance goals.

The reality is that we need tools to further assess our results and, moreso, make some timely on-table decisions. I think the development of technology like two-dimensional perfusion angiography or implantable microsensors will drive the adoption and acceptance of below-the-ankle interventions. If we can show that these procedures provide good perfusion, then we can tell ourselves—and more importantly, our colleagues who are referring the cases—that we have achieved an established goal (which further leads to adequate wound healing). It would be amazing to think that in the near future, we could come up with some clear-cut perfusion levels that could easily be interpreted by our foot surgeons/podiatrists in order to establish therapy benchmarks.

Dr. Langhoff: Vessels below the ankle are very small, and we mostly treat the "sad foot" patients. Personally, I have no experience with drug-coated devices in these arteries, as they are often very calcified and hence are not the proper scenario for DCB use.

I learned a lot from my Japanese colleagues and friends, and in my lab, we spend our efforts using wire technology and support catheters, which I think have taken a major step forward in being able to open even very distal and challenging lesions through a bidirectional approach. Around 90% of these procedures are finalized with PTA only.

THE FUTURE OF CLI: WISHLIST DEVICES, COMPARATIVE-EFFECTIVENESS DATA, AND PATIENT-CENTERED OUTCOMES

We've discussed the need for developments in telemedicine, but what other unmet needs remain in the CLI space?

Dr. Mustapha: In terms of devices, we need a microcatheter for the pedal circulation. Many patients come to us with a dissected pedal artery or transmetatarsal artery, because a previous intervention shoved a catheter up and ruined the pedal circulation.

Dr. Lookstein: What about a reliable reentry catheter for the balloon recirculation?

Dr. Mustapha: That would be an amazing thing to have. As we continue to collect IVUS data on long tibial CTO crossing, we have learned many important technical steps to help fill some of the current unmet needs. IVUS-directed CTO crossing via the subintimal space using wires in the tibials is extremely helpful and provides factual feedback to the operator and assists in choosing the best possible treatment modalities. If IVUS shows the crossing wire to be just under the endothelial luminal layer, this allows for almost all therapeutic options, including catheter-based crossing techniques. On the other hand, if the IVUS feedback shows the crossing wire to be deep into the vessel wall (ie, deep media or adventitia), the therapeutic options become very limited and the risk of complications becomes high. Hence, we have the terminology of *deep wall crossing*, which is unfavorable and associated with untoward outcomes. We also have subendothelial or subintimal crossing, which has much more favorable outcomes and allows for the dual antegrade/retrograde catheters crossing technique, leading to easy reentry into the true lumen.

Dr. Lookstein: I think guidewires could clearly be improved upon. I'm excited that the FDA now recognizes that there are unmet clinical needs for this patient population and that trials are going through an expedited pathway. I'm hoping we will soon see a number of devices that are on label for the treatment of CLI in North America. I think an unmet need is comparative-effectiveness research for this anatomic space to prove which therapy works best.

Dr. Langhoff: Wires, wires, and once again wires—they make the difference! Beyond all endovascular approaches, the recruitment of collaterals is an unmet need. A drug or maybe noninvasive counterpulsation that may create better oxygen perfusion to the tissue could be the answer to failed endovascular procedures or bypass surgery. This is still a matter of basic science.

Venous arterialization is also very interesting as a bailout strategy. However, I believe there should be something performed before giving up the arterial pathway to restore oxygen perfusion via the venous side of the collateral bed.

Dr. Montero-Baker: Not all of the efforts in trying to facilitate appropriate patient care may lead to a lot of money making. I think there needs to be investment in the science itself—creating objective performance goals, optimizing our intraoperative data, and better assessment of intraoperative efficiency. I would like to find more support on other research parameters as goals for CLI. I think we should move away from target lesion revascularization (TLR) and find some wound-based, quality-of-life, and/or true walking assessment. We have to change the way studies are performed. We don't have to ignore patency, because it is important to avoid bringing the patient back over and over, but ultimately, the problem is that ischemic wounds don't do well. We need to cure the wounds and make the patient's pain go away and get them back into society.

As we develop more research projects, we should be open to changing the endpoints that we have been adhering to for the last 15 years. We're mature enough as a field now to understand that CLI requires different endpoints moving forward.

Dr. Lookstein: There is a tremendous amount of opportunity to identify patient-centered outcomes related to CLI. To Dr. Montero-Baker's point, freedom from TLR is not the most important variable for a majority of our patients. Pain is a huge driver for this demographic. I don't think we're doing enough to really identify whether an endovascular or surgical approach successfully alleviates pain with or without tissue loss at 6 months or 1 year and how that contributes to someone being able to work, ambulate, and take care of themselves. Much of what contributes to patients' everyday quality of life is independence and how that affects their mood and their ability to be opiate free.

If the entire community treating these patients can embrace a more patient-centered approach, we will hopefully soon identify the best treatment strategy to improve patients' quality of life, not just achieve freedom from TLR. We've been centered on whether the artery is open, and that's only a small piece of the puzzle. We are talking about people who have lost their ability to control their own lives, and we all want to give them control of their lives back and make them functioning members of this global entity. There is a lot of room for improvement there. ■

1. Mustapha JA. Lutonix below-the-knee global DCB IDE study: primary endpoint outcomes at 6 months. Presented at: VIVA 18; November 7, 2018; Las Vegas, NV.

2. Utsunomiya M, Takahara M, Iida O, et al. Wound blush obtainment is the most important angiographic endpoint for wound healing. JACC Cardiovasc Interv. 2017;10:188-194.

Techniques for Successful BTK Revascularization

An overview of BTK vessel anatomy, related angiosomes, and techniques for optimal outcomes.

BY LUIS MARIANO PALENA, MD, AND MARCO MANZI, MD

The worldwide prevalence of peripheral artery disease (PAD) affects 12% of the adult population and up to 20% of individuals aged 70 years or older. Its incidence continues to increase, mainly due to the uncontrolled epidemic of obesity and diabetes mellitus caused by calorie-rich diets and sedentary lifestyles, combined with poorly controlled hypertension and failed attempts at controlling tobacco use.¹⁻³ Critical limb ischemia (CLI) represents the end stage of PAD.

In patients with diabetes, the risk of PAD is three- to fourfold higher and tends to be more aggressive than in patients without diabetes, with a major amputation rate that is 5 to 10 times higher. Typical infrapopliteal (IP) diabetic disease is characterized by a long, multilevel, and multivessel process that involves all three IP arteries.^{4,5} The presence of isolated IP disease is mainly seen in the elderly (> age 80 years) and dialysis-dependent patients.⁶ These patients have a higher risk for amputation and shorter amputation-free survival compared to those with combined femoropopliteal and IP disease.⁷

This article provides a review of the below-the-knee (BTK) anatomy, angiosome concept, and target selection for revascularization, as well as a technical review of crossing strategy and device selection.

BTK VESSEL ANATOMY

Leg Vessel Distribution

The vascularization of the foot is supplied by three tibial vessels: the anterior tibial artery (ATA), posterior tibial artery (PTA), and peroneal artery (PA). The distribution of the three leg vessels at the ankle level presents a high variability. Similar to the anatomic classification of the coronary distribution, the ankle distribution patterns can be classified as *balanced circulation*, *anterior dominant PA*, *posterior dominant PA*, and *single PA*.

Balanced Circulation. In balanced circulation, ATA and PTA are codominant arteries, their course in the leg is straight, and at the ankle level, they directly originate from

the dorsalis pedis and plantar arteries, respectively. The PA is a small, terminal artery (Figure 1).

Anterior Dominant PA. In the anterior dominant PA pattern, the ATA is absent or hypoplastic. Typically, it is a thin vessel with a tortuous course into the leg, ending at the mid or distal leg. The PA is large in size, and at the ankle, it moves anteriorly and keeps the position of the ATA, directly generating from the dorsalis pedis artery (DPA) (Figure 2).

Posterior Dominant PA. In the posterior dominant PA pattern, the PTA is absent or hypoplastic. Like the ATA, the PTA is also typically a thin vessel with a tortuous course into the leg, ending at the mid or distal leg. At the ankle, the larger PA moves posteriorly and keeps the position of the PTA, directly generating from the plantar arteries (Figure 3).

Single Dominant PA. In the single dominant PA pattern, both tibial arteries are hypoplastic and the PA is the only leg vessel supplying the foot. In our experience, the DPA is a thin vessel, whereas the plantar arteries are dominant (Figure 4). This is a less common pattern.

Foot Vessel Distribution

Two principal circulatory pathways, the dorsal and the plantar

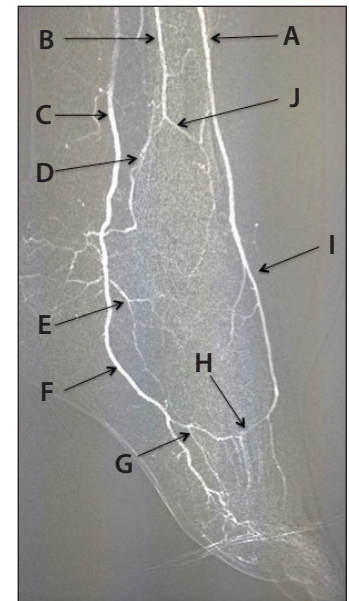


Figure 1. Vessel distribution and balanced circulation at the ankle level: ATA (A); distal PA (B); PTA (C); posterior communicating branch of the PA (D); MPA (E); LPA (F); plantar arch (G); deep perforating artery (H); DPA (I); and anterior perforating branch of the sPA (J).

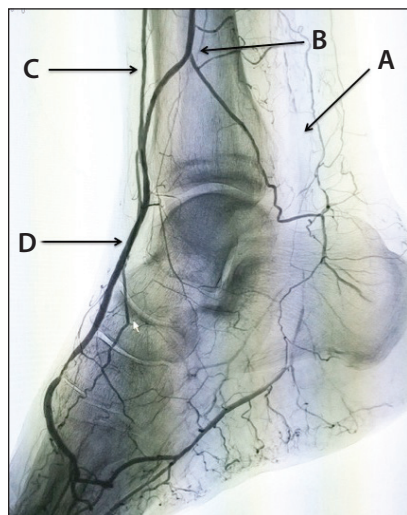


Figure 2. Anterior dominance of the PA: occluded PTA (A); dominant PA (B); hypoplastic ATA (C); DPA (D).

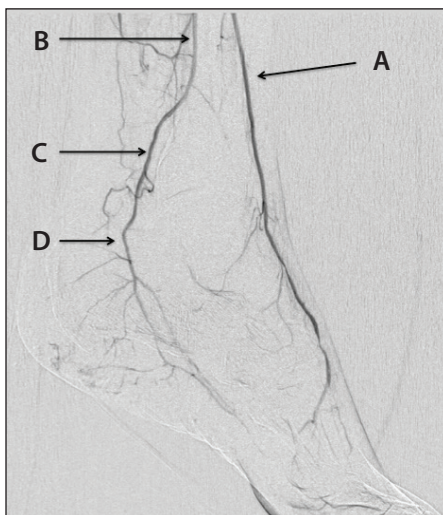


Figure 3. Posterior dominance of the PA: ATA (A); patent PA (B); retromalleolar part of the PTA (C); common plantar artery (D).

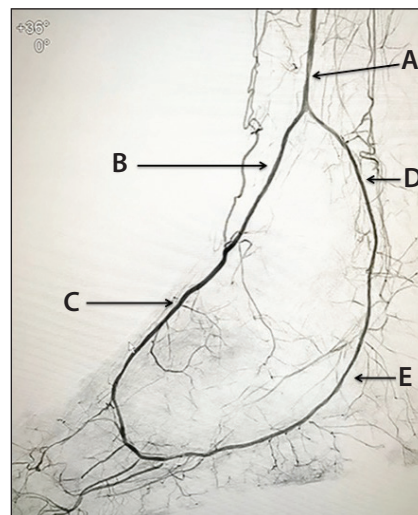


Figure 4. Single dominant PA: PA (A); anterior perforating branch of the PA (B); DPA (C); posterior branch of the PA (D); plantar arteries (E).

circulations, comprise the vascular anatomy of the foot. Both circulatory pathways, together with the PA branches, supply different regions of the foot.^{8,9}

Dorsal Distribution. The main vessel of the dorsal circulation is the DPA. The DPA branches off to the medial tarsal, lateral tarsal, and arcuate arteries. At the level of the first metatarsal space, just distal to the origin of the first metatarsal artery (which mainly supplies the first toe), the DPA curves in the plantar direction. This arterial segment, called the *deep perforating artery*, communicates with the plantar arch and plantar circulation. The dorsal circulation supplies the dorsal part of the foot and the first and second toes.

Plantar Distribution. The distal PTA, also known as the *common plantar artery*, bifurcates into the medial and lateral plantar arteries. The medial plantar artery (MPA) becomes the first plantar metatarsal artery. The lateral plantar artery (LPA) is continuous with the plantar arch where it communicates with the anterior circulation via the deep perforating artery. The plantar circulation supplies the plantar part of the foot and the third, fourth, and fifth toes.

Foot Vessel Network

The anatomic anastomosis between the dorsal and plantar circulations influences the distal runoff and the revascularization strategies. The main pedal-plantar connection is called the *pedal-plantar loop*, which consists of the anastomosis of the DPA in the first metatarsal space to the plantar arch and LPA via the deep perforating artery.

The deep pedal arch, the proximal pathway between the superficial branch of the MPA and the medial tarsal artery, is often narrow; however, it could become predominant in cases of pedal-plantar loop occlusion or forefoot amputation.

Anatomic Variability of Foot Vessel Distribution

The most frequent anatomic variants of the foot arteries have been described in the literature.¹⁰ Similar to the ankle distribution, we propose a classification of the foot distribution patterns as balanced circulation, dominant DPA, and dominant LPA. Other abnormalities include the tarsal loop and the absence of a pedal-plantar loop.

Balanced Circulation. In balanced circulation, the DPA and LPA are codominant arteries. They present at a similar diameter and communicate with each other through the plantar arch (Figure 5).

Dominant DPA. DPA dominance consists of the absence of plantar arteries or the presence of hypoplastic plantar arteries (Figure 6). In this pattern, the first metatarsal artery is supplied by the DPA.

Dominant LPA. In this variation, the DPA is absent or hypoplastic and the connection between the dorsal and plantar circulation is not present or could be supplied by thin tarsal branches. Absence of the DPA has been reported in 6% to 12% of patients (Figure 7).¹⁰

Tarsal Loop. This pattern is correlated to the absence or hypoplasia of the DPA. In this group, the tarsal artery becomes dominant and develops an anastomosis to the plantar circulation (Figure 8).

Absence of the Pedal-Plantar Loop. In this variation, the dorsal and plantar circulations are completely separate; this presentation is very rare.

Angiosomes of the Foot and Ankle

An angiosome can be defined as vascular territories of skin and underlying muscles, tendons, nerves, and bones based on segmental or distributing arteries.¹¹⁻¹³ The foot and ankle angiosomes are correlated to the principal BTK arteries, which are described within the following groups.

Dorsal angiosome. The entire dorsal part of the foot is functionally connected in a single angiosome that is

supplied by the dorsal circulation. The principal vessel in this angiosome is the DPA, which prolongs the ATA and branches off to the medial and lateral malleolar arteries, medial and lateral tarsal arteries, and arcuate artery. The DPA and its branches also supply the dorsum of the foot and toes, as well as the upper anterior perimalleolar vascularization (Figure 9).

Plantar angiosomes. The posterior and plantar circulation is supplied by the PTA, which feeds three different angiosomes. The medial calcaneal artery is the first vessel of the posterior circulation that originates from PTA; this branch supplies the medial malleolar region and the medial plantar heel (Figure 10). The angiosome supplied by the medial plantar artery includes the medial plantar instep. The medial plantar artery has a superficial branch, which perfuses the dorsum of the foot and is often connected to the anterior circulation through the medial tarsal arteries. Furthermore, its deep branch might be connected to the first plantar metatarsal artery, which supplies the first toe (Figure 11). The LPA communicates with the dorsal circulation through the plantar arch and deep perforating artery. The plantar metatarsal arteries originate from the plantar arch and feed the digital artery in the forefoot, which, in combination with the lateral plantar surface, constitutes the lateral plantar angiosome (Figures 12 and 13).

Peroneal angiosomes. At the level of the malleolus, the PA bifurcates into anterior perforating and lateral calcaneal branches, each of which supplies a specific angiosome. The anterior branch of the PA supplies the anterolateral ankle angiosome, and the calcaneal branch of the PA supplies the lateral heel angiosome (Figure 14).

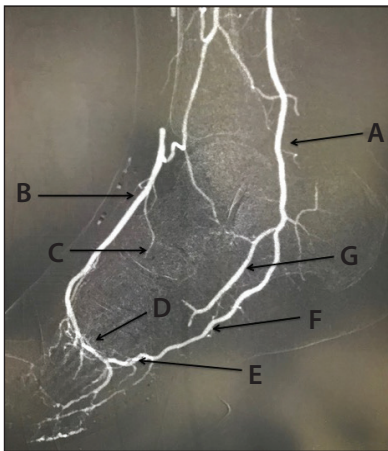


Figure 5. Balanced circulation: common plantar artery (A); DPA (B); lateral tarsal artery (C); deep perforating artery (D); plantar arch (E); LPA (F); MPA (G).

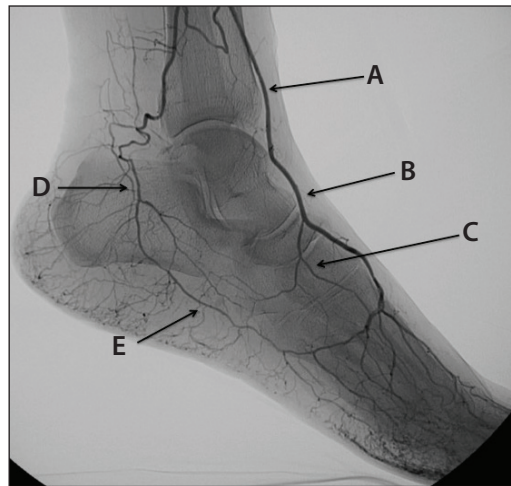


Figure 6. Dominant DPA: ATA (A); dominant DPA (B); lateral tarsal branch (C); common plantar artery (D); hypoplastic LPA (E).

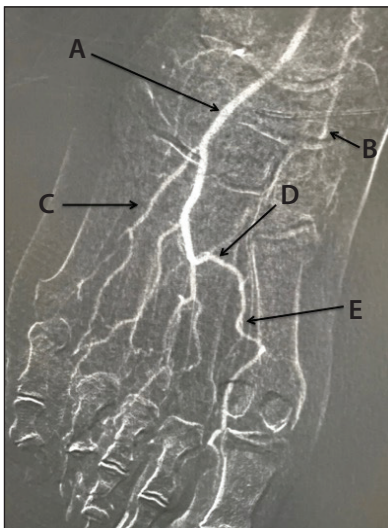


Figure 7. Dominant LPA: LPA (A); MPA (B); fifth metatarsal artery (C); plantar arch (D); first metatarsal artery (E).

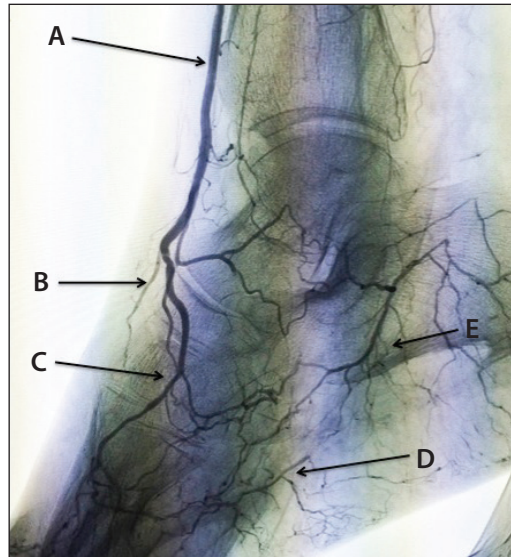


Figure 8. Tarsal loop: ATA (A); hypoplastic DPA (B); tarsal plantar loop (C); distal LPA (D); MPA (E).

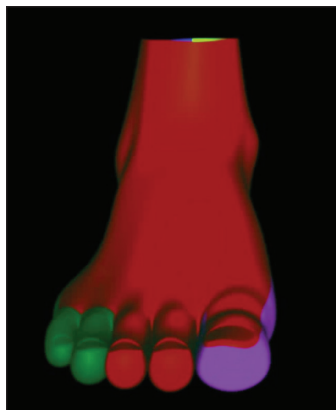


Figure 9. Anterior pedal angiosome. The dorsum of the foot is supplied by the anterior circulation (red).

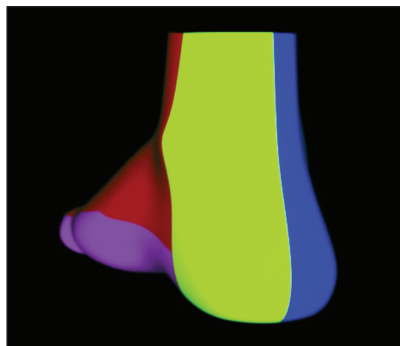


Figure 10. The medial calcaneal angiosome (yellow) through the medial calcaneal artery of the posterior circulation that originates from the PTA. This branch supplies the medial malleolar region and the medial plantar heel.




Figure 11. Medial plantar angiosome (violet) from the MPA. Its deep branch might be connected to the first plantar metatarsal artery, which supplies the first toe.

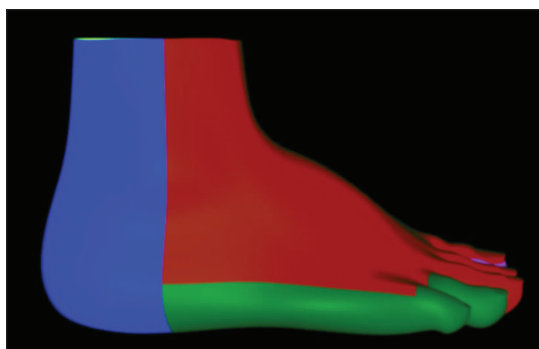


Figure 12. The LPA angiosome (green), which feeds the lateral part of the foot and the fourth and fifth toes.

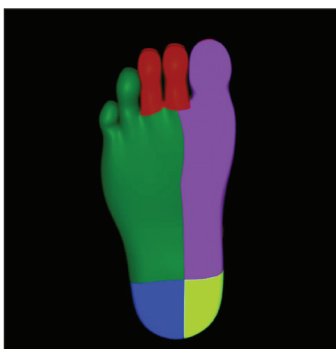

Figure 13. Overview of all the plantar angiosomes: lateral plantar angiosome (green); medial plantar angiosome (violet); medial calcaneal angiosome (yellow) from the PTA; lateral calcaneal angiosome (blue) from the PA.

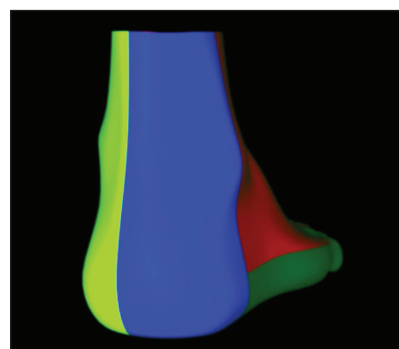


Figure 14. The lateral calcaneal angiosome (blue) from the PA, which feeds the external part of the heel and the external malleolar region.

TARGETS IN CLI REVASCULARIZATION

Revascularization is a mainstay therapy in patients with CLI because reestablishing an adequate blood supply to the wound is essential for healing and avoiding major amputation.^{14,15} The targets of revascularization can be summarized by two concepts: “complete” and “wound-related artery” revascularization.

Complete Revascularization

Peregrin et al analyzed the clinical success of percutaneous revascularization in patients with diabetic CLI based on the number of patent leg vessels.¹⁶ They demonstrated that “complete” revascularization is better than “partial” revascularization, as the limb salvage rate at 1 year increased from 56% without direct blood flow to the foot (0 leg

vessels open), to 73%, 80%, and 83% with one, two, or three leg vessels open, respectively. Faglia et al also verified that angioplasty of tibial arteries had a better outcome than angioplasty of the PA.¹⁷ Healing is a blood flow-dependent phenomenon, and the first principle guiding our revascularization strategy must be providing the foot with the best possible blood supply. This statement is particularly true in patients with extensive tissue damage and infection, where the lesion is not confined into a single angiosome space but spreads over contiguous foot spaces and angiosomes.

Wound-Related Artery Revascularization

In the last several years, the concept of angiosome-oriented revascularization has gained a wide consent

because it was clearly demonstrated that successful revascularization of the artery directly feeding the wound region leads to a higher rate of limb salvage and wound healing.^{13,18-24} Direct revascularization has a different value that depends on the capacity of the outflow distribution network. Varela et al demonstrated that the restoration of blood flow to the wound through distal collateral vessels (pedal and peroneal branches) could provide similar results to those obtained through its specific source artery in terms of healing and limb salvage.²⁵ On the other hand, patients with diffuse disease of the small distal vessels (patients with diabetes and end-stage renal disease) could require direct blood flow to the wound-related artery for healing.²⁶

The wound-related artery concept has particular importance in case of surgical wounds: forefoot amputations (rays, transmetatarsal, Lisfranc, Chopart amputations) often interrupt the perforating metatarsal branches connecting the dorsum and the plantar vessels, separating the two systems. In these cases, revascularization should supply the surgical flap, supporting the surgical wound healing. Foot vessel evaluation and treatment represent the key points in the revascularization strategy in CLI patients (Figure 15).

TREATMENT STRATEGY IN BTK VESSELS

The first step in percutaneous recanalization is to successfully cross the vascular lesions. Recanalization can be performed using antegrade and retrograde techniques (Figure 16). To date, there are few studies regarding angioplasty and stenting of the BTK arteries.²⁷⁻³⁸ Nonetheless, these studies have proven the principle, safety, and feasibility of using standard subintimal or intraluminal recanalization techniques in the pedal and plantar arteries for limb salvage in cases of CLI.³⁷ Plain old balloon angioplasty must be considered the standard technique BTK; in foot vessels, stenting is contraindicated due to the high burden of mechanical trauma that can collapse and break the stent structure.³⁷ The pedal-plantar loop technique and retrograde puncture of the distal forefoot vessels can increase the success rate of percutaneous revascularization of the foot vessels.

Antegrade Recanalization

The endoluminal approach should be the first choice in every type of lesion, because it is often possible to cross even long BTK lesions by maintaining the endoluminal position. It is also the preferred approach in calcified vessels. Our choice of wire is usually a shapeable-tip, 0.014-inch, hydrophilic guidewire (Savion FLX™ Guidewire, Boston Scientific Corporation) and support catheter or balloon catheter (Coyote™ ES Balloon Catheter, Boston Scientific Corporation). When traditional endoluminal revascularization fails, we then change our strategy according to the vessel lesion. In the case

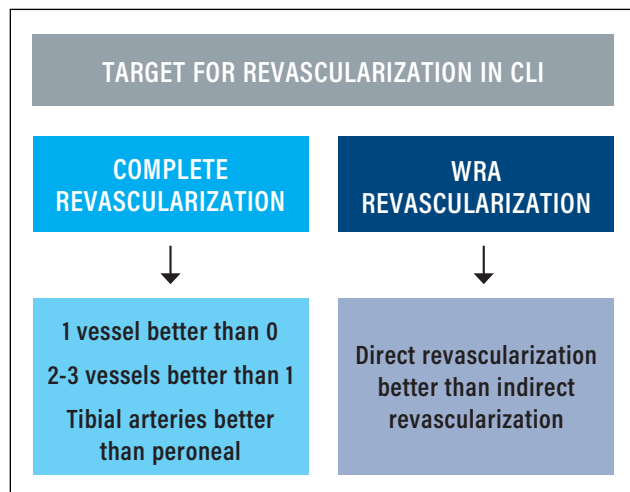


Figure 15. Flowchart of the target for CLI revascularization. WRA, wound-related artery.

of calcified vessels or short-length obstructions, we prefer to pursue the endoluminal approach using the “parallel wire” technique and advanced crossing wires (Victory™ Guidewire, Boston Scientific Corporation).

In case of a long chronic total occlusion (CTO) or a noncalcified or spot-calcified vessel, we shift to a subintimal approach. The subintimal approach can be safely and effectively used to achieve a successful revascularization. It is usually performed using a 0.035- or 0.018-inch V-18™ ControlWire™ Guidewire (Boston Scientific Corporation) in the tibial vessels and a 0.018-inch V-18™ ControlWire™ Guidewire or 0.014-inch Savion FLX™ Guidewire in the foot arteries, as well as a support catheter (Rubicon™ Support Catheter, Boston Scientific Corporation) or balloon catheter (Sterling™ Balloon Catheter [Boston Scientific Corporation], Coyote™ ES). It is usually performed by pushing the

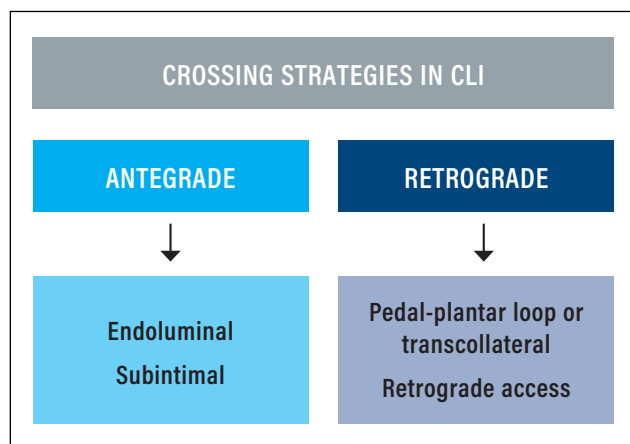


Figure 16. Flowchart of the technical strategies for crossing in CLI.

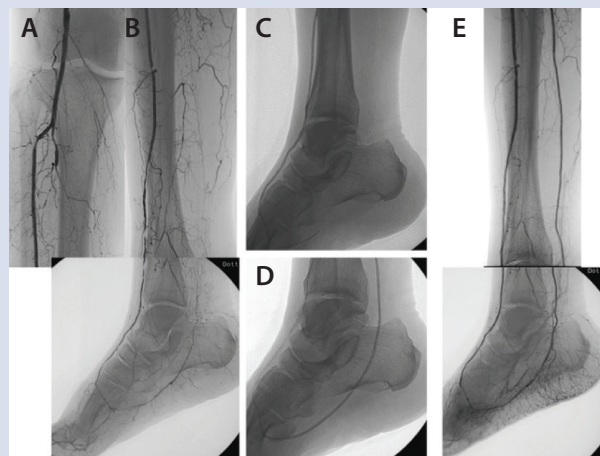
CASE REPORT

A 73-year-old man presented with CLI of his right leg and ulceration on the fourth/fifth toes and metatarsophalangeal joint. He also had a history of diabetes, hypertension, and dyslipidemia. Antegrade access was achieved in the common femoral artery, and diagnostic angiography showed BTK/BTA arterial disease, with multiple stenoses in the anterior tibial artery and occlusion of the peroneal and posterior tibial arteries. Further arterial disease was found in the lateral plantar artery as well (A, B).

We decided on an endoluminal and subintimal crossing approach with the Savion FLX™ Guidewire, which was supported with a 2- X 40-mm Coyote™ ES Balloon Catheter. This allowed us to reach and reenter the lateral plantar artery and safely navigate the plantar arch. Finally, balloon angioplasty was performed using a 2.5- X 220-mm Coyote™ ES Balloon Catheter. Endoluminal angioplasty was also performed in the anterior tibial and dorsalis pedis arteries with the same Savion FLX™ Guidewire and 2.5- X 220-mm Coyote™ ES Balloon Catheter (C, D).

The final control angiogram showed direct blood flow through the anterior and posterior tibial arteries, with direct blood flow for the dorsal and plantar circulation (E).

Due to its structure, the Savion FLX™ Guidewire allows us to combine endoluminal and subintimal crossing, making the loop-shape tip without damaging the tip of the wire, and after reentry, straightening the wire again to allow continuous navigation of the patent distal vessel.



guidewire to create a loop shape and following the loop with a support catheter to dissect the subintimal space until the reentry point. At the reentry point, the main imperative is to avoid damaging the healthy distal vessels. We manage this by pushing the looped wire toward the patent distal vessel in a location where the patent distal lumen is straight and free from calcium. In the case of a calcified vessel, poor landing zone, or patent distal vessel that is suitable for a bypass, we preferred to approach it using an advanced crossing wire (Victory™ Guidewire) or retrograde approach.

Pedal-Plantar Loop Technique

This technical strategy aims to restore direct arterial inflow from both principal circulatory pathways of the foot, achieving complete BTK revascularization, but it can also be used to succeed in wound-related artery recanalization, crossing through the opposite patent circulatory pathway to obtain retrograde recanalization of the occluded foot vessel. It is based on the wiring and balloon tracking through the plantar arch and creating a loop from the dorsal to the plantar circulation of the foot (or vice versa).^{27,28}

This technical strategy has been thoroughly tested and proven to be useful for recanalization of patients with CLI due to BTK and below-the-ankle (BTA) atherosclerotic disease,³⁰ providing a high rate of acute success. Before applying the loop technique, the operator must carefully

analyze the vascular anatomy of the foot network. It is essential to emphasize that direct blood flow through one tibial artery (ATA or PTA) with a good distal distribution system into the foot vessels can be a satisfactory and conclusive result of revascularization for the majority of the patients.

Retrograde Percutaneous Puncture

This technical strategy is considered when antegrade recanalization fails and consists of a retrograde percutaneous puncture of the distal patent vessel followed by retrograde wiring with the objective to achieve patency of the proximal lumen of the target artery.^{35,38-41} Retrograde recanalization in BTK arteries can be performed through multiple different access sites. Specifically, to perform percutaneous retrograde distal access, we offer the following suggestions:

- **Choose the puncture site.** Accurate angiographic evaluation using the correct radiological projection is necessary for tibial and foot artery puncture.
- **Avoid spasms.** Spasms can compromise the puncture and wiring of the small vessels, and pharmacological support is essential. The use of a vasodilator (nitroglycerine, verapamil) is mandatory; it can be administered intra-arterially, as close as possible to the access site and, together with lidocaine, into the subcutaneous tissue around the needle entry site.

- **Puncture technique.** The puncture is performed with a 21-gauge needle under fluoroscopic or ultrasound guidance.
- **Retrograde crossing strategy.** We generally prefer to use a 0.018-inch V-18™ ControlWire™ Guidewire after the puncture due to its enhanced support. However, the Savion DLVR™ Guidewire (Boston Scientific Corporation) is also an option as a designated wire for support and exchange due to its 0.014-inch platform and maximum rail support. The chosen guidewire is used in combination with a low-profile support catheter, which is very useful for wire support, orientation, and exchange.
- **Reconnection with the antegrade approach.** After retrograde crossing of the occluded vessel and reaching the proximal patent arterial segment, the aim is to perform the rendezvous with the antegrade catheter.³⁹⁻⁴¹ When the rendezvous is achieved, the retrograde wire is externalized at the groin level. After reversion of the approach, final hemostasis is obtained by advancing a balloon catheter beyond the puncture site and inflating it to nominal pressure.

CONCLUSION

The first step in treating PAD in BTK or BTA anatomy is gaining knowledge of the vascular anatomy of the tibial and foot vessels, as well as the most frequent anatomic variations and the angiosome concept. The target for CLI should change in relation to the clinical baseline condition, as well as to the vascular anatomy. In regard to our toolbox, the V-18™ ControlWire™ Guidewire is preferred for an endoluminal subintimal approach in the BTK arteries, the Savion FLX™ Guidewire can be used in an endoluminal subintimal approach in the BTA vessels, and the Savion DLVR™ Guidewire is helpful for increasing support and in delivering devices BTK/BTA.

We have many techniques that support us in successful approaches to the distal arteries, and by combining these in the proper way and following clinical needs, we can achieve excellent results, saving legs and lives. ■

12. Taylor GI, Pan WR. Angiosomes of the leg: anatomic study and clinical implications. *Plast Reconstr Surg*. 1998;102:599-616.
13. Attinger CE, Evans KK, Bulan E, et al. Angiosomes of the foot and ankle and clinical implications for limb salvage: reconstruction, incisions, and revascularization. *Plast Reconstr Surg*. 2006;117(7 suppl):261S-293S.
14. Hinchliffe RJ, Andros G, Apelqvist J, et al. A systematic review of the effectiveness of revascularization of the ulcerated foot in patients with diabetes and peripheral arterial disease. *Diabetes Metab Res Rev*. 2012;28(suppl 1):179-217.
15. Norgren L, Hiatt WR, Dormandy JA, et al; TASC II Working Group. Inter-Society Consensus for the Management of Peripheral Arterial Disease (TASC II). *J Vasc Surg*. 2007;45:55-67.
16. Peregrin JH, Kozmar B, Kovac J, et al. PTA of infrapopliteal arteries: long-term clinical follow-up and analysis of factors influencing clinical outcomes. *Cardiovasc Intervent Radiol*. 2010;33:720-725.
17. Faglia E, Clerici G, Querisi J, et al. When is a technically successful peripheral angioplasty effective in preventing above-the-ankle amputation in diabetic patients with critical limb ischemia? *Diabet Med*. 2007;24:823-829.
18. Iida O, Nanto S, Uematsu M, et al. Importance of the angiosome concept for endovascular therapy in patients with critical limb ischemia. *Catheter Cardiovasc Interv*. 2010;75:830-836.
19. Iida O, Soga Y, Hirano K, et al. Long-term results of direct and indirect endovascular revascularization based on the angiosome concept in patients with critical limb ischemia presenting with isolated below-the-knee lesions. *J Vasc Surg*. 2012;55:363-370.
20. Alexandrescu V, Hubermont G. The challenging topic of diabetic foot revascularization: does the angiosome-guided angioplasty may improve outcome. *J Cardiovasc Surg*. 2012;53:3-12.
21. Alexandrescu V, Söderström M, Venermo M. Angiosome theory: fact or fiction? *Scand J Surg*. 2012;101:125-131.
22. Alexandrescu V, Vincent G, Azdad K, et al. A reliable approach to diabetic neuroischemic foot wounds: below-the-knee angiosome-oriented angioplasty. *J Endovasc Ther*. 2011;18:376-387.
23. Alexandrescu VA, Hubermont G, Phillips Y, et al. Selective primary angioplasty following an angiosome model of reperfusion in the treatment of Wagner 1-4 diabetic foot lesions: practice in a multidisciplinary diabetic limb service. *J Endovasc Ther*. 2008;15:580-593.
24. Neville RF, Attinger CE, Bulan EJ, et al. Revascularization of a specific angiosome for limb salvage: does the target artery matter? *Ann Vasc Surg*. 2009;23:367-373.
25. Varela C, Acín F, de Haro J, et al. The role of foot collateral vessels on ulcer healing and limb salvage after successful endovascular and surgical distal procedures according to an angiosome model. *Vasc Endovasc Surg*. 2010;44:654-660.
26. Azuma N, Uchida H, Kokubo T, et al. Factors influencing wound healing of critical ischaemic foot after bypass surgery: is the angiosome important in selecting bypass target artery? *Eur J Vasc Endovasc Surg*. 2012;43:322-328.
27. Fusaro M, Dalla Paola L, Biondi-Zoccai G. Pedal-plantar loop technique for a challenging below-the-knee chronic total occlusion: a novel approach to percutaneous revascularization in critical lower limb ischemia. *J Invasive Cardiol*. 2007;19:E34-37.
28. Fusaro M, Dalla Paola L, Brigato C, et al. Plantar to dorsalis pedis artery subintimal angioplasty in a patient with critical foot ischemia: a novel technique in the armamentarium of the peripheral interventionist. *J Cardiovasc Med (Hagerstown)*. 2007;8:977-980.
29. Kawarada O, Yokoi Y. Dorsalis pedis artery stenting for limb salvage. *Catheter Cardiovasc Interv*. 2008;71:976-982.
30. Manzi M, Fusaro M, Ceccacci T, et al. Clinical results of below-the-knee intervention using pedal-plantar loop technique for the revascularization of foot arteries. *J Cardiovasc Surg (Torino)*. 2009;50:331-337.
31. Zhu YQ, Zhao JG, Liu F, et al. Subintimal angioplasty for below-the-ankle arterial occlusions in diabetic patients with chronic critical limb ischemia. *J Endovasc Ther*. 2009;16:604-612.
32. Abdelhamid MF, Davies RS, Rai S, et al. Below-the-ankle angioplasty is a feasible and effective intervention for critical leg ischaemia. *Eur J Vasc Endovasc Surg*. 2010;39:762-768.
33. Zhu YQ, Zhao JG, Li MH, et al. Retrograde transdorsal-to-plantar or transplantar-to-dorsal intraluminal re-entry following unsuccessful subintimal angioplasty for below-the-ankle arterial occlusion. *J Endovasc Ther*. 2010;17:712-721.
34. Kawarada O, Yokoi Y, Higashimori A, et al. Stent-assisted below-the-ankle angioplasty for limb salvage. *J Endovasc Ther*. 2011;18:32-42.
35. Palena LM, Manzi M. Extreme below-the-knee interventions: retrograde transmetatarsal or transplanter arch access for foot salvage in challenging cases of critical limb ischemia. *J Endovasc Ther*. 2012;19:805-811.
36. Manzi M, Palena LM, Brocco E. Is digital arteries recanalization useful to preserve the foot functionality and avoid toes amputation, after pedal recanalization? *Clinical results*. *J Cardiovasc Surg (Torino)*. 2012;53:61-68.
37. Katsanos K, Diamantopoulos A, Spiliopoulos S, et al. Below-the-ankle angioplasty and stenting for limb salvage: anatomical considerations and long-term outcomes. *Cardiovasc Intervent Radiol*. 2013;36:926-935.
38. Palena LM, Brocco E, Manzi M. The clinical utility of below-the-ankle angioplasty using "transmetatarsal artery access" in complex cases of CLI. *Catheter Cardiovasc Interv*. 2014;83:123-129.
39. Spinosa DJ, Leung DA, Hathun NL, et al. Simultaneous antegrade and retrograde access for subintimal recanalization of peripheral arterial occlusion. *J Vasc Interv Radiol*. 2003;14:1449-1454.
40. Spinosa DJ, Hathun NL, Bissonette EA, et al. Subintimal arterial flossing with antegrade-retrograde intervention (SAFARI) for subintimal recanalization to treat chronic critical limb ischemia. *J Vasc Interv Radiol*. 2005;16:37-44.
41. Gandini R, Pipitone V, Stefanini M, et al. The "Safari" technique to perform difficult subintimal infragenicular vessels. *Cardiovasc Intervent Radiol*. 2007;30:469-473.

Luis Mariano Palena, MD

Interventional Radiology Unit
Foot & Ankle Clinic
Policlinico Abano Terme
Abano Terme (PD), Italy
marianopalena@hotmail.com
Disclosures: None.

Marco Manzi, MD

Interventional Radiology Unit
Foot & Ankle Clinic
Policlinico Abano Terme
Abano Terme (PD), Italy
Disclosures: None.

1. Brazeau NF, Pinto EG, Harvey HB, et al. Critical limb ischemia: an update for interventional radiologists. *Diagn Interv Radiol*. 2013;19:173-180.
2. Egorova NN, Guilleme S, Gelijns A, et al. An analysis of the outcomes of a decade of experience with lower extremity revascularization including limb salvage, lengths of stay, and safety. *J Vasc Surg*. 2010;51:878-885.
3. Bashir R, Cooper CJ. Evaluation and medical treatment of peripheral arterial disease. *Curr Opin Cardiol*. 2003;18:436-443.
4. Spiliopoulos S, Katsanos K, Karnabatidis D, et al. Cryoplasty versus conventional balloon angioplasty of the femoropopliteal artery in diabetic patients: long-term results from a prospective randomized single-center controlled trial. *Cardiovasc Intervent Radiol*. 2010;33:929-938.
5. Graziani L, Silvestro A, Bertone V, et al. Vascular involvement in diabetic subjects with ischemic foot ulcer: a new morphologic categorization of disease severity. *Eur J Vasc Endovasc Surg*. 2007;33:453-460.
6. Gray BH, Grant AA, Kalbaugh CA, et al. The impact of isolated tibial disease on outcomes in the critical limb ischemic population. *Ann Vasc Surg*. 2010;24:349-359.
7. Sadek M, Ellozy SH, Turnbull IC, et al. Improved outcomes are associated with multilevel endovascular intervention involving the tibial vessels compared with isolated tibial intervention. *J Vasc Surg*. 2009;49:638-643; discussion 643-644.
8. Alson MD, Lang EV, Kaufman JA. Pedal arterial imaging. *J Vasc Interv Radiol*. 1997;8(1 pt 1):9-18.
9. Manzi M, Cester G, Palena LM, et al. Vascular imaging of the foot: the first step toward endovascular recanalization. *Radiographics*. 2011;31:1623-1636.
10. Yamada T, Głowiczki P, Bower TC, et al. Variations of the arterial anatomy of the foot. *Am J Surg*. 1993;166:130-135; discussion 135.
11. Graziani L, Silvestro A, Monge L, et al. Transluminal angioplasty of peroneal artery branches in diabetics: initial technical experience. *Cardiovasc Intervent Radiol*. 2008;31:49-55.

CASE REPORT

Utilizing IVUS Below the Knee

The importance of invasive imaging to guide treatment decisions and improve outcomes.

BY STEVE HENAO, MD, FACS, FACC

It should be considered among the best practices of endovascular therapy to reserve intervention of diseased tibial arteries for critical limb ischemia (CLI) cases. This should be an individualized decision based on the assessment of an available venous conduit for possible bypass options, patient comorbidities, lesion morphology, and tissue loss characteristics.¹ This challenging subset of patients exhibits lower procedural success rates due to increased lesion complexity (eg, plaque length, chronic total occlusions [CTOs], calcific wall involvement).² For the vascular specialist, procedural success should be seen as a high-stakes endeavor because failure to revascularize is more likely to lead to major amputation or death during follow-up.³

The optimal regimen for tibial interventions in patients with CLI has yet to be defined. Angioplasty is still considered the primary therapeutic modality for the infrageniculate distribution, whereas antiproliferative strategies are still being evaluated and are not approved for use in the United States at this time. Atherectomy is considered a reasonable strategy to optimize the vessel for percutaneous transluminal angioplasty (PTA) and minimize dissection, especially within the calcific pathology seen in these patients.⁴ Strategic evaluation of the arterial target to ensure true lumen position, assess plaque morphology, and obtain the precise vessel diameter using intravascular ultrasound (IVUS) has been extrapolated from results seen in the coronary circulation,⁵ and promising data regarding these benefits in the setting of peripheral artery disease continue to evolve.

CASE REPORT

A 57-year-old man receiving appropriate wound care and nutrition presented to the limb preservation service with a nonhealing left fourth digit amputation of the foot, sustained 2 months prior to our consultation. He had a 40 pack-year smoking history, as well as chronic renal insufficiency (stage 3B), type 2 diabetes, hypertension, and dyslipidemia. Our podiatry team performed arterial duplex examination of his lower extremity, which demonstrated monophasic tibiopedal flow and a toe-brachial index of 0.2. Ultrasound vein mapping obtained at the time

of his initial visit demonstrated a previous vein harvest for a coronary artery bypass graft on the ipsilateral limb and an inadequate vein < 2 mm in diameter within the contralateral leg. With a diagnosis of CLI, absence of a usable conduit, and list of comorbidities, the patient was offered endovascular evaluation and therapy via a right retrograde femoral approach. His renal insufficiency was also taken into consideration, so carbon dioxide (CO₂) was planned for use as the principal contrast medium.

Within 48 hours, the patient was taken to the hybrid operating room and placed supine on the table, where conscious sedation was administered. Ultrasound-guided right femoral access was achieved followed by placement of a 0.035-inch wire and a 6-F retrograde sheath. An Imager™ II Angiographic Catheter (Boston Scientific Corporation) was advanced into the abdominal aorta under fluoroscopic guidance. Digital subtraction CO₂ angiography was then performed. This demonstrated a patent aorta and bilateral iliac systems. Selective catheterization of the left common and external iliac arteries was then performed. CO₂ angiography performed at this level demonstrated patency of the common femoral, profunda femoral, superficial femoral, and popliteal arteries. Below the knee, imaging demonstrated intermittent CTOs of all three tibial vessels (Figure 1). There was a common trunk joining the anterior tibial artery and the peroneal artery, with a posterior tibial artery arising directly from the popliteal artery.

With the absence of inline flow to the foot appearing to be directly related to the patient's ischemic situation, intervention was warranted (Figure 2). A 7-F, 90-cm sheath was then placed up and over the bifurcation and positioned at the P2 segment of the popliteal artery. A Savion FLX™ Guidewire (Boston Scientific Corporation) and Rubicon™ Support Catheter (Boston Scientific Corporation) were then directed into the CTO of the posterior tibial artery, where an exchange was made for a 0.014-inch RotaWire™ for use with the Rotablator™ Rotational Atherectomy System (Boston Scientific Corporation).

Prior to this, the nature of the plaque morphology as well as the relative sizing of the tibial vasculature was determined using the Opticross™ 18 Peripheral Imaging Catheter (Boston




Figure 1. CO₂ angiography of the infrageniculate circulation demonstrating CTOs of all three tibiopedal arteries.

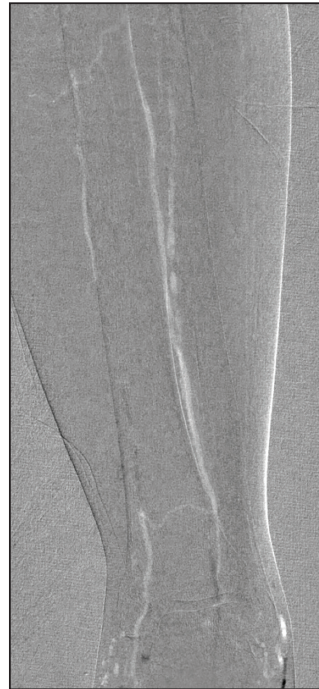

Figure 2. CO₂ angiography showing distal reconstitution of the posterior tibial artery representing the dominant supply to the foot.

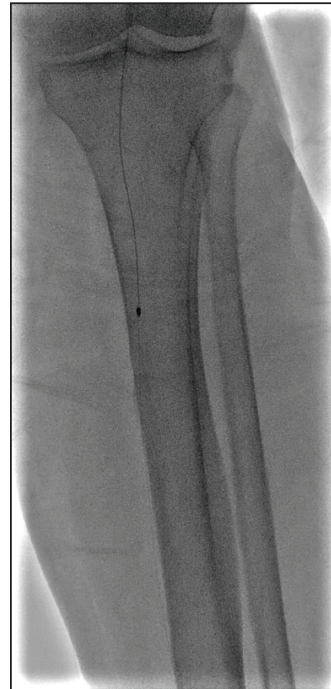


Figure 3. Rotational atherectomy of the tibiopedal arteries after IVUS assessment.

and below the knee (Figures 5 and 6). This demonstrated a robust three-vessel runoff with excellent flow into the foot, predominantly via the posterior tibial artery. Upon completion of successful therapy, the sheath was removed over a 0.035-inch wire, and a closure device was successfully deployed at the right femoral access site. The patient tolerated the procedure nicely and was discharged home after several hours of observation, intravenous fluids, and bed rest. Optimal wound care, off-loading, and smoking cessation efforts were continued, with improved healing seen at follow-up evaluation.

Scientific Corporation) for IVUS, which demonstrated a 3.5-mm overall diameter of the posterior tibial artery. A 2-mm burr was selected for plaque modification of the critically stenosed segments using rotational atherectomy, followed by angioplasty using the selected 3.5-mm-diameter PTA balloon at low pressure for 3-minute intervals (Figure 3). A follow-up CO₂ angiogram demonstrated no evidence of extravasation, injury, or dissection. Selective catheterization of the anterior tibial artery was performed, using similar maneuvers for rotational atherectomy positioning. Plaque modification was performed with rotational atherectomy, followed by postdilation directed by IVUS, which demonstrated a 4- to 5-mm range in diameter (Figure 4). Both PTA balloon sizes were included in the treatment of this vessel, with a completion CO₂ angiogram demonstrating excellent flow through the system. To finalize the procedure, selective catheterization of the peroneal artery was then performed. Rotational atherectomy was performed again in this vessel, in which IVUS had demonstrated a relative size of 3.5 mm and thus dictated PTA balloon selection.

After treatment of all three vessels, a total of 10 mL of iodinated contrast was used for completion imaging to provide granular detail of the flow to the foot, lower leg,

DISCUSSION

It has been established that angiography alone provides luminal characteristics of the peripheral arteries, yet yields very little information on the true extent of the underlying plaque burden, objective knowledge of morphology, or the true size of the entire vessel.⁶ A similar pattern has been noted in the coronary circulation, where IVUS use in this territory has yielded additional information for the operator that may result in a change in procedural strategy in up to 74% of patients, requiring placement of larger or longer devices or additional poststent dilatation because of incomplete expansion or incomplete stent apposition and thus leading to improved outcomes in percutaneous coronary intervention.⁵

Recent studies have also shown better outcomes in peripheral interventions with IVUS use. A meta-analysis of 13 studies composed of more than 2,250 patients demonstrated a significant difference in amputation rates and frequency of reinterventions favoring the use of IVUS.⁷ Another study including over 90,000 patients demonstrated significantly lower postprocedural complications, lower amputation rates, and a nonsignificant increase in hospitalization costs with IVUS use.⁸

Percutaneous interventions to correct tibial occlusive lesions in patients with CLI warrant the highest level of

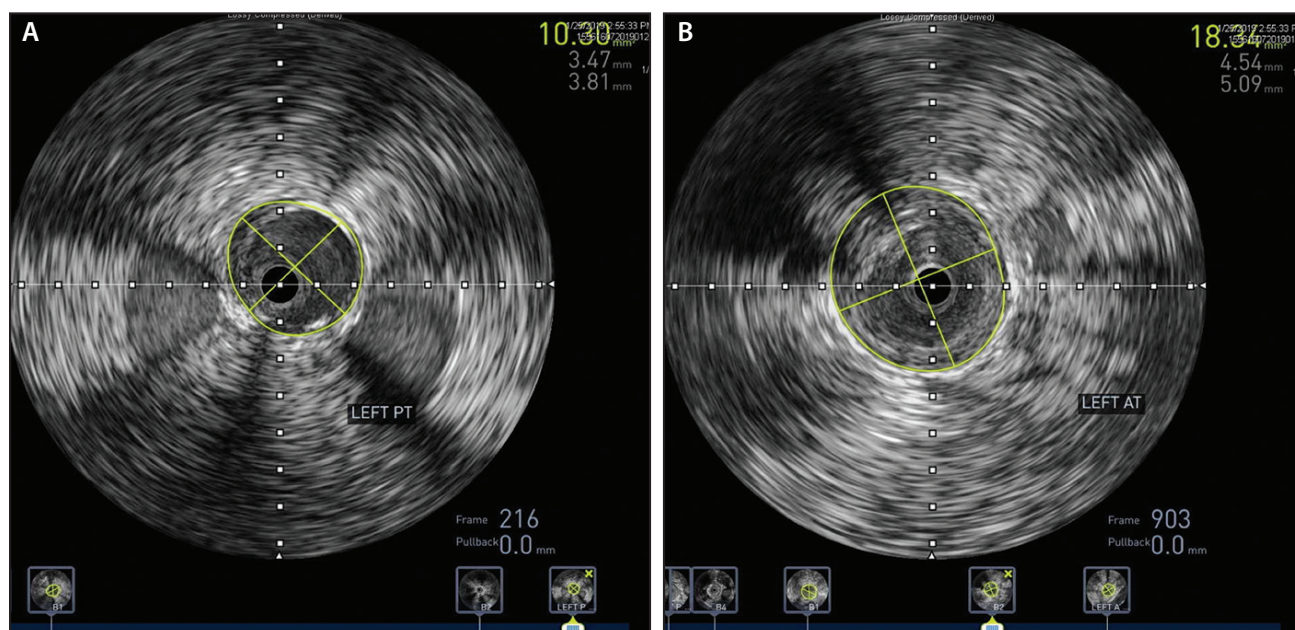


Figure 4. IVUS interrogation of the posterior tibial (A) and anterior tibial (B) arteries demonstrating a larger than expected diameter, influencing device size selection for PTA.

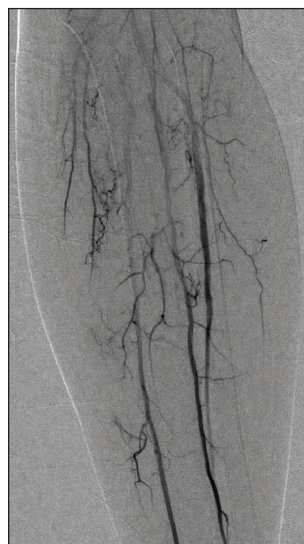

Figure 5. Completion angiography with contrast demonstrating restoration of robust three-vessel tibiopedal flow.

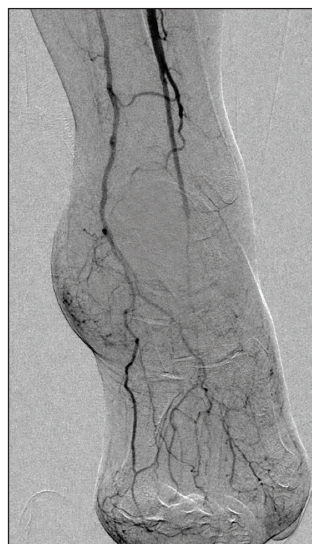

Figure 6. Three-vessel runoff into the ankle and foot.

scrutiny available to optimize outcomes. Unfortunately, concern over reimbursement has discouraged the widespread use of IVUS. This has been recently addressed with the addition of two new bundled codes (as of 2016) for noncoronary IVUS (37252, 37253). In the case presented here, a typical treatment regimen based on an average tibial size of 2 to 3 mm from angiographic

assessment alone would have led to significant undersizing and inferior outcomes. Vascular specialists should consider this imaging modality as an important and effective adjunct to help plan complex interventions more precisely in this challenging patient population. ■

1. Armstrong EJ, Alam S, Henao S, et al. Multidisciplinary care for critical limb ischemia: current gaps and opportunities for improvement. *J Endovasc Ther.* 2019;26:199-212.
2. Baumann F, Engelberger RP, Willenberg T, et al. Infrapopliteal lesion morphology in patients with critical limb ischemia: implications for the development of anti-restenosis technologies. *J Endovasc Ther.* 2013;20:149-156.
3. Singh GD, Brinza EK, Hildebrand J, et al. Midterm outcomes after infrapopliteal interventions in patients with critical limb ischemia based on the TASC II classification of below-the-knee arteries. *J Endovasc Ther.* 2017;24:321-330.
4. Mustapha JA, Diaz-Sandoval LJ, Saab F. Infrapopliteal calcification patterns in critical limb ischemia: diagnostic, pathologic and therapeutic implications in the search for the endovascular holy grail. *J Cardiovasc Surg (Torino).* 2017;58:383-401.
5. Witzensbichler B, Maehara A, Weisz G, et al. Relationship between intravascular ultrasound guidance and clinical outcomes after drug-eluting stents: the assessment of dual antiplatelet therapy with drug-eluting stents (ADAPT-DES) study. *Circulation.* 2014;129:463-470.
6. Kashyap VS, Pavkov ML, Bishop PD, et al. Angiography underestimates peripheral atherosclerosis: lumenography revisited. *J Endovasc Ther.* 2008;15:117-125.
7. Makris GC, Chrysafi P, Little M, et al. The role of intravascular ultrasound in lower limb revascularization in patients with peripheral arterial disease. *Int Angiol.* 2017;36:505-516.
8. Panaich SS, Arora S, Patel N, et al. Intravascular ultrasound in lower extremity peripheral vascular interventions: variation in utilization and impact on in-hospital outcomes from the nationwide inpatient sample (2006-2011). *J Endovasc Ther.* 2016;23:65-75.

Steve Henao, MD, FACS, FACC

Vascular Surgery and Vascular Interventional Radiology
New Mexico Heart Institute
Albuquerque, New Mexico
steveh@nmhi.com

Disclosures: Speaker's bureau for Abbott Vascular, Boston Scientific Corporation, Endologix, Inc.; medical/scientific advisory board for Boston Scientific Corporation, Abbott Vascular.

CASE REPORTS

Use of Atherectomy + DCB in CLI

Tips and tricks to achieve optimal results in patients with complex disease.

BY TIBOR BALÁZS, MD

Critical limb ischemia (CLI) as a manifestation of peripheral artery disease (PAD) is associated with significant health issues and severe disabilities. It is a major worldwide cause of morbidity and, in cases when it takes a limb-threatening course, mortality.¹ A wide range of clinical signs can occur in PAD and CLI, from intermittent claudication to limb-threatening ischemia, manifesting with rest pain, nonhealing wounds, and gangrene. The primary goal of treatment is the reestablishment of pulsatile, straight-line flow to the foot. In recent years, major advancements have been made in the field of endovascular therapy (EVT), and it is now considered a safe and feasible treatment option for limb salvage and wound healing.¹

This article highlights the importance of vessel preparation in complex lesions and emphasizes the unique role of percutaneous atherectomy with adjunctive drug-coated balloon (DCB) therapy in CLI treatment. The philosophy of percutaneous atherectomy is based on luminal gain by reduction/modification of the atherosclerotic plaque, changing vessel compliance to reduce dissections, vessel barotrauma, and bailout stenting. The “leave-nothing-behind” strategy has been

gaining popularity, with the aim of leaving the treated vessel intact for potential future treatments without permanent metallic stents, as well as to avoid potential stent-related problems.²

COMPLEX CALCIFIED LESIONS AND CTOs

Complex lesions and chronic total occlusions (CTOs) are very often associated with arterial wall calcifications, which could be severe and diffuse. These calcifications include different morphologies like thrombus or fibrous tissue and affect the femoropopliteal (FP) and below-the-knee (BTK) vessels. Although plain old balloon angioplasty has shown favorable periprocedural results, the previously mentioned factors limit the immediate periprocedural success, and the high restenosis rates and recurrent clinical symptoms make EVT challenging.

Dedicated drug-eluting technologies, such as drug-eluting stents and DCBs, have emerged to improve the long-term patency rates. Although good outcomes have been seen with DCBs in the superficial femoral artery (SFA) and popliteal artery (PA), when the artery is very calcified (Figure 1A) with almost complete or complete circumferential distribution of calcium (360°), the drug

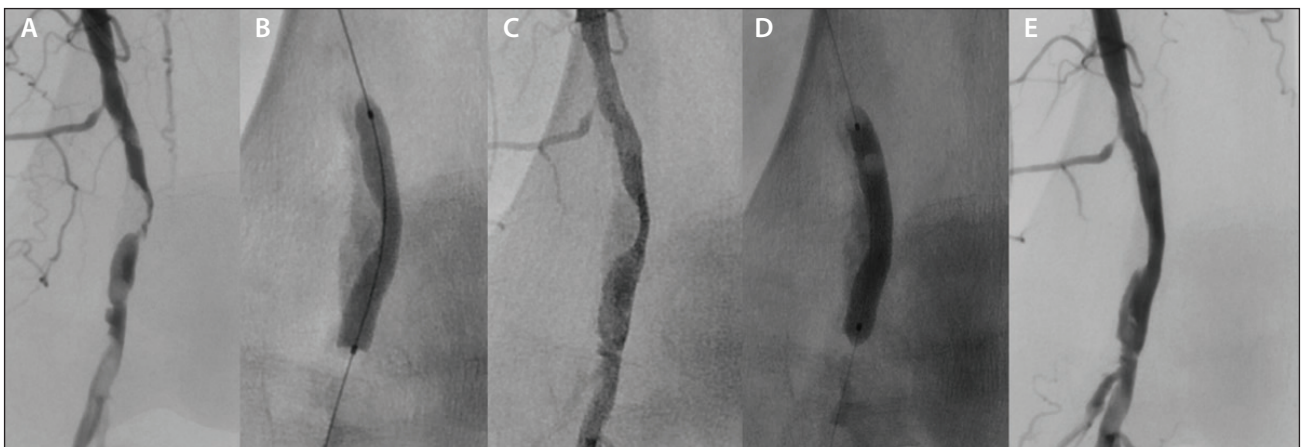


Figure 1. Heavily calcified eccentric lesion of the proximal PA (A). High-pressure balloon angioplasty (B). Early severe recoil (C). After angioplasty with the 6-X 40-mm Ranger™ DCB and plaque modification with the JETSTREAM™ Atherectomy System's 2.1-mm XC, the treated vessel is more compliant (D). Final angiography showing significant luminal gain (E).

is not able to provide the same effect, as there is only limited intravascular drug delivery.³ In many cases, there is an inability to dilate the lesion (Figure 1B and 1C), with higher dissection and perforation rates, leading to bailout stenting, higher stent fracture rates, and subsequent lower patency rates. Especially at the distal SFA and proximal PA levels, high failure rates of FP artery interventions are often attributed to severe mechanical deformations (axial compression, bending) that occur with limb movement.⁴ As the complexity of the lesions increases, the advantage of the JETSTREAM™ Atherectomy System (Boston Scientific Corporation) is that it can be utilized for plaque removal, allowing the vessel to be more compliant for subsequent DCB treatment (Figure 1D and 1E).

JETSTREAM™ ATHERECTOMY SYSTEM

At our institution, we use the JETSTREAM™ Atherectomy System to treat calcified complex lesions affecting the SFA, PA, and BTK vessels. We adopted the idea of plaque modification with the aim of improving periprocedural success by lowering the chance for periprocedural bailout stenting and prolonging long-term patency by adding DCB treatment. The JETSTREAM™ catheters are intended for atherectomy of the peripheral vasculature and to break apart and remove thrombus. The main advantage lies in the ability to perform thrombus removal and treat the underlying lesion in one session, especially when the age of the treated lesion is not certain. The main indications, based on our own experiences, are summarized in the *Indications for Atherectomy* sidebar.

The system consists of a sterile, single-use catheter attached to the control pod and the reusable power console. The catheter is compatible with a 0.014-inch wire and 7-F sheath and is equipped with a five-flute, front-end cutting tip (Figure 2).




Figure 2. The JETSTREAM™ Atherectomy System catheters. The nonexpandable SC devices are available in two sizes (1.6 mm and 1.85 mm). The XC devices are available in two sizes as well (2.1/3 mm and 2.4/3.4 mm). The device features active aspiration and is also approved for thrombus removal.

Adopting atherectomy technology takes time due to the learning curve involved. Therefore, the following cases highlight proper indications, lesion crossing and treatment techniques, correct catheter selection, and how to avoid complications and achieve an optimal result.

CASE PRESENTATIONS

Case 1: Distal SFA CTO

A 64-year-old man presented with clinical signs of limiting intermittent claudication and pain in the right calf. Previous ultrasound examination demonstrated patency of the common femoral artery (CFA), profunda femoris artery, and proximal SFA. The distal part of SFA was chronically occluded (Figure 3A), and the PA was patent and filled via collaterals.

An ipsilateral antegrade approach using a 7-F sheath was selected, with the aim to get the best tactile feedback from the cutter. After administering 5,000 units of intravenous heparin, a 0.018-inch, 300-cm-long, V-18™ ControlWire™ Guidewire (Boston Scientific Corporation) was used to recanalize the CTO along with the TrailBlazer™ Support

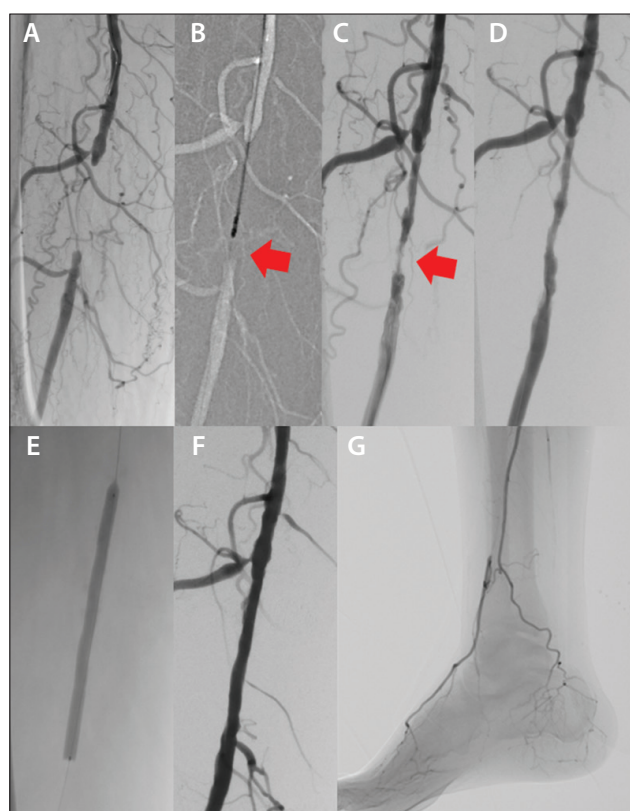


Figure 3. A CTO of the distal right SFA (A). The JETSTREAM™ Atherectomy System's 2.1-mm XC keeping the distal part of the lesion intact to act as a "filter" (red arrows) (B, C). Posttreatment imaging of the distal part of the lesion (D). Use of a 6- X 80-mm Ranger™ DCB (E). Final imaging showing the reconstituted SFA (F) without DE (G).

INDICATIONS FOR ATHERECTOMY*

- Long calcified lesions, complex CTO with/without thrombus
- In-stent occlusions
- Bifurcation and “no-stent” zones
- High-risk patients for open repair
- Contraindication for stent implantation or for dual antiplatelet therapy

*Based on the author's experience.

Catheter (Medtronic). Low-profile recanalization is important for preservation of the distal part of the disease, which acts as a “filter” while treating the more proximal disease (Figure 4), thus avoiding distal embolization (DE). After exchanging for a 0.014-inch Thruway™ Guidewire (Boston Scientific Corporation), the JETSTREAM™ Atherectomy System was used to debulk the lesion.

The 2.1/3-mm cutter was introduced close to the proximal part of the CTO, and after activation, two passes with blades down were performed without entering the 1- to 2-cm-long distal part of the CTO (Figure 3B). This maneuver allows treatment of the entire proximal portion of the CTO without the fear of distal embolization, avoids the need for placement of a distal embolic protection device (EPD) at the beginning of the procedure, and controls proper positioning during treatment. This tactic is especially helpful for longer lesion treatment (approximately 5- to 7-cm segments [Figure 4]), thus making the procedure more convenient. More importantly, the activation time should be kept short (30 seconds at a time) to avoid overheating




Figure 4. Treatment of long lesion segments (5–7 cm) by activating the blades-down mode then coming back to blades-up mode in each segment before moving to the next, thus having the more distal disease act as a “filter” while treating the more proximal disease.

or stalling the device. Proper aspiration can be controlled by monitoring the line leading to the collection bag.

After additional passes with blades up, the REX mode is activated, and slow catheter retrieval is recommended to allow proper aspiration of the debris. In this case, control angiography showed the smooth inner surface of the created lumen (Figure 3C). At this point, the distal part of the lesion was targeted with blades-down atherectomy (Figure 3D). If further atherectomy had been needed, the recanalized lumen was wide enough for EPD crossing and placement (the Emboshield® NAV6 Embolic Protection System [Abbott Vascular] is recommended). Due to a sufficient luminal gain, angioplasty using a 6- X 80-mm Ranger™ DCB (Boston Scientific Corporation) was performed (Figure 3E). Final angiography demonstrated full patency of the treated SFA without dissection or significant residual stenosis (Figure 3F) and without DE (Figure 3G).

Case 2: Calcified Tibioperoneal Trunk Stenosis and Peroneal Artery CTO

A 74-year-old man presented with clinical signs consisting of rest pain in the right calf and ischemic ulceration of the

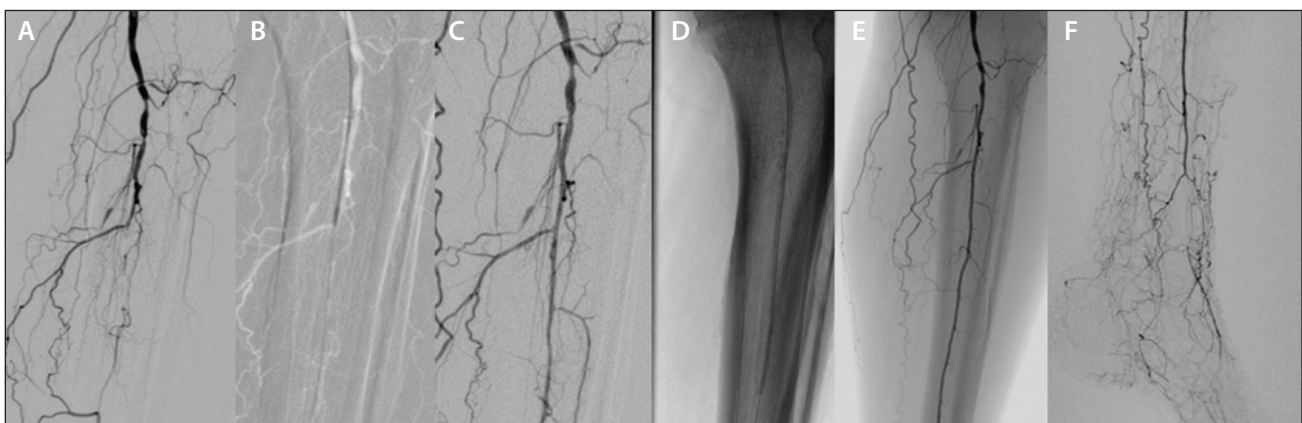


Figure 5. Critical obstructive disease of the tibioperoneal trunk and occlusion of the ATA, posterior tibial artery, and the mid part of the peroneal artery (A). The JETSTREAM™ Atherectomy System's 1.85-mm SC entering the calcified lesion (B). Angiography after treatment of the peroneal artery (C). PTA with a 2.5- X 200-mm balloon (D) followed by two 3- X 120-mm Ranger™ DCBs. The reconstituted peroneal artery (E) without DE (F).

toe. Previous ultrasound examination demonstrated patency of the FP artery and diffusely diseased BTK arteries. Ipsilateral antegrade access was achieved from the right CFA using a 7-F sheath. Selective angiography demonstrated highly calcified, critical obstructive disease of the tibioperoneal trunk, as well as occlusion of the anterior tibial artery (ATA), posterior tibial artery, and the mid part of the peroneal artery (Figure 5A). After several failed attempts, the occlusion of the mid peroneal artery was finally crossed by a 0.018-inch, 300-cm-long, 30-gauge Victory™ Guidewire (Boston Scientific Corporation). Balloon catheter advancement into the lesion was not possible due to its heavily calcified morphology.

After exchanging for a 0.014-inch Thruway™ Guidewire, the JETSTREAM™ Atherectomy System was used to modify the plaque and remove the calcium. The 1.85-mm single cutter (SC) was advanced, and two passes were performed, encompassing the entire length of the diseased tibioperoneal segment (Figure 5B). This was followed by additional angioplasty with a 2.5- X 200-mm percutaneous transluminal angioplasty (PTA) catheter (Figure 5C and 5D) and, subsequently, with two 3- X 120-mm Ranger™ DCBs. Final angiography demonstrated fast flow in the reconstituted peroneal artery, without dissection, early recoil, or DE (Figure 5E and 5F).

Case 3: In-Stent PA Occlusion

A 60-year-old man presented with clinical signs of severe, limiting claudication and pain in the right calf. Previous ultrasound examination demonstrated in-stent occlusion of the P2 and P3 segments of the PA and a resting ankle-brachial index of 0.45 in the right leg. An ipsilateral

antegrade approach from the CFA using a 45-cm-long, 7-F, straight Pinnacle® Destination® Guiding Sheath (Terumo Interventional Systems) was chosen. Selective right FP angiography demonstrated in-stent occlusion of the PA and patent BTK arteries filled via collaterals (Figure 6A).

After administering 5,000 units of intravenous heparin, a 0.018-inch, 300-cm-long, V-18™ ControlWire™ Guidewire was used to recanalize the CTO using a TrailBlazer™ Support Catheter (Figure 6B). After exchanging for a 0.014-inch Thruway™ Guidewire, the JETSTREAM™ Atherectomy System was used to debulk the lesion. The 2.1/3-mm cutter was introduced close to the proximal in-stent part of the CTO, and after activation, one pass with blades down and one pass with blades up were performed without entering the 1- to 2-cm-long distal part of the CTO (Figure 6C). As previously mentioned, this technique allows the treatment of the entire proximal portion of the CTO without the fear of DE and eluding the need for distal EPD placement. REX mode with slow catheter removal followed. Subsequently, a 0.035-inch TrailBlazer™ Support Catheter was advanced over the wire into the newly created channel, and the contrast agent was administered through this catheter. Angiography showed sufficient thrombus and neointima removal (Figure 6D). At this point, the distal part of the lesion was targeted with blades-down atherectomy (Figure 6E).

Repeat angiography revealed complete thrombus clearance and high-grade proximal and distal edge stent restenosis (Figure 7A). Balloon inflations were performed using 5- X 40-mm and 6- X 40-mm Ranger™ DCBs (Figure 7B and 7C). Final angiography demonstrated full patency of the treated PA without dissection or significant residual stenosis, with preserved collateral vessels arising

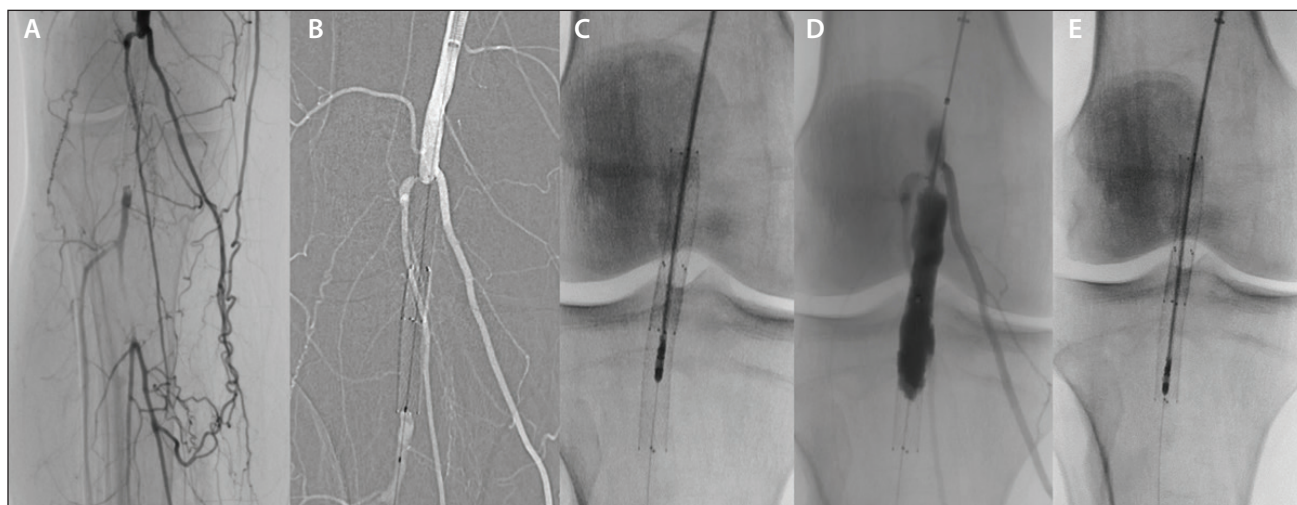


Figure 6. In-stent occlusion of the right PA (A). Intraluminal recanalization with a 0.018-inch, 300-cm-long, V-18™ ControlWire™ Guidewire and a 0.018-inch TrailBlazer™ Support Catheter (B). JETSTREAM™ Atherectomy System 2.1-mm activation, keeping the distal part of the lesion intact to act as a “filter” (C, D). Atherectomy of the distal part of the CTO (E).

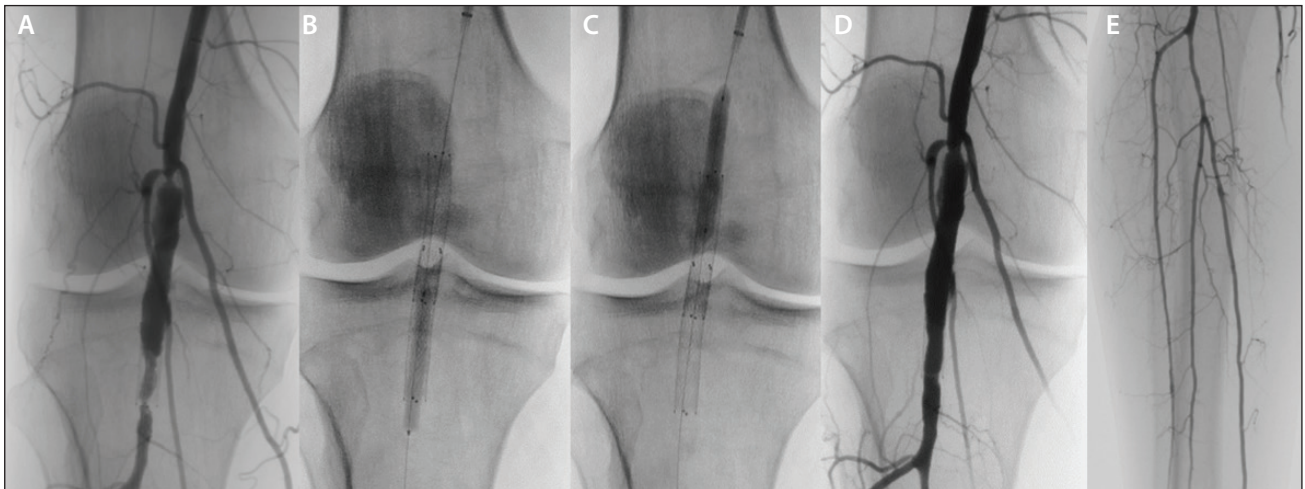


Figure 7. Angiography after activation of the JETSTREAM™ Atherectomy System's 2.1-mm XC, revealing high-grade proximal and distal edge stent restenosis (A), which was corrected by 5- X 40-mm and 6- X 40-mm Ranger™ DCBs (B, C). The reconstituted PA and preserved collateral vessels (D) without DE (E).

above the previously implanted stent (Figure 7D), and without DE (Figure 7E). The patient was discharged the following day symptom-free and with a resting ankle-brachial index of 0.85 in the right leg.

Case 4: Complex Calcific Occlusion of the Distal PA, Proximal ATA, and Tibioperoneal Artery

A 68-year-old woman presented with rest pain in the right foot and was referred for selective right FP and BTK angiography. Ipsilateral antegrade access was gained from the CFA using a 7-F sheath. Angiography demonstrated complex obstructive disease of the distal PA involving the tibioperoneal trunk and the origin of the ATA, with two-vessel runoff BTK to the ATA and peroneal artery (Figure 8A).

First, a 0.018-inch, 300-cm-long, V-18™ ControlWire™ Guidewire was used to recanalize the CTO using an angled TrailBlazer™ Support Catheter. After exchanging for a 0.014-inch Thruway™ Guidewire, the JETSTREAM™ Atherectomy System's 2.1-mm expandable cutter (XC) was used to debulk the lesion, and two passes with blades down were performed (Figure 8B). Control angiography showed smooth lumen (Figure 8C). At this point, the tibioperoneal trunk was targeted in the same fashion with blades-down atherectomy (Figure 8D). According to the "+1 mm rule," the blades-up mode was not activated in 3-mm-wide BTK arteries. Finally, kissing-balloon inflations were performed in both the ATA and tibioperoneal trunk with 2.5- X 40-mm and 3- X 40-mm Ranger™ DCBs (Figure 8E). Final arteriography demonstrated wide patency of the reconstituted vessels, without significant residual stenosis (Figure 8F) or DE (Figure 8G).

DISCUSSION

These case studies demonstrate that the JETSTREAM™ Atherectomy System is effective in treating severely calcified lesions in the FP and BTK arteries. Published randomized trials

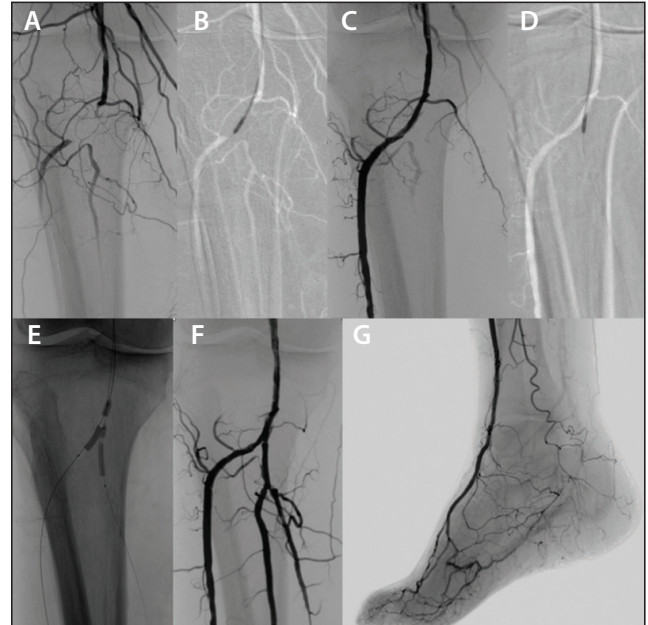


Figure 8. Occlusion of the distal PA involving the tibioperoneal trunk and origin of the ATA (A). Use of the JETSTREAM™ Atherectomy System's 2.1-mm XC in the ATA (B). Posttreatment imaging of the ATA (C). Use of the JETSTREAM™ Atherectomy System's 2.1-mm XC in the tibioperoneal trunk (D). Kissing-balloon angioplasty in both the ATA and tibioperoneal trunk with 2.5- X 40-mm and 3- X 40-mm Ranger™ DCBs (E). Final angiography without residual stenosis (F) or DE (G).

have shown that atherectomy can accomplish the task of vessel preparation, reducing dissections and bailout stenting.⁵⁻⁷

The JET multicenter prospective registry investigated the procedural, safety, and effectiveness outcomes of real-world practice with the JETSTREAM™ Atherectomy System for treatment of FP artery lesions.⁸ In total, 241 patients (41% with diabetes; Rutherford classes 1–3) with de novo or restenotic (nonstent) FP lesions ≥ 4 cm in length were enrolled. The mean (\pm standard deviation) lesion length was 16.4 ± 13.6 cm, an EPD was used in 22.4% of cases, and 35% of patients received adjunctive stents. The procedural success rate was 98.3%. The 30-day major adverse event rate was 2% (5/219: two target lesion/vessel revascularizations [TLR/TVR], three DEs). There were no deaths, index limb amputations, or myocardial infarctions. At 12 months, the overall estimated freedom from TLR/TVR was 81.7%, and 77.2% (44/57) of patients had no duplex ultrasound–assessed restenosis.⁸

At present, there are no randomized data comparing atherectomy with adjunctive DCB use versus atherectomy alone, stenting alone, or stenting with adjunctive DCB use. The long-term outcomes with the JETSTREAM™ Atherectomy System, with or without DCBs, in treating FP arteries were investigated in the JET-SCE study.⁹ In this study, 75 patients (54.7% with diabetes) with de novo or restenotic FP lesions (Rutherford class 1–5) were enrolled. Adjunctive PTA was performed in 50 patients (26 de novo, 13 in-stent restenosis, three nonstent restenosis, eight mixed lesions) and adjunctive DCB use (24 Lutonix® DCB [BD Interventional], one In.Pact™ DCB [Medtronic]) in 25 patients (21 de novo, one in-stent restenosis, two nonstent restenosis, one mixed lesion; $P = .0249$). The median treated length in both the adjunctive PTA (15 cm) and DCB (10 cm) groups was the same ($P = .0530$). The estimated freedom from TLR rate was significantly higher with atherectomy and adjunctive DCB than with atherectomy and adjunctive PTA at 12 months (94.7% vs 68%; $P = .002$) and 16 months (94.4% vs 54%; $P = .002$).⁹

Proper technique is essential for excellent results, and there is a learning curve during the adoption of the device. Slow advancement of the cutter is mandatory to avoid stalling of the device and to allow room for aspiration. EPDs have added a level of protection to the outflow vessels (eg, irregular/heavily calcified lesions, in-stent restenosis, TransAtlantic Inter-Society Consensus D lesions). The low-profile recanalization and preservation of the distal part of the CTO, which acts as a “filter” (Case 1) while treating the more proximal disease, significantly reduce the likelihood of DE and the need for EPD placement. The JETSTREAM™ Atherectomy System cutters feature front-end cutting. In complex calcific disease, this has the advantage of allowing the cutter to overcome the usually tougher proximal part of a lesion, which is otherwise impenetrable by conventional low-profile PTA catheters or

wires (Case 2). In-stent restenosis, and particularly reocclusion, is challenging for EVT; smooth muscle cell proliferation and thrombus presence with higher embolic potential usually require additional stent placement over existing stents.¹⁰ PTA has a very high rate of restenosis, and debulking is emerging as an important tool in treating FP in-stent restenosis combined with antirestenotic measures to prolong the TLR-free rate (Case 3). In case of bifurcation lesions, the main task during EVT is the preservation of the involved vessels and not covering their origin by stent implantation (Case 4). Based on my clinical experience, the JETSTREAM™ Atherectomy System can meet these challenges.

CONCLUSION

Recently, major technological advancements have been made in the field of EVT, and interventional specialists are encountering more complex and challenging cases. Durability and long-term patency remain the main goals in EVT of CLI. The JETSTREAM™ Atherectomy System has demonstrated a high procedural success rate, with a low rate of complications and early reinterventions. Now, it can be accompanied by DCB technologies with promising long-term patency, although this still needs to be addressed by large, randomized trials. ■

1. Faglia E, Clerici G, Clerici J, et al. Early and five-year amputation and survival rate of diabetic patients with critical limb ischemia: data of a cohort study of 564 patients. *Eur J Vasc Endovasc Surg*. 2006;32:484–490.
2. Shammas NW. Optimizing strategy in peripheral vascular interventions: the role of Jetstream® atherectomy. *J Invas Cardiol*. 2013;25 (supplement B):28.
3. Tzafirni AR, Garcia-Polite R, Zani B, et al. Calcified plaque modification alters local drug delivery in the treatment of peripheral atherosclerosis. *J Control Release*. 2017;264:203–210.
4. Poulson W, Kamenskiy A, Seas A, et al. Limb flexion-induced axial compression and bending in human femoropopliteal artery segments. *J Vasc Surg*. 2018;67:607–613.
5. Shammas NW, Coiner D, Shammas GA, et al. Percutaneous lower-extremity arterial interventions with primary balloon angioplasty versus Silverhawk atherectomy and adjunctive balloon angioplasty: randomized trial. *J Vasc Interv Radiol*. 2012;22:1223–1228.
6. Shammas NW, Lam R, Mustapha J, et al. Comparison of orbital atherectomy plus balloon angioplasty vs. balloon angioplasty alone in patients with critical limb ischemia: results of the CALCIUM 360 randomized pilot trial. *J Endovasc Ther*. 2012;19:480–488.
7. Zeller T, Langhoff R, Rocha-Singh RK, et al. Directional atherectomy followed by a paclitaxel-coated balloon to inhibit restenosis and maintain vessel patency: twelve-month results of the DEFINITIVE AR study. *Circ Cardiovasc Interv*. 2017;10:e004848.
8. Gray WA, Garcia LA, Amin A, Shammas BW, JET Registry Investigators. Jetstream Atherectomy System treatment of femoropopliteal arteries: results of the post-market JET Registry. *Cardiovasc Revasc Med*. 2018;19(5 Pt A):506–511.
9. Shammas NW, Shammas GA, Jones-Miller S, et al. Long-term outcomes with Jetstream atherectomy with or without drug coated balloons in treating femoropopliteal arteries: a single center experience (JET-SCE). *Cardiovasc Revasc Med*. 2018;19(7 Pt A):771–777.
10. Shammas NW, Weissman NJ, Coiner D, et al. Treatment of subacute and chronic thrombotic occlusions of lower extremity peripheral arteries with the excimer laser: a feasibility study. *Cardiovasc Revasc Med*. 2012;13:211–214.

CAUTION: The Ranger Drug-Coated Balloon Catheter is an Investigational Device. Limited by Federal (or US) law to investigational use only. Not available for sale in the US.

Tibor Balázs, MD

Interventional Radiologist
Chief of Endovascular Program
Center of Interventional Neuroradiology and
Endovascular Therapy
Bratislava, Slovakia
tibor.balazs@cinre.sk

Disclosures: Consultant, speaker, and performs workshops for Boston Scientific Corporation; receives honoraria from Boston Scientific Corporation.

The SAVAL Trial

Details on the design and rationale behind this randomized trial studying infrapopliteal drug-eluting stent use for critical limb ischemia.

**BY JIHAD A. MUSTAPHA, MD, FACC, FSCAI; PATRICK GERAGHTY, MD, FACS;
AND HANS VAN OVERHAGEN, MD, PhD, EBIR**

Prompt endovascular or surgical revascularization is recommended to restore distal perfusion, minimize tissue loss, and maintain quality of life for patients with critical limb ischemia (CLI).¹ The major advantage of endovascular treatment compared to surgical bypass is lower periprocedural morbidity and mortality, which is a concern in typical patients with CLI who are older, frail, and often present with systemic atherosclerosis, diabetes mellitus, and elevated risk for cardiovascular events. Patients with CLI presenting with infrapopliteal atherosclerotic lesions of the tibial or peroneal arteries are an especially challenging population because restoring vessel patency is considerably more difficult in infrapopliteal lesions compared to those in the femoropopliteal segment.

Despite the obvious advantages of an endovascular approach in patients with significant systemic comorbidities, percutaneous transluminal angioplasty (PTA) results remain suboptimal in infrapopliteal lesions.² Short coronary drug-eluting stents (DESs) have been evaluated in infrapopliteal lesions in several randomized controlled trials, demonstrating superior patency and freedom from reintervention with DES compared to PTA,³⁻⁵ with a sustained clinical benefit through 5 years.⁶ However, no DES is indicated in the United States for infrapopliteal use, and coronary stents are not well suited for the hostile infrapopliteal segment. A DES for dedicated infrapopliteal applications should be available in longer lengths to accommodate long tortuous lesions, provide adequate radial force to prevent stent collapse and restenosis, yet remain flexible enough to avoid fracture when subjected to torque and extravascular compressive forces.

The SAVAL trial was designed to provide level 1 evidence of the clinical utility of a DES that is specifically intended for infrapopliteal applications. Investigation of this DES was arranged through the FDA Breakthrough Devices Program (formerly the Expedited Access Pathway), which is intended to facilitate development and expedite the review of breakthrough technologies.⁷

TRIAL DESIGN

A total of approximately 301 patients with CLI undergoing infrapopliteal endovascular treatment are planned to be enrolled in the SAVAL trial (NCT03551496), which includes two phases. The first phase is a global, prospective, multicenter, randomized investigation designed to evaluate the safety and effectiveness of an infrapopliteal DES (Saval™ DES BTK, Boston Scientific Corporation) in patients with CLI. Approximately 201 patients with CLI (Rutherford class 4 and 5) will be randomly assigned (2:1) to the DES or PTA arms at up to 50 centers in the United States, Europe, and Japan. The primary objective of the randomized study is to demonstrate superior effectiveness and acceptable safety of infrapopliteal DES treatment versus PTA in patients with CLI.

The second phase of the SAVAL trial is a nonrandomized, single-arm study of 100 patients treated with the Saval™ DES BTK. Enrollment for this phase will commence after enrollment is complete in the randomized phase, with identical participating centers, eligibility criteria, procedures, outcome measures, and follow-up assessments. The purpose of the nonrandomized phase of the trial is to collect additional safety and efficacy data on patients who undergo implantation of a Saval™ DES BTK.

PATIENT ELIGIBILITY

Key eligibility criteria include Rutherford class 4 or 5 disease, life expectancy > 1 year, no previous surgery in the target vessel, no previous or planned major amputation in the target limb, and absence of significant systemic comorbidities such as renal failure, New York Heart Association class IV heart failure, or symptomatic coronary artery disease. Importantly, limb hemodynamics will be collected at study enrollment and at all follow-up visits but not used as an inclusion or exclusion criteria. Inclusion criteria assessed intraprocedurally include the presence of one target lesion per vessel in no more than two infrapopliteal arteries in a single limb, reference vessel

diameter of 2.5 to 3.75 mm, total lesion length \leq 70 mm (\leq 140 mm after approval for stent overlap), and lesion location at least 4 cm above the ankle joint.

STUDY PROCEDURES AND FOLLOW-UP

Patients will be randomly allocated to undergo infrapopliteal treatment with the self-expanding, nitinol, paclitaxel-eluting Saval™ DES BTK or PTA. This DES is specifically designed to optimize flexibility, radial/compressive strength, and fatigue properties for durable performance in infrapopliteal arteries. Commercially available PTA balloons, selected at the investigator's discretion, will be used as the comparator.

Adjunctive therapies for treating the target lesion, such as drug-coated balloons, atherectomy, or radiation therapy, are not permitted in the study. Anticoagulation and antiplatelet therapy will be administered before and during the procedure, according to the standard medication regimen at each center. Dual antiplatelet therapy is required in all patients for 6 months and is strongly recommended for 1 year in patients treated with the DES.

Patients will return for clinical and imaging follow-up at 1 month, 3 months, 6 months, and annually for 3 years.

OUTCOMES

The primary effectiveness endpoint of the randomized trial is primary patency at 6 months. Primary vessel patency will be evaluated by duplex ultrasound on a per-lesion basis. Primary patency is a binary endpoint determined by duplex ultrasound measurement of flow (vs no flow) in the absence of clinically driven target lesion revascularization (TLR) or bypass of the target lesion. The primary safety endpoint of this trial is freedom from major adverse limb events and postoperative death (MALE-POD) at 6 months. This is a composite outcome including MALE (above-ankle amputation of the index limb or major reintervention [eg, bypass or interposition graft, thrombectomy, thrombolysis]) and POD (death within 30 days of index procedure). The MALE outcome has been endorsed by the Society for Vascular Surgery and FDA, and it is a primary endpoint in the ongoing BEST-CLI trial.⁸⁻¹⁰ The single-arm study has a 12-month primary safety endpoint based on MALE-POD criteria, and efficacy information will also be collected.

Additional outcomes to be assessed include unplanned readmissions through 30 days, as well as hemodynamic outcomes and health-related quality of life (EuroQoL five dimensions and Vascular Quality of Life Questionnaire) through 1 year. Patency, clinically driven TLR, wound assessment, major amputations, Rutherford classification, and adverse events will be evaluated through 3 years.

Wound characteristics will be documented at each follow-up visit in patients with minor tissue loss, ischemic ulcer, or focal gangrene (Rutherford class 5) and evaluated by an independent blinded reviewer.

DISCUSSION

Revascularization remains the cornerstone of therapy for CLI and is recommended by the professional guidelines.^{11,12} The ongoing BEST-CLI trial may provide further insight into selective treatment strategies for these challenging patients. Although the specific role of surgery versus endovascular therapy remains uncertain, an endovascular-first approach has been recently advocated.¹³

For patients undergoing endovascular intervention, there is currently no DES that is approved for infrapopliteal applications in the United States. The aim of the SAVAL trial is to determine if a DES specifically developed for the infrapopliteal segment offers superior patency and acceptable safety compared with the current standard of care (PTA). The regulatory application for this trial will receive priority review by the FDA given the novelty of the device and because of the need for more effective treatment options in this patient population.

It should be noted that after the SAVAL trial had begun enrollment, the meta-analysis by Katsanos et al voiced concern regarding increases in late mortality seen after the use of paclitaxel-coated balloons and paclitaxel-eluting stents in the femoral and popliteal arteries.¹⁴ This issue has been closely followed by the FDA and Boston Scientific Corporation. After the release of the updated FDA letter to treating physicians in March 2019,¹⁵ the SAVAL trial informed consent document is being modified to reflect the following: the acknowledgment of a potential increased rate of mortality associated with paclitaxel-coated devices used to treat peripheral artery disease, the impact that this mortality signal may have on benefit-risk considerations for patient participation in the trial, and the need for diligent review and follow-up of all trial participants by the Data and Safety Monitoring Board.

CONCLUSION

Given that CLI is underdiagnosed, increasing in prevalence, and responsible for significant risk to life and limb, considerable efforts are needed to raise disease awareness, refine diagnostic algorithms, and establish evidence-based treatment pathways. The SAVAL randomized trial is a first-of-its-kind study that utilizes a DES that is specifically developed for infrapopliteal applications. ■

1. Shishehbor MH, White CJ, Gray BH, et al. Critical limb ischemia: an expert statement. *J Am Coll Cardiol*. 2016;68:2002–2015.
2. Mustapha JA, Finton SM, Diaz-Sandoval LJ, et al. Percutaneous transluminal angioplasty in patients with infrapopliteal arterial disease: systematic review and meta-analysis. *Circ Cardiovasc Interv*. 2016;9:e003468.
3. Scheinert D, Katsanos K, Zeller T, et al. A prospective randomized multicenter comparison of balloon angioplasty and infrapopliteal stenting with the sirolimus-eluting stent in patients with ischemic peripheral arterial disease: 1-year results from the ACHILLES trial. *J Am Coll Cardiol*. 2012;60:2290–2295.
4. Spreen MI, Martens JM, Hansen BE, et al. Percutaneous transluminal angioplasty and drug-eluting stents for infrapopliteal lesions in critical limb ischemia (PADI) trial. *Circ Cardiovasc Interv*. 2016;9:e002376.
5. Bosiers M, Scheinert D, Peeters P, et al. Randomized comparison of everolimus-eluting versus bare-metal stents in patients with critical limb ischemia and infrapopliteal arterial occlusive disease. *J Vasc Surg*. 2012;55:390–398.
6. Spreen MI, Martens JM, Knippenberg B, et al. Long-term follow-up of the PADI trial: percutaneous transluminal angioplasty versus drug-eluting stents for infrapopliteal lesions in critical limb ischemia. *J Am Heart Assoc*. 2017;6:e004877.
7. US Food and Drug Administration. Breakthrough devices program: draft guidance for industry and Food and Drug Administration staff. <https://www.fda.gov/downloads/MedicalDevices/DeviceRegulationandGuidance/GuidanceDocuments/UCM581664.pdf>. Published December 18, 2018. Accessed March 28, 2019.
8. Conte MS, Geraghty PJ, Bradbury AW, et al. Suggested objective performance goals and clinical trial design for evaluating catheter-based treatment of critical limb ischemia. *J Vasc Surg*. 2009;50:1462–1473.
9. Kumar A, Brooks SS, Cavanaugh K, Zuckerman B. FDA perspective on objective performance goals and clinical trial design for evaluating catheter-based treatment of critical limb ischemia. *J Vasc Surg*. 2009;50:1474–1476.
10. Menard MT, Farber A, Assmann SF, et al. Design and rationale of the best endovascular versus best surgical therapy for patients with critical limb ischemia (BEST-CLI) trial. *J Am Heart Assoc*. 2016;5:e003219.
11. Hirsch AT, Haskal ZJ, Hertzner NR, et al. ACC/AHA 2005 guidelines for the management of patients with peripheral arterial disease (lower extremity, renal, mesenteric, and abdominal aortic): executive summary a collaborative report from the American Association for Vascular Surgery/Society for Vascular Surgery, Society for Cardiovascular Angiography and Interventions, Society for Vascular Medicine and Biology, Society of Interventional Radiology, and the ACC/AHA Task Force on Practice Guidelines (Writing Committee to Develop Guidelines for the Management of Patients With Peripheral Arterial Disease) endorsed by the American Association of Cardiovascular and Pulmonary Rehabilitation; National Heart, Lung, and Blood Institute; Society for Vascular Nursing; TransAtlantic Inter-Society Consensus; and Vascular Disease Foundation. *J Am Coll Cardiol*. 2006;47:1239–1312.
12. Norgren L, Hiatt WR, Dormandy JA, et al. Inter-society consensus for the management of peripheral arterial disease (TASC II). *Eur J Vasc Endovasc Surg*. 2007;33(suppl 1):S1–75.
13. Jaff MR, White CJ, Hiatt WR, et al. An update on methods for revascularization and expansion of the TASC lesion classification to include below-the-knee arteries: a supplement to the inter-society consensus for the management of peripheral arterial disease (TASC II): the TASC steering committee. *Catheter Cardiovasc Interv*. 2015;86:611–625.
14. Katsanos K, Spiliopoulos S, Kitrou P, et al. Risk of death following application of paclitaxel-coated balloons and stents in the femoropopliteal artery of the leg: a systematic review and meta-analysis of randomized controlled trials. *J Am Heart Assoc*. 2018;7:e011245.
15. US Food and Drug Administration. Update: Treatment of peripheral arterial disease with paclitaxel-coated balloons and paclitaxel-eluting stents potentially associated with increased mortality—letter to health care providers. <https://www.fda.gov/MedicalDevices/Safety/LetterstoHealthCareProviders/ucm633614.htm>. Published March 15, 2019. Accessed April 3, 2019.

CAUTION: Investigational Device. Limited by Federal (or US) law to investigational use only. Not available for sale.

Products shown for informational purposes only – not meant as a promotion or offer for sale – certain components are pending CE Mark, not available for sale in the European Economic Area (EEA).

Jihad A. Mustapha, MD, FACC, FSCAI

Associate Professor

Michigan State University

Advanced Cardiac & Vascular Amputation Prevention Centers

Grand Rapids, Michigan

jmustapha@acvcenters.com

Disclosures: Consulting agreements with Bard Peripheral Vascular, Inc., Boston Scientific Corporation, Cardiovascular Systems, Inc., Medtronic, Philips, and Terumo.

Patrick Geraghty, MD, FACS

Professor of Surgery and Radiology

Washington University School of Medicine

St. Louis, Missouri

geraghtyp@wustl.edu

Disclosures: Consulting/advisory board for Bard/BD, Boston Scientific Corporation, Intact Vascular, Inc.; equity holder in Euphrates Vascular.

Hans van Overhagen, MD, PhD, EBIR

Department of Radiology

Haga Teaching Hospital

The Hague, the Netherlands

h.voverhagen@hagaziekenhuis.nl

Disclosures: Consultant to Boston Scientific Corporation.

Coyote OTW

CAUTION: Federal law (USA) restricts this device to sale by or on the order of a physician. Rx only. Prior to use, please see the complete "Directions for Use" for more information on Indications, Contraindications, Warnings, Precautions, Adverse Events, and Operator's Instructions.

INTENDED USE/INDICATIONS FOR USE

The Coyote OTW PTA Balloon Dilatation Catheter is indicated for Percutaneous Transluminal Angioplasty (PTA) in the peripheral vasculature, including iliac, femoral, popliteal, infra-popliteal and renal arteries, and for the treatment of obstructive lesions of native or synthetic arteriovenous dialysis fistulae.

CONTRAINDICATIONS

None known.

WARNINGS

- Any use for procedures other than those indicated in these instructions is not recommended.

PRECAUTIONS

- The Coyote OTW PTA Balloon Dilatation Catheter shall only be used by physicians trained in the performance of percutaneous transluminal angioplasty.
- The Coyote OTW PTA Balloon Dilatation Catheter should be used with caution for procedures involving calcified lesions or synthetic vascular grafts due to the abrasive nature of these inflation sites.
- The Coyote OTW PTA Balloon Dilatation Catheters are not intended for injection of contrast medium.
- Precautions to prevent or reduce clotting should be taken when any catheter is used:
- Consider systemic anticoagulation.
- Flush or rinse all products entering the vascular system with sterile isotonic saline or a similar solution prior to use.
- Consult the manufacturers instructions for use when using distal embolic protection devices during angioplasty.

ADVERSE EVENTS

The complications that may result from a balloon dilatation procedure include, but are not limited to:

- Allergic reaction (device, contrast medium and medications)
- Arteriovenous fistula
- Embolization (air, device, plaque, etc.)
- Hematoma
- Hemorrhage, including bleeding at puncture site
- Pseudoaneurysm
- Sepsis/infection
- Thromboembolic episodes
- Vessel injury, e.g. dissection, perforation, rupture
- Vessel occlusion
- Vessel spasm

91056106 AA

Imager II Angiographic Catheter

CAUTION: Federal law (USA) restricts this device to sale by or on the order of a physician. Rx only. Prior to use, please see the complete "Directions for Use" for more information on Indications, Contraindications, Warnings, Precautions, Adverse Events, and Operator's Instructions.

INTENDED USE/INDICATIONS FOR USE

The IMAGER II Angiographic Catheters are designed to provide a pathway for delivering contrast media to selected sites in the vascular system, including the carotid arteries. Additionally, the 5F Selective IMAGER II Angiographic Catheters without side holes can also be used for the controlled and selective delivery of the Boston Scientific Interlock - 35 Detachable Coils into the peripheral vasculature.

CONTRAINDICATIONS

No known contraindications.

WARNINGS

- Angiographic catheters are designed for use by physicians engaged in the practice of a specialized branch of medicine. Use of these devices should be restricted to those specialists trained to perform the procedure. A thorough understanding of the technical principles, clinical applications, and risks associated with diagnostic angiography is necessary before performing this procedure.
- Accordingly, the IMAGER II Angiographic Catheters should only be used by physicians with a thorough understanding of angiographic procedures.
- Due to the various sizes and shapes, and the relative stiffness of angiographic catheters, extreme care must be taken when selecting and using the IMAGER™ II Angiographic Catheters to avoid damage to the vessel walls through which this catheter passes.
- Do not exceed the pressure ratings printed on the device labeling. Catheter integrity may be compromised if pressure limits are exceeded.
- The risk associated with IMAGER II Angiographic Catheters outside the intended use is not known.

PRECAUTIONS

- Precautions to prevent or reduce clotting should be taken when any catheter is used in the vascular system. The catheter should always be filled with either heparinized saline solution or contrast medium. Use of systemic heparinization should be considered.

ADVERSE EVENTS

Potential adverse events (in alphabetical order) which may be associated with the use of angiographic catheters include but are not limited to:

- Access Site Related Trauma
- Arteriovenous Fistula
- Embolism
- Hemorrhage
- Infection
- Ischemia
- Neurological Deficit Including Stroke
- Plaque Dislodgment
- Pseudoaneurysm
- Thrombus Formation
- Vasospasm
- Vessel Occlusion
- Vessel Wall Damage/ Dissection/ Perforation/Rupture

90960881 AB

Jetstream Catheters combined with Console

Jetstream SC Atherectomy Catheter
Jetstream XC Atherectomy Catheter
Jetstream PVCN100 Console

CAUTION: Federal law (USA) restricts this device to sale by or on the order of a physician. Rx only. Prior to use, please see the complete "Directions for Use" for more information on Indications, Contraindications, Warnings, Precautions, Adverse Events, and Operator's Instructions.

Catheter INTENDED USE/INDICATIONS FOR USE

The JETSTREAM System is intended for use in atherectomy of the peripheral vasculature and to break apart and remove thrombus from upper and lower extremity peripheral arteries. It is not intended for use in coronary, carotid, iliac or renal vasculature.

Console INTENDED USE/INDICATIONS FOR USE

The PVCN100 Console is designed for use only with the JETSTREAM Catheter and Control Pod. See the current revision of the applicable Catheter and Control Pod Directions for Use for further information.

CONTRAINDICATIONS

None known.

Catheter WARNINGS

- Use room temperature infusate only. Use of heated infusate may lead to wrinkling, ballooning and/or bursting of the outer catheter sheath, which could lead to injury to the patient
- Operating the Catheter over a kinked guidewire may cause vessel damage or guidewire fracture.
- During treatment, do not allow the Catheter tip within 10.0 cm of spring tip portion of the guidewire. Interaction between the Catheter Tip and this portion of the guidewire may cause damage to or detachment of the guidewire tip or complicate guidewire management.
- The guidewire must be in place prior to operating the Catheter in the patient. Absence of the guidewire may lead to inability to steer the Catheter and cause potential vessel damage.
- If the guidewire is accidentally retracted into the device during placement or treatment, stop use, and remove the Catheter and the guidewire from the patient. Verify that the guidewire is not damaged before re-inserting the guidewire. If damage is noticed, replace the guidewire.
- Check the infusate bag frequently and replace when needed. Do not run the JETSTREAM System without infusate as this may cause device failure.
- Hold the guidewire firmly during Catheter retraction process. Failure to do so may result in guidewire rotation within the vessel, which could cause patient injury.
- Do not manipulate the Catheter against resistance unless the cause for that resistance has been determined.
- Prior to use of the JETSTREAM System, confirm the minimum vessel diameter proximal to the lesion per the following table:

Model	1.6	1.85	2.1/3.0	2.4/3.4
Minimum Vessel Diameter Proximal to Lesion	2.5 mm	2.75mm	-	-
Minimum Vessel Diameter, Blades Down	-	-	3.0 mm	3.5 mm
Minimum Vessel Diameter, Blades Up	-	-	4.0 mm	4.5 mm

Catheter PRECAUTIONS

- Do not bend or kink the Catheter during setup or during the procedure. This may damage the device and lead to device failure.
- Do not inject contrast while the device is activated.
- Use only listed compatible guidewires and introducers with the JETSTREAM System. The use of any supplies not listed as compatible may damage or compromise the performance of the JETSTREAM System.

Console WARNINGS AND PRECAUTIONS

- WARNING:** To avoid the risk of electric shock, this equipment must only be connected to a supply mains with protective earth.
- Do not open either pump door during operation of the System. Doing so could result in loss of aspiration and/or infusion and will halt device activation.
- Ensure the PVCN100 Console display is visible during the entire procedure.
- Observe normal safety practices associated with electrical/electronic medical equipment.
- Avoid excessive coiling or bending of the power cables during storage.
- Store the PVCN100 Console using appropriate care to prevent accidental damage.
- Do not place objects on the PV Console.
- Do not immerse the PV Console in liquids.

ADVERSE EVENTS

Potential adverse events associated with use of this device and other interventional catheters include, but are not limited to the following (alphabetical order):

- | | | |
|---------------------------------------|----------------------|---|
| • Abrupt or sub-acute closure | • non-access site | • Restenosis of the treated segment |
| • Amputation | • Death | • Vascular |
| • Bleeding complications, access site | • Dissection | complications which may require surgical repair |
| • Bleeding complications, | • Distal emboli | • Thrombus |
| | • Hypotension | • Vasospasm |
| | • Infection or fever | |
| | • Minor burn | |
| | • Perforation | |

91063447 AB

OptiCross 18 Catheter and MDU5 PLUS Bag

CAUTION: Federal law (USA) restricts this device to sale by or on the order of a physician. Rx only. Prior to use, please see the complete "Directions for Use" for more information on Indications, Contraindications, Warnings, Precautions, Adverse Events, and Operator's Instructions.

INTENDED USE/INDICATIONS FOR USE

OptiCross 18 Catheter: This catheter is intended for intravascular ultrasound examination of peripheral vessels only. Intravascular ultrasound imaging is indicated in patients who are candidates for transluminal interventional procedures. MDU5 PLUS Sterile Bag: The MDU5 PLUS Sterile Bag is intended to cover the motordrive during intravascular ultrasound procedures to maintain the sterile field and prevent transfer of microorganisms, body fluids and particulate material to the patient and healthcare worker.

CONTRAINDICATIONS

Use of this product is contraindicated in the presence of conditions which create unacceptable risk during catheterization.

WARNINGS

- Intravascular ultrasound examination of vascular anatomy should be performed only by physicians fully trained in interventional radiology and in the techniques of intravascular ultrasound, and in the specific approach to be used, in a fully-equipped cardiac catheterization lab.
- The catheter has no user serviceable parts. Do not attempt to repair or to alter any component of the catheter assembly as provided. Using an altered catheter can result in poor image quality or patient complications.
- No modification of this equipment is allowed.
- **Do not pinch, crush, kink or sharply bend the catheter at any time. An insertion angle greater than 45° is considered excessive.**
- Do not manipulate, advance and/or withdraw the coated device through a metal cannula or needle. Manipulation, advancement and/or withdrawal through such a metal device may result in destruction and/or separation of the outer hydrophilic coating, resulting in coating material remaining in the vasculature, which may cause adverse events and require additional intervention.
- Do not advance the catheter if resistance is encountered. The catheter should never be forcibly inserted into lumens narrower than the catheter body or forced through a tight stenosis.
- When advancing the catheter through a stented vessel, catheters that do not completely encapsulate the guidewire may engage the stent between the junction of the catheter and guidewire, resulting in entrapment of catheter/guidewire, catheter tip separation, and/or stent dislocation.
- If resistance is met upon withdrawal of the catheter, verify resistance using fluoroscopy, then remove the entire system simultaneously.
- When readvancing a catheter after deployment of stent(s), at no time should a catheter be advanced across a guidewire that may be passing between one or more stent struts. A guidewire may exit between one or more stent struts when recrossing stent(s). Subsequent advancement of the catheter could cause entanglement between the catheter and the stent(s), resulting in entrapment of catheter/guidewire, catheter tip separation and/or stent dislocation. Use caution when removing the catheter from a stented vessel.
- Inadequately apposed stents, overlapping stents, and/or small stented vessels with distal angulation may lead to entrapment of the catheter with the stent upon retraction. When retracting the catheter, separation of a guidewire from an imaging catheter or bending of the guidewire may result in kinking of the guidewire, damage to the catheter distal tip, and/or vessel injury. The looped guidewire or damaged tip may catch on the stent strut resulting in entrapment.

PRECAUTIONS

- Do not attempt to connect the catheter to electronic equipment other than the designated Systems.
- Never attempt to attach or detach the catheter while the motor is running.
- If difficulty is encountered when backloading the guidewire into the distal end of the catheter, inspect the guidewire exit port for damage before inserting the catheter into the vasculature.
- Never advance the imaging catheter without guidewire support.
- Never advance the distal tip of the imaging catheter near the very floppy end of the guidewire.
- Never advance or withdraw the imaging catheter without the imaging core assembly being positioned at the most distal portion of the imaging window.
- During and after the procedure, inspect the catheter carefully for any damage which may have occurred during use. Multiple insertions may lead to catheter exit port dimension change/distortion which could increase the chance of the catheter catching on the stent. Care should be taken when re-inserting and/or retracting catheter to prevent exit port damage.

- Turn the MDU5 PLUS™ "OFF" before withdrawing the imaging catheter.

ADVERSE EVENTS

The risks and discomforts involved in vascular imaging include those associated with all catheterization procedures. These risks or discomforts may occur at any time with varying frequency or severity. Additionally, these complications may necessitate additional medical treatment including surgical intervention and, in rare instances, result in death.

- | | | |
|---|--|--|
| • Allergic reaction | • Hemorrhage/ Hematoma | • Stroke and Transient Ischemic Attack |
| • Device entrapment requiring surgical intervention | • Hypotension and/ or bradycardia (vasovagal syndrome) | • Thrombosis |
| • Embolism (air, foreign body, tissue or thrombus) | • Infection | • Vessel occlusion and abrupt closure |
| • End organ infarction | • Peripheral ischemia | • Vessel trauma including, but not limited to dissection and perforation |

91161545 AA

Rotablator Rotational Atherectomy System

Rotablator Peripheral Rotalink Plus

Rotablator Peripheral RotaWire Guidewire and wireClip Torquer

Rotablator Rotational Atherectomy System Console

Rotaglide Lubricant

CAUTION: Federal law (USA) restricts this device to sale by or on the order of a physician. Rx only. Prior to use, please see the complete "Directions for Use" for more information on Indications, Contraindications, Warnings, Precautions, Adverse Events, and Operator's Instructions.

Rotalink Plus INTENDED USE/INDICATIONS FOR USE

The Rotablator Rotational Atherectomy System is intended for percutaneous use in the peripheral vessels in patients with occlusive atherosclerotic disease who are acceptable candidates for endovascular procedures.

RotaWire: INDICATIONS FOR USE/INTENDED USE

These guidewires are intended for use with the Rotablator Rotational Atherectomy System.

Lubricant INDICATIONS FOR USE

Rotaglide lubricant is intended for use with the Rotablator atherectomy system, for the purpose of increasing the lubricity of the system.

CONTRAINDICATIONS AND RESTRICTIONS

Contraindications

1. Occlusions through which a guidewire will not pass.
2. Use in coronary arteries.
3. Long (≥ 20 cm) total occlusions.
4. Angiographic evidence of thrombus prior to treatment with the Rotablator Rotational Atherectomy System. Such patients may be treated with thrombolytics (e.g., Urokinase). When the thrombus has been resolved for two to four weeks, the lesion may be treated with the Rotablator Rotational Atherectomy System.
5. Angiographic evidence of significant dissection at the treatment site. The patient may be treated conservatively for approximately four weeks to permit the dissection to heal before treating the lesion with the Rotablator Rotational Atherectomy System.

Lubricant CONTRAINDICATIONS

Rotaglide™ lubricant is contraindicated in patients with known allergies to the lubricant ingredients: olive oil, egg yolk phospholipids, glycerin, sodium deoxycholate, L-histidine, disodium EDTA, sodium hydroxide, and water.

Restrictions

- Federal (USA) law restricts the use of this system to physicians who are credentialed in peripheral angioplasty and who have attended the Rotablator System Physician Training Program.

WARNINGS

- The risks of Rotational Atherectomy can be reduced if the device and associated accessories are used in the appropriate patient population by a physician who has had adequate training.
- If the Peripheral Rotalink Plus shows evidence of mechanical failure at any time prior to or during the angioplasty procedure, immediately discontinue use of the device and return it to Customer Service for evaluation. Do NOT attempt to use a damaged Peripheral Rotalink Plus; use may result in device malfunction and/or patient injury.
- Never operate the Peripheral Rotalink Plus without saline infusion. Flowing saline is essential for cooling and lubricating the working parts of the advancer. Operation of the advancer without proper saline infusion may result in permanent damage to the advancer.
- Never operate the Peripheral Rotalink Plus with the Rotablator Rotational Atherectomy System in Dynaglide™ mode or operate the guidewire brake defeat button unless you have a firm grip on the guidewire using the wireClip™ Torquer. The wireClip Torquer may be held with the fingers or inserted completely into the docking port after the brake button is depressed. Defeating the brake, or operating the Peripheral Rotalink Plus with the Rotablator Rotational Atherectomy System in Dynaglide mode, without securing the guidewire may result in rotation and entanglement of the guidewire.
- During setup of the Peripheral Rotalink Plus never grip or pull on the flexible shaft.
- The burr at the distal tip of the Peripheral Rotalink Plus is capable of rotating at very high speeds. Do NOT allow parts of the body or clothing to come in contact with the burr. Contact may result in physical injury or entanglement.

- Never advance the rotating burr to the point of contact with the guidewire spring tip. Such contact could result in distal detachment and embolization of the tip.
- If the Peripheral RotaLink Plus stops and the red STALL light on the console illuminates, retract the burr and immediately discontinue treatment. Check the advancer for proper connection to the console. If the connections are correct, use fluoroscopy to analyze the situation. Never force the system when rotational or translational resistance occurs, as vessel perforation may occur.
- Never advance the rotating burr by advancing the sheath. Guidewire buckling may occur and perforation or vascular trauma may result. Always advance the rotating burr by using the advancer knob.
- If resistance is encountered, retract the burr and stop treatment immediately. Use fluoroscopy to analyze the situation. Never force the Peripheral RotaLink Plus when rotational or translational resistance occurs, as vessel perforation, vessel trauma or embolism due to burr detachment or fractured wire may occur and in rare instances may result in surgical intervention and death.
- The use of Rotablator Rotational Atherectomy System for in-stent restenosis might lead to damage of stent components and/or Peripheral RotaLink Plus, which may lead to patient injury.
- Always keep the burr advancing or retracting while it is rotating. Maintaining the burr in one location while it is rotating may lead to excessive tissue removal or damage to the Peripheral RotaLink Plus or entrapment of the Peripheral RotaLink Plus. It is best to advance and retreat the burr no more than 3 cm at a time in a smooth pecking motion, being careful to engage the lesion only minimally when resistance is met. Do not allow the individual burr run time to exceed 30 seconds with total rotational procedure time not to exceed five minutes.

RotaWire WARNINGS

Use extreme caution and careful judgment in patients for whom anticoagulation is not indicated.

WARNINGS

- Never use oxygen as the propellant for the Rotablator Rotational Atherectomy System.
- The use of accessories, transducers and cables other than those specified, with the exception of transducers and cables sold by the manufacturer of the Rotablator System as replacement parts for internal components, may result in increased emissions or decreased immunity of the Rotablator System.
- This device is not to be used in the presence of flammable anesthetics.
- Do NOT operate the Rotablator Console with gas pressures in excess of 758.4 kPa (110 psi).
- Do not modify or repair.

Lubricant WARNINGS

Discard vial if there are particulates in the emulsion or if an oiling-out of emulsion has occurred.

PRECAUTIONS

- Percutaneous rotational angioplasty with the Rotablator Rotational Atherectomy System should only be carried out at medical facilities where prompt treatment can be immediately performed in the event of a potentially injurious or serious complication.
- Appropriate drug therapy including (but not limited to) anticoagulant and vasodilator therapy must be provided to the patient during all phases of patient care.
- When the Peripheral RotaWire™ Guidewires and/or Peripheral RotaLink Plus are in the body, they should only be manipulated while they are under fluoroscopic observation with radiographic equipment that provides high resolution images.
- Use only normal saline as the infusate. Never inject contrast agent, or any other substance that is not approved as part of the Rotablator Rotational Atherectomy System, into the infusion port or saline infusion bag as this may cause permanent damage to the Peripheral RotaLink Plus.

Console PRECAUTIONS

- User should take precautions when using the console in conjunction with other medical electrical equipment.
- The Rotablator Console needs special precautions regarding EMC and needs to be installed and put into service according to the EMC information provided in Appendix D in the DFU.

ADVERSE EVENTS

Potential adverse reactions which may result from the use of this device include but are not limited to:

- | | | |
|---------------------------|---|------------------------|
| • Additional intervention | • Stroke | • There may also |
| • Allergic reaction | • Slow, no flow, abrupt vessel closure | be complications |
| • Amputation | • Surgery including arterial bypass | associated with |
| • Death | • Thrombosis and vessel occlusion | distortion, kinks, |
| • Embolism | • Vessel trauma (dissection, perforation, | and fracture of |
| • Hematoma/Hemorrhage | psudoaneurysm, arteriovenous fistula) | the guidewire |
| • Hemodynamic changes | | and physical |
| • Hemoglobinuria | | deterioration or |
| • Infection | | malfunction of the |
| • Restenosis | | device, which can |
| | | lead to patient injury |
| | | or death |

There may also be complications associated with distortion, kinks, and fracture of the guidewire and physical deterioration or malfunction of the device, which can lead to patient injury or death.

91059041 AC

Rubicon 14 18 4f 35 5f Support Cath

CAUTION: Federal law (USA) restricts this device to sale by or on the order of a physician. Rx only. Prior to use, please see the complete "Directions for Use" for more information on Indications, Contraindications, Warnings, Precautions, Adverse Events, and Operator's Instructions.

INTENDED USE/INDICATIONS FOR USE

The Rubicon Support Catheter is intended to facilitate placement and support of guidewires and other interventional devices within the peripheral vasculature and to allow for exchange of guidewires, and provide a conduit for the delivery of saline or contrast solutions.

CONTRAINDICATIONS

None known

WARNINGS

- The catheter is designed and intended for intravascular use only.
- This catheter is designed and intended for one time use only. Do not re-sterilize and/or reuse.
- This catheter should only be used by physicians qualified to perform percutaneous, vascular interventions.
- These catheters are not designed for use in the coronary arteries or the neurovasculature. Any use for procedures other than those indicated in the instructions is not recommended.

PRECAUTIONS

Support Catheters are designed for use by physicians engaged in the practice of a specialized branch of medicine.

Use of these devices should be restricted to those specialists trained to perform the procedure. A thorough understanding of the technical principles, clinical applications and risks associated with support catheters is necessary before performing this procedure.

- Precautions to prevent or reduce clotting should be taken when any catheter is used. Use of systemic heparinization should be considered.

ADVERSE EVENTS

Vascular catheterization and/or vascular interventions may result in complications including but not limited to:

- | | | |
|---|--|---|
| • Access site pain | • Impaired blood flow | damage such as |
| • Allergic reaction (drug, contrast, device & other) and neurological reactions | due to thrombosis, embolism, or vasospasm that could lead to tissue infarction, limb amputation, and other thrombo-embolic organ | renal infarction |
| • Death | | • Infection/Sepsis |
| • Hemorrhage or hematoma | | • Vessel injury (dissection, perforation, trauma & rupture) |
| | | • Vasospasm |

91026982 AA

SAVION DLVR and SAVION FLX Guidewires

CAUTION: Federal law (USA) restricts this device to sale by or on the order of a physician. Rx only. Prior to use, please see the complete "Directions for Use" for more information on Indications, Contraindications, Warnings, Precautions, Adverse Events, and Operator's Instructions.

INTENDED USE/INDICATIONS FOR USE

Boston Scientific SAVION DLVR™ and SAVION FLX™ Guidewires are intended to facilitate the placement of balloon dilatation catheters or other interventional therapeutic devices during PTCA, PTA, or other intravascular interventional procedures. They are not intended for use in the cerebral vasculature.

CONTRAINDICATIONS

None known.

WARNINGS

Use extreme caution and careful judgment in patients for whom anticoagulation is not indicated. Severe reaction may occur in response to contrast agents that cannot be adequately premedicated. When the guidewire is in the body, it should be manipulated only under fluoroscopy. The hydrophilic coating of these guidewires increases the possibility of vessel wall perforation compared to non-hydrophilic coatings.

PRECAUTIONS

Carefully check and match therapeutic device compatibility to the wire prior to use.

ADVERSE EVENTS

Potential adverse events which may result from the use of the device include but are not limited to:

- Abrupt closure
- Allergic reaction (to contrast, device or other)
- Angina or unstable angina
- Arrhythmias
- Bleeding/Hemorrhage
- Cardiac tamponade/pericardial effusion
- Death
- Embolization (plaque, thrombus, device, tissue, or other)
- Hematoma
- Infection/Sepsis
- Myocardial infarction or ischemia
- Pain at the access site
- Pseudoaneurysm
- Renal insufficiency or renal failure
- Stroke/cerebral vascular accident (CVA)/transient ischemic attack (TIA)
- Thrombosis/Thrombus
- Vasospasm
- Vessel trauma (dissection, perforation, rupture or injury)
- Vessel perforation, dissection, trauma or damage
- Embolism
- Hematoma
- Infection
- Vessel spasm
- Hemorrhage
- Renal Failure
- Myocardial
- Infarction
- Vascular thrombosis
- Stroke
- Death

90960864 AB

V-18 Control Wire Guidewire with ICE Coating

CAUTION: Federal law (USA) restricts this device to sale by or on the order of a physician. Rx only. Prior to use, please see the complete "Directions for Use" for more information on Indications, Contraindications, Warnings, Precautions, Adverse Events, and Operator's Instructions.

INTENDED USE/INDICATIONS FOR USE

The V-18 Control Wire guidewire is available in 110, 150, 200 and 300 cm lengths. The wire can be torqued to facilitate the selective placement of diagnostic or therapeutic catheters. This device is intended for peripheral use only. A torque device (pin vise) is included with each wire to facilitate directional manipulation of the guidewire. The 110 cm V-18 Control Wire guidewire is intended for general intravascular use including the placement of PTA balloon catheters requiring an 0.018 in guidewire in hemodialysis AV access procedures. The 150, 200 and 300 cm V-18 Control Wire guidewire are intended for general intravascular use.

CONTRAINDICATIONS

Boston Scientific 110 cm Guidewires are not intended for use in the cerebral vasculature.

PRECAUTIONS

- This device should be used only by physicians thoroughly trained in percutaneous, intravascular techniques and procedures.

ADVERSE EVENTS

Potential adverse events which may result from the use of the device include but are not limited to:

- Air Embolism/Thromboembolism
- Allergic Reaction
- Amputation
- Arteriovenous (AV) Fistula
- Death
- Embolism
- Hematoma
- Hemorrhage
- Hemoglobinuria
- Infection or Sepsis/Infection
- Myocardial Ischemia and/or Infarction
- Pseudoaneurysm
- Stroke (CVA)/Transient Ischemic Attacks (TIA)
- Thrombus
- Vessel Occlusion
- Vessel Perforation, Dissection, Trauma or Damage
- Vessel Spasm
- Wire Entrapment/Entanglement
- Foreign Body/Wire Fracture

90960873 AB

Victory Peripheral Guidewire

CAUTION: Federal law (USA) restricts this device to sale by or on the order of a physician. Rx only. Prior to use, please see the complete "Directions for Use" for more information on Indications, Contraindications, Warnings, Precautions, Adverse Events, and Operator's Instructions.

INDICATIONS FOR USE

The Victory guidewires are intended to facilitate the placement and exchange of balloon catheters or other interventional devices within the peripheral vasculature during Percutaneous Transluminal Angioplasty (PTA) or other intravascular interventional procedures.

CONTRAINDICATIONS

The Victory guidewires are not intended for use in the coronary or cerebral vasculatures or in patients judged not acceptable for percutaneous intervention.

PRECAUTIONS

- This device should be used only by physicians trained in percutaneous, intravascular techniques and/or procedures.
- Carefully read all instructions prior to use. Observe all warnings and precautions noted throughout these instructions. Failure to do so may compromise guidewire performance and result in complications.

ADVERSE EVENTS

Potential adverse events which may result from use of the device include but are not limited to:

- Hematoma and other access site complications
- Death
- Hemorrhage (bleeding)
- Reaction to contrast media
- Irritation to vessel causing vessel spasm
- Vessel dissection or perforation
- Thrombus formation

90960874 AA

Some of the above potential adverse events may require additional urgent intervention or surgery.

92275338 A

Sterling Over-the-Wire

CAUTION: Federal law (USA) restricts this device to sale by or on the order of a physician. Rx only. Prior to use, please see the complete "Directions for Use" for more information on Indications, Contraindications, Warnings, Precautions, Adverse Events, and Operator's Instructions.

INTENDED USE/INDICATIONS FOR USE

The Sterling OTW PTA Balloon Dilatation Catheter is indicated for Percutaneous Transluminal Angioplasty (PTA) in the peripheral vasculature, including iliac, femoral, popliteal, infra-popliteal, and renal arteries, and for the treatment of obstructive lesions of native or synthetic arteriovenous dialysis fistulae. This device is also indicated for post-dilatation of balloon expandable and self-expanding stents in the peripheral vasculature.

CONTRAINDICATIONS

None known.

GENERAL PRECAUTIONS

The Sterling OTW PTA Balloon Dilatation Catheter shall only be used by physicians trained in the performance of percutaneous transluminal angioplasty. The Sterling OTW PTA Balloon Dilatation Catheter should be used with caution for procedures involving calcified lesions or synthetic vascular grafts due to the abrasive nature of these lesions. Sterling™ OTW PTA Balloon Dilatation Catheters are not intended for injection of contrast medium. Precautions to prevent or reduce clotting should be taken when any catheter is used:

- Consider systemic heparinization.
- Flush or rinse all products entering the vascular system with sterile isotonic saline or a similar solution prior to use.

ADVERSE EVENTS

The complications that may result from a balloon dilatation procedure include, but are not limited to:

- Allergic reaction to contrast medium
- Arrhythmias
- Arteriovenous fistula
- Cerebrovascular accidents
- Death
- Hematoma
- Hemodynamic instability
- Hemorrhage
- Pseudoaneurysm
- Pyrogenic reaction
- Sepsis/infection
- Thromboembolic episodes
- Vascular thrombosis
- Vessel injury, e.g. dissection, perforation, rupture
- Vessel occlusion
- Vessel spasm

91056104 AB

Thruway .014 Guidewire

CAUTION: Federal law (USA) restricts this device to sale by or on the order of a physician. Rx only. Prior to use, please see the complete "Directions for Use" for more information on Indications, Contraindications, Warnings, Precautions, Adverse Events, and Operator's Instructions.

INTENDED USE/INDICATIONS FOR USE

The Thruway Guidewire facilitates placement of a catheter during diagnostic or interventional peripheral intravascular procedures including but not limited to renal intervention. The wire can be torqued to facilitate navigation through the vasculature.

CONTRAINDICATIONS

- Not intended for use in coronary arteries.
- Not intended for use in the neurovasculature.

WARNINGS/ADVERSE REACTIONS

The complications that may result from the use of a guidewire in a procedure include:

SAVION FLX™ & SAVION DLVR™ GUIDEWIRES

TAKE CONTROL OF COMPLEXITY

Building on trusted technology

Savion Guidewires exhibit attributes ideally matched for BTK interventions to help you treat complex lesions successfully and restore blood flow to the leg.

