

IVC Filter Placement in Bariatric Patients

Selective placement can limit pulmonary embolism, the leading cause of death in this growing surgical population.

BY DIRK S. BAUMANN, MD, FACS

There has been a change in the indications for inferior vena cava (IVC) filter placement. In the earliest reports of filter use, the majority of filters were placed because of the failure of anticoagulation to prevent pulmonary embolism (PE).¹ Now, more than half of filters are placed prophylactically for the prevention of PE.² Not only are filters being placed for prophylaxis against PE in patients with known deep vein thrombosis (DVT), but filters are also being used in patients who are only at risk of developing a thromboembolic event.

There are three main conditions for which filters are being placed prophylactically for this indication. Neurosurgical patients, especially those with paralysis, are at particularly high risk for PE and are often not able to be anticoagulated because of the risk of intracranial hemorrhage. Second, many trauma centers have adopted policies of prophylac-

tic IVC filter placement in high-risk patients, such as those who are immobile, or are at risk for bleeding complications, or are unable to be screened with ultrasound for DVT due to their injuries. Langan et al have shown a significantly reduced incidence of PE in those high-risk trauma patients who have undergone prophylactic filter placement.³ Last, obese patients undergoing surgery are at substantial risk for developing thromboembolic disease. The increasingly important role of surgical therapy for treating the morbidly obese has brought more relevance to the issue of prophylaxis for PE in this patient population. The introduction of retrievable IVC filters may perpetuate the increased use of filters for prophylaxis. This is particularly true in patients with a short, defined period of increased risk for thromboembolic disease.

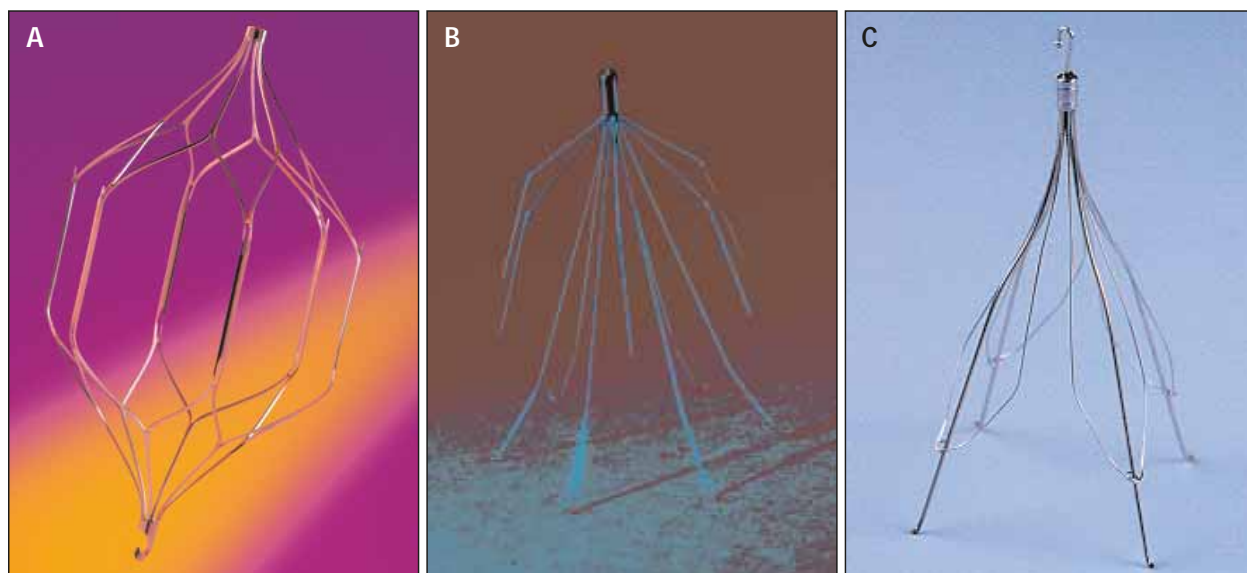


Figure 1. Retrievable filters. The OptEase vena cava filter (Cordis Endovascular, a Johnson & Johnson company, Miami, FL) (A). The Bard Recovery filter (C. R. Bard, Inc., Tempe, AZ) (B). The Günther Tulip filter (Cook Incorporated, Bloomington, IN) (C).

INDICATIONS FOR PLACEMENT OF IVC FILTERS IN BARIATRIC SURGERY PATIENTS

Routine use of some form of prophylaxis for DVT after surgery for morbid obesity is used by nearly all surgeons.⁴ However, there is little consensus in the method used for prophylaxis. Despite aggressive use of perioperative intermittent compression stockings, early ambulation, and anticoagulation, there is still a significant incidence of PE (approximately 1% overall and up to 4% in high-risk patients).^{4,5} After a review of their vast experience with obesity surgery, Sapala et al were able to identify four comorbid factors associated with the development of PE.⁶ These factors include severe venous stasis disease, a body mass index (BMI) of greater than 60, truncal obesity, and obesity hypoventilation syndrome/sleep apnea. In addition, other risk factors include a documented history of DVT/PE, a hypercoagulable state (Table 1), strong family history of DVT, use of oral contraceptives, age >60 years, and expected prolonged immobilization. IVC filter placement also may be considered in patients who receive postoperative epidural analgesia for pain control because optimal DVT prophylactic anticoagulation increases the risk of epidural hematoma (Table 2). Similar alterations in the systemic coagulation and fibrinolysis cascades are seen in both laparoscopic surgery and open bariatric surgery, although the rate of PE may be lower with laparoscopic procedures.⁷ Prophylaxis should be considered in high-risk patients undergoing both open and laparoscopic procedures.

FLUOROSCOPIC TECHNIQUE

Although morbidly obese patients present several technical challenges to IVC filter placement, these are

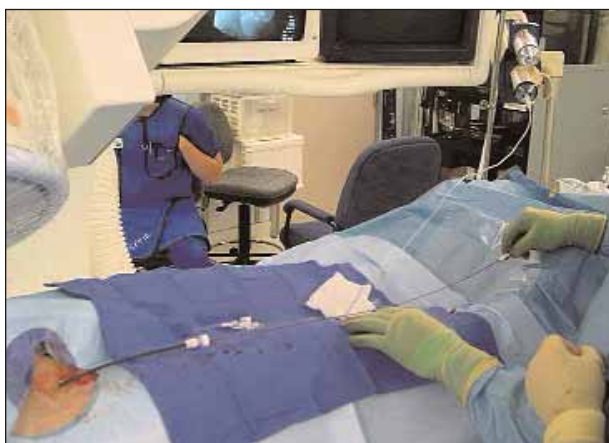

Figure 2. Retrieval of an OptEase filter used for prophylaxis. An 8-F sheath is inserted via a femoral approach as described. A cavagram is then obtained.

TABLE 1. CAUSES OF HYPERCOAGULABLE STATE LEADING TO HIGH RISK OF VENOUS THROMBOEMBOLISM

- Activated protein C resistance, such as Factor V Leiden mutation
- Prothrombin gene mutation, such as 20210A mutation
- Antithrombin III deficiency
- Protein C deficiency
- Protein S deficiency
- Lupus anticoagulant and antiphospholipid antibodies
- Hyperhomocysteinemia
- Dysfibrinogenemias
- Oral contraceptive usage

not prohibitive with proper planning. In the past, the morbidly obese patient often exceeded the weight limit of standard angiographic tables. However, most centers performing bariatric surgery now have fluoroscopic operating room tables capable of holding in excess of 750 pounds. In addition, fluoroscopic imaging is now much improved, such that effective venography and accurate filter placement can be obtained in nearly all patients.

Venous access is often the most difficult part of the filter placement procedure. Although newer filters can be placed via the brachial venous approach, the right internal jugular vein is the most commonly used access. The neck is often less laden with adipose tissue than the groin, especially in patients with a redundant panniculus. Additionally, the jugular approach allows for easy placement of a central venous catheter over the wire used for filter placement. This approach also obviates the need for a femoral/iliac venogram to rule out pre-existent DVT, but requires traversal of the heart, which can sometimes be difficult.

Placement of a rolled towel vertically between the shoulder blades allows posterior distraction of the shoulders. Pendulous breasts should be taped inferiorly to prevent obscuring the neck anatomy. The head is extended and rotated to the left. A small-gauge (22-gauge) seeker needle is used to localize the jugular vein, followed by cannulation with an 18-gauge needle. Alternatively, a micropuncture needle set (Inter-V Medical, Inc., Gainesville, FL) can be used for access. B-mode and duplex ultrasonography is rarely necessary but helpful in selected situations. A .035-inch guidewire is passed into the IVC, and an appropriately sized sheath for the filter carrier system is inserted. Occasionally, a directional catheter is required to pass the wire through the heart into the IVC.

Some filters require a femoral approach (ie, the OptEase vena cava filter). For a femoral approach, the pannus is elevated and taped out of the way. Once access is gained, an iliofemoral venogram must be obtained to exclude iliofemoral or caval thrombus, which would require another approach. Once wire access to the IVC is achieved, a pigtail catheter with marking bands is positioned at the L2-L3 interspace. An auto injection of 30 mL to 50 mL of nonionic contrast material through this catheter ensures the absence of thrombus in the cava, allows measurement of the cava, and often permits localization of the renal veins. A Valsalva maneuver at the time of the injection aids in visualizing the renal veins. The filter is typically placed with its tip at or just below the level of the renal veins. A central line can be placed through the jugular vein over the wire prior to its removal, if desired.

ALTERNATIVE TECHNIQUES

Contrast venography cannot be used in all patients for placement of IVC filters. Patients with contrast allergy or with renal insufficiency cannot receive radioiodinated contrast. Carbon dioxide or gadolinium cavography can be substitutes at some institutions. It is usually possible to obtain suitable imaging, even in these morbidly obese patients. Modern imaging systems with digital subtraction and road mapping capabilities have greatly improved fluoroscopic imaging capabilities (eg, OEC 9800 mobile C-arm, GE Healthcare Technologies, Salt Lake City, UT). However, when contrast venography

TABLE 2. INDICATIONS FOR PLACEMENT OF IVC FILTERS IN PATIENTS UNDERGOING BARIATRIC SURGERY

- Previous history of DVT/PE
- BMI greater than 55-60
- Hypercoagulable state
- Chronic venous insufficiency
- Obesity hypoventilation syndrome/sleep apnea
- Truncal obesity (android build)
- Contraindication to adequate prophylactic anticoagulation
- Expected prolonged immobilization

cannot be used for filter placement, other methods are available. The accurate deployment of IVC filters using IVUS has been well demonstrated in trauma patients, and this technique is well suited to placement in the bariatric surgery patient as well.⁸

A right femoral approach is used as previously described. A .035-inch guidewire is passed into the right atrium, and a 9-F sheath is inserted over the wire. Prior to insertion of the IVUS catheter, the catheter is aligned with the filter deployment sheath and the distance from the tip of the filter deployment sheath to the proximal hub marked on the IVUS catheter. The 12.5-MHz IVUS catheter (Boston Scientific Corporation,

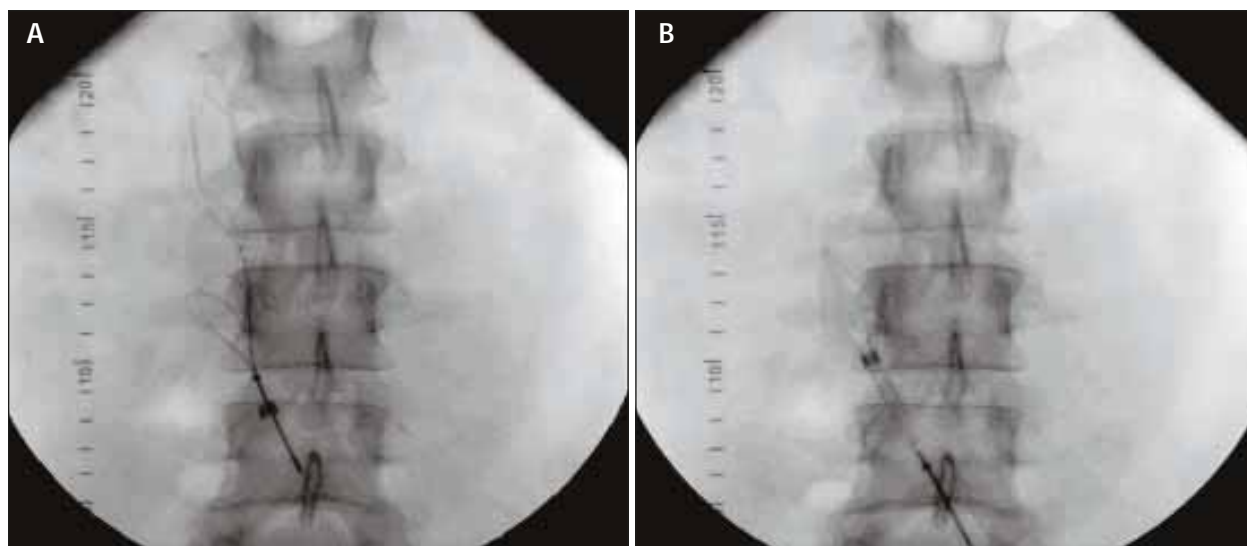


Figure 3. OptEase filter retrieval (A). Note filter hook engaged by snare. Ensnared OptEase filter recaptured into a 12-F sheath by advancing the sheath over the snare and filter (B). (Reprinted with permission from Rosenthal D, Wellons ED, Levitt AB, et al. Role of prophylactic temporary IVC filters placed at the ICU bedside under intravascular ultrasound guidance in patients with multiple trauma. *J Vasc Surg.* 2004;40:958-964).

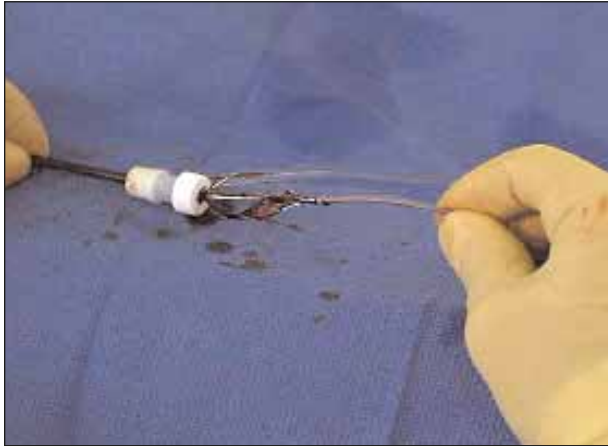


Figure 4. An OptEase filter ensnared with an Amplatz Gooseneck snare (Microvena, White Bear Lake, MN) being removed from the sheath.

Natick, MA) is used to measure the transverse and anterior/posterior diameters of the vena cava, identify thrombus within the femoral or iliac veins and the vena cava, locate the level of the renal veins, and detect any venous anomalies. Once the level of the renal veins is determined, the location of the mark on the IVUS catheter is transposed to the patient's thigh for filter deployment at the appropriate level. The filter deployment sheath is positioned so that the proximal hub is aligned with the mark on the patient's thigh, and the filter is deployed. Filter location can be confirmed with postprocedure abdominal radiography. Using this technique, accurate placement can be achieved in nearly all patients.⁹ Transcutaneous ultrasonography also has been utilized successfully to allow IVC filter placement, even in morbidly obese patients.¹⁰

COMPLICATIONS OF IVC FILTERS

Complications of IVC filters can occur during three timeframes: at insertion, with long-term implantation, or upon removal of retrievable filters. The rate of these adverse events varies with the designs of the different filters. In general, however, implantation complications of filter malpositioning or tilting, incomplete opening, migration, bleeding, air embolism, and pneumothorax are rare. Venous access site thrombosis ranges greatly among the different devices (2%-35%), with less thrombosis seen with the lower-profile systems.^{11,12} IVC thrombosis rates are also variable (0%-28%), depending on the device.¹¹ Venous insufficiency as a consequence of the DVT or IVC thrombosis occurs in more than half of patients when studied over time.¹³ PE rates are quite low with all filters currently in use (2%-5%).¹⁴ IVC penetration by the filter is typically seen as a delayed sequela

and can lead to bowel injury or aortocaval fistula. Other less common late adverse events include filter fracture, guidewire entrapment during placement of a central line, and filter migration. Retrieval failure, IVC perforation or injury, filter embolization, and pulmonary embolization of clot in the filter are all complications of attempted filter removal. These risks of filter removal must be weighed against the natural history of long-term filter implantation before embarking on retrieval.

RETRIEVABLE FILTERS

Retrievable filters were developed to meet the immediate benefit of IVC filters in preventing pulmonary embolization without the late complications of caval thrombosis and venous insufficiency. There are currently three FDA-approved filters with retrievable indications on the market in the US: OptEase, Recovery, and Günther Tulip (Figure 1). Patients undergoing bariatric surgery are ideal candidates for consideration of removable filters. Despite perioperative anticoagulation, they are at high risk of DVT and PE, but this potential risk is reduced quickly after surgery in those patients without complication. Gargiulo was able to show a reduction in the rate of PE with filter placement in patients with a BMI of greater than 55 who underwent open gastric bypass operations.¹⁵ However, their 14% late complication rate associated with indwelling filters may be remedied with filter removal.

In our experience, bariatric surgery patients with a BMI of greater than 55, a history of DVT, or a known hypercoagulable state are considered for IVC filter placement. During a preoperative discussion with a vascular surgeon, patients are explained the risks and benefits of both filter placement and removal. In those patients who desire potential filter removal, preopera-

(Continued on page 63)

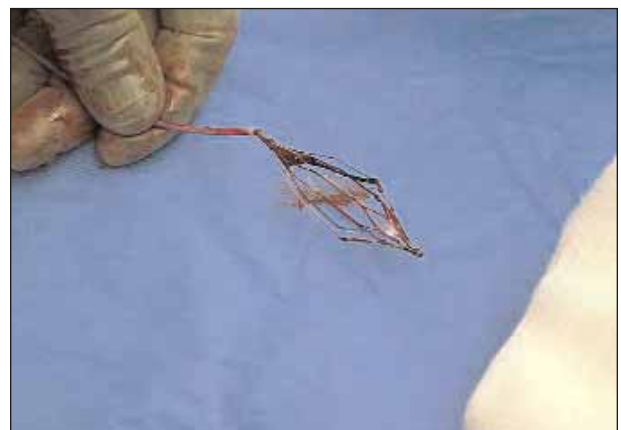


Figure 5. An ensnared, removed OptEase filter explanted after 2 weeks.